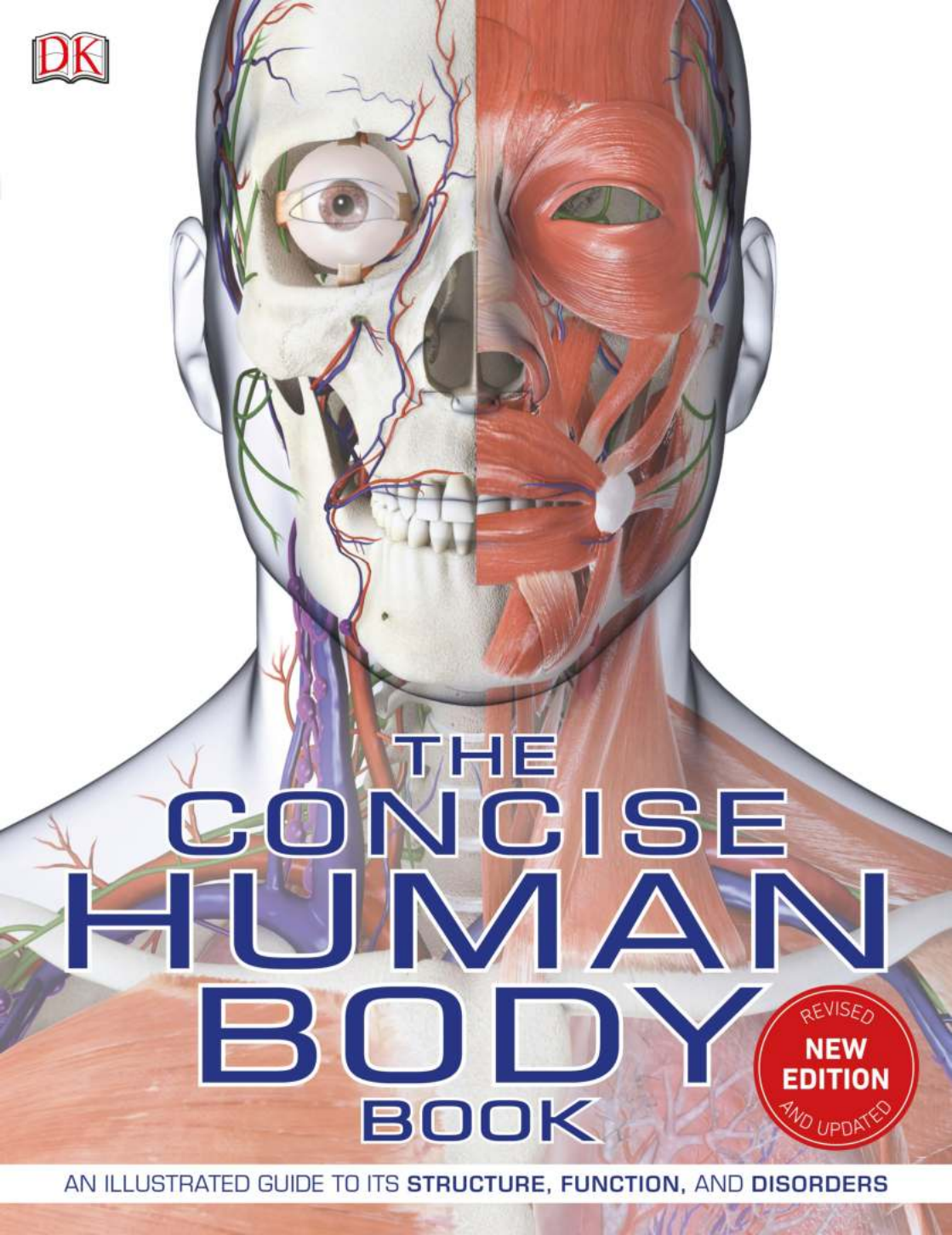

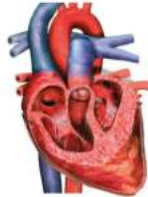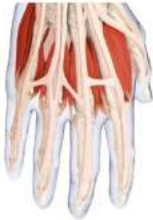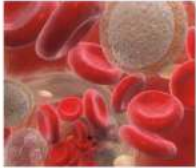
THE  
**CONCISE  
HUMAN  
BODY**  
BOOK

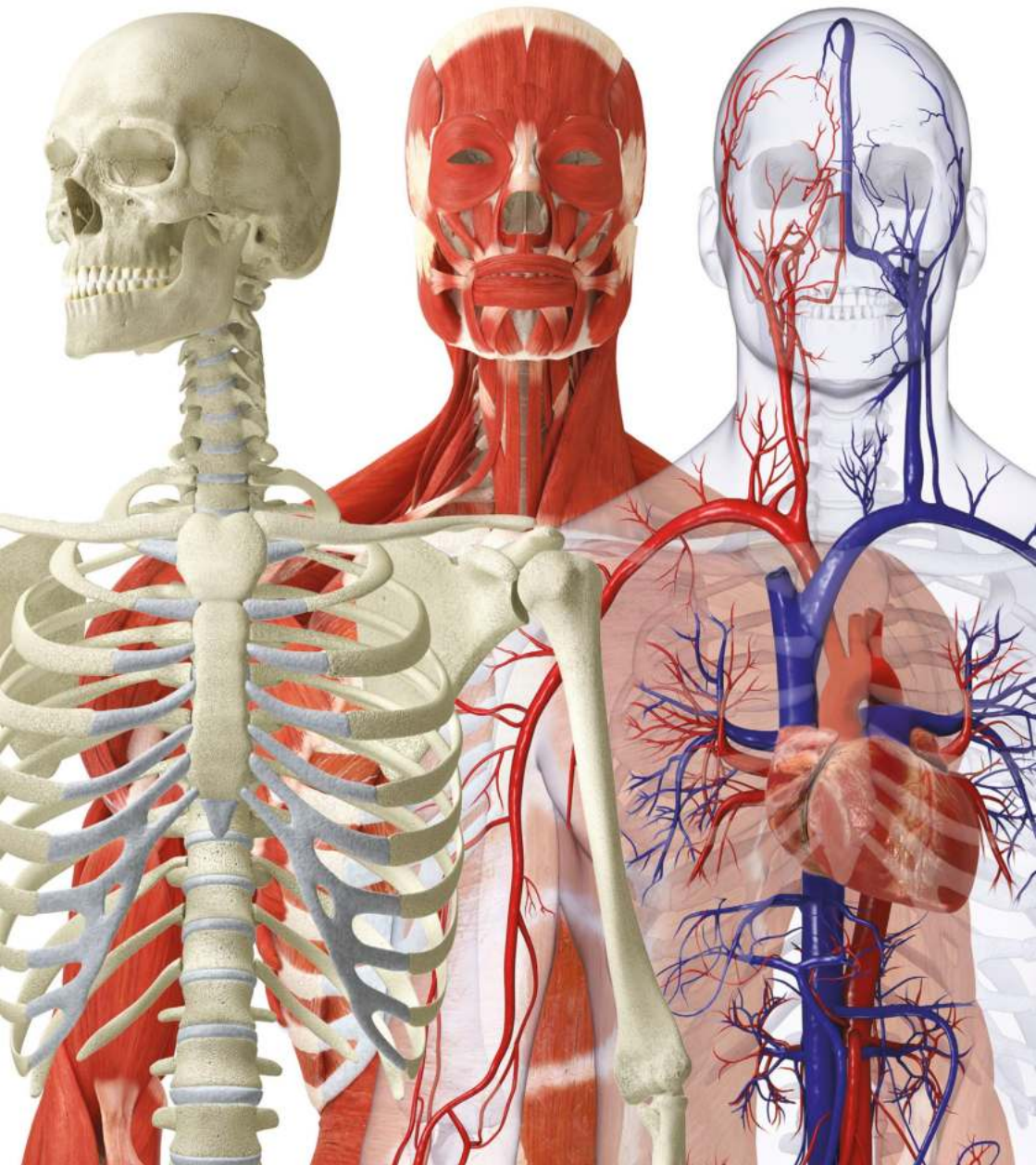
REVISED  
**NEW  
EDITION**  
AND UPDATED

AN ILLUSTRATED GUIDE TO ITS **STRUCTURE, FUNCTION, AND DISORDERS**



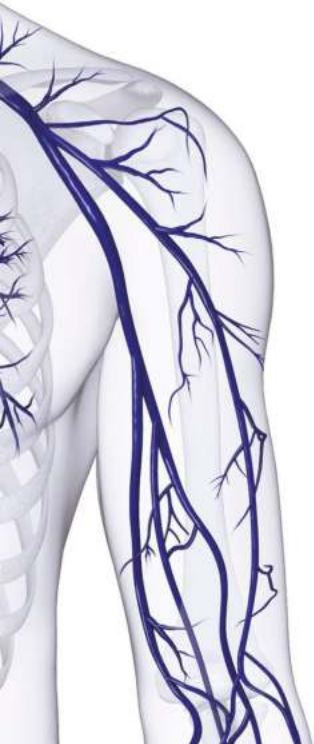THE  
CONCISE  
HUMAN  
BODY  
BOOK







THE  
CONCISE  
HUMAN  
BODY  
BOOK



**STEVE PARKER**



Penguin  
Random  
House

**PROJECT EDITORS** Ann Baggaley, Abhijit Dutta,  
Philip Morgan, Martyn Page, Mark Silas, Kate Taylor

**PROJECT ART EDITORS** Mandy Earey,  
Rupanki Arora Kaushik, Ted Kinsey

**SENIOR EDITOR** Simon Tuite

**SENIOR ART EDITOR** Vicky Short

**MANAGING EDITOR** Angeles Gavira, Julie Oughton

**MANAGING ART EDITOR** Louise Dick, Michael Duffy

**ASSOCIATE PUBLISHER** Liz Wheeler

**PUBLISHER** Jonathan Metcalf

**ART DIRECTOR** Karen Self, Bryn Walls

**JACKET DESIGNER** Duncan Turner

**PRODUCTION EDITORS** Joanna Byrne, Maria Elia

**PRE-PRODUCTION MANAGER** Balwant Singh

**PRODUCTION CONTROLLER** Sophie Argyris

**DTP DESIGNER** Bimlesh Tiwari

**INDEXER** Hilary Bird

**PROOFREADER** Katie John

**MEDICAL CONSULTANT** Dr Penny Preston,  
Dr Kristina Routh

*The Concise Human Body Book* provides information on a wide range of medical topics, and every effort has been made to ensure that the information in this book is accurate. The book is not a substitute for medical advice, however, and you are advised always to consult a doctor or other health professional on personal health matters

*The Concise Human Body Book* has been adapted from *The Human Body Book*, first published in Great Britain in 2007 by Dorling Kindersley Limited

This edition published in 2019  
First published in Great Britain in 2009 by  
Dorling Kindersley Limited,  
80 Strand, London, WC2R 0RL

Copyright © 2009, 2019  
Dorling Kindersley Limited  
A Penguin Random House Company  
10 9 8 7 6 5 4 3 2 1  
001 – 315374 – Jun/19

All rights reserved.

No part of this publication may be reproduced, stored in or introduced into a retrieval system, or transmitted, in any form, or by any means (electronic, mechanical, photocopying, recording, or otherwise), without the prior written permission of the copyright owner.

A CIP catalogue record for this book is  
available from the British Library

ISBN 978-0-2413-9552-3

For *The Human Body Book*:

**PROJECT EDITOR** Rob Houston

**PROJECT ART EDITOR** Maxine Lea

**EDITORS** Ruth O'Rourke, Rebecca Warren,  
Mary Allen, Kim Bryan, Tarda Davidson-Aitkins,  
Jane de Burgh, Salima Hirani, Miezian van Zyl

**DESIGNERS** Matt Schofield, Kenny Grant,  
Francis Wong, Anna Plucinska

**MANAGING EDITOR** Sarah Larter

**MANAGING ART EDITOR** Philip Ormerod

**PUBLISHING MANAGER** Liz Wheeler

**REFERENCE PUBLISHER** Jonathan Metcalf

**ART DIRECTOR** Bryn Walls

**PICTURE RESEARCHER** Louise Thomas

**JACKET DESIGNER** Lee Ellwood

**DTP DESIGNER** Laragh Kedwell

**PRODUCTION CONTROLLER** Tony Phipps

**EDITORIAL ASSISTANTS** Tamlyn Calitz,  
Manisha Thakkar

**INDEXER** Hilary Bird

**PROOFREADER** Andrea Bagg

**CONTRIBUTORS** Mary Allen, Andrea Bagg,  
Jill Hamilton, Katie John, Janet Fricker,

Jane de Burgh, Claire Cross

**MEDICAL CONSULTANTS** Dr Sue Davidson,  
Dr Penny Preston, Dr Ian Guinan

**ILLUSTRATORS**

**CREATIVE DIRECTOR** Rajeev Doshi

**3D ARTISTS** Olaf Louwinger, Gavin Whelan,  
Monica Taddei



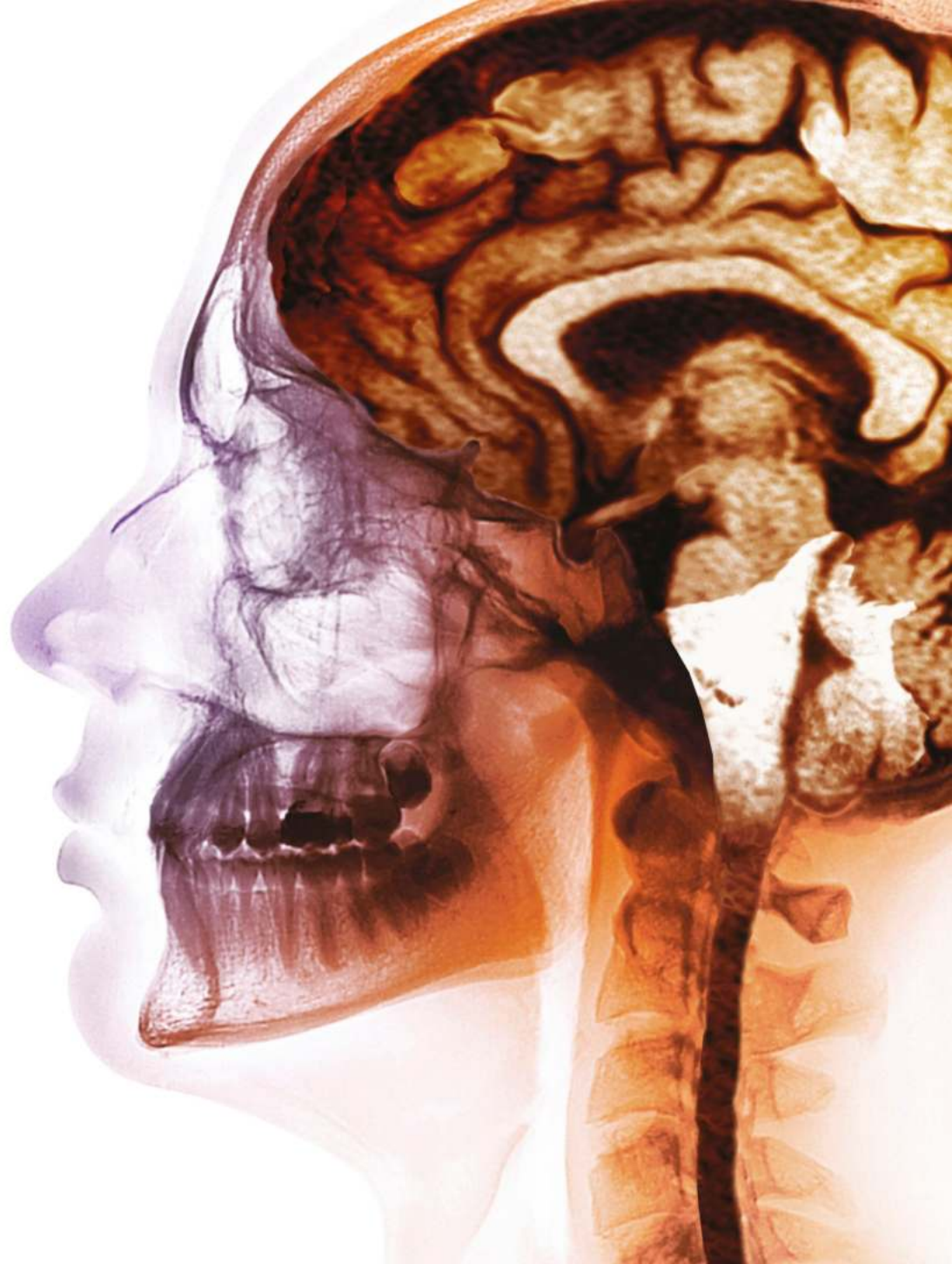**ADDITIONAL ILLUSTRATORS** Peter Bull Art Studio,  
Kevin Jones Associates, Adam Howard

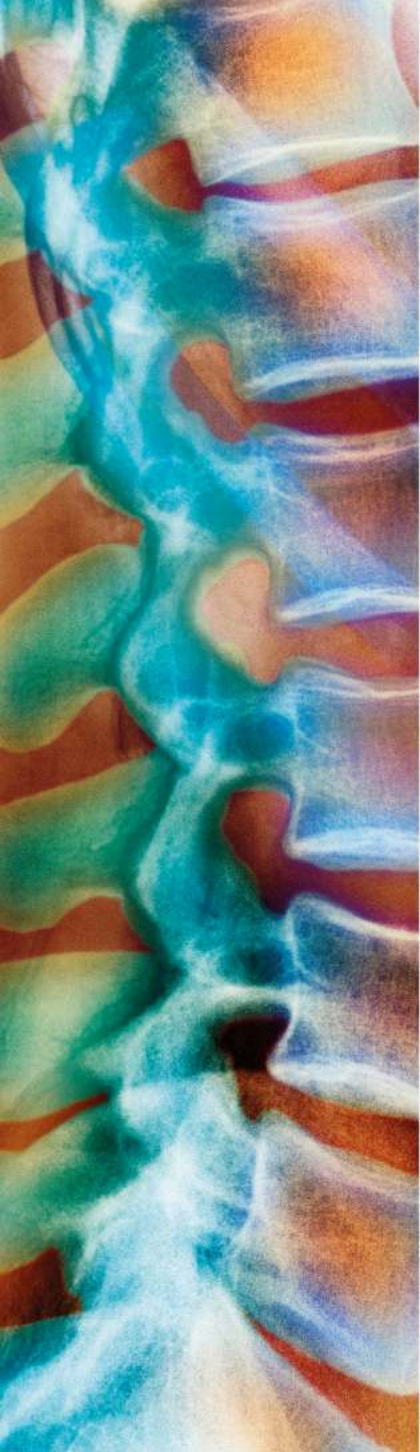
Colour reproduction by  
GRB Editrice s.r.l. in London, UK

Printed and bound in China

A WORLD OF IDEAS:  
**SEE ALL THERE IS TO KNOW**

[www.dk.com](http://www.dk.com)





# CONTENTS

<b>INTEGRATED BODY</b>	<b>8</b>
INTRODUCTION	10
IMAGING THE BODY	12
BODY SYSTEMS	14
SUPPORT AND MOVEMENT	18
INFORMATION PROCESSING	20
THE FLUID BODY	21
EQUILIBRIUM	22
BODY SYSTEMS TO CELLS	24
THE CELL	26
DNA	30
THE GENOME	34
SPECIALIZED CELLS AND TISSUES	36
<b>SKELETAL SYSTEM</b>	<b>38</b>
SKELETON	40
BONE STRUCTURE	42
JOINTS	44
SKULL	48
SPINE	50
RIBS AND PELVIS	52
HANDS AND FEET	54
BONE AND JOINT DISORDERS	56
<b>MUSCULAR SYSTEM</b>	<b>62</b>
MUSCLES OF THE BODY	64
MUSCLES OF THE FACE, HEAD, AND NECK	68
MUSCLES AND TENDONS	70
MUSCLE AND TENDON DISORDERS	74
<b>NERVOUS SYSTEM</b>	<b>76</b>
NERVOUS SYSTEM	78
NERVES AND NEURONS	80
NERVE IMPULSE	84
BRAIN	86
BRAIN STRUCTURES	90
THE PRIMITIVE BRAIN	94
SPINAL CORD	98
PERIPHERAL NERVES	102
AUTONOMIC NERVOUS SYSTEM	106
MEMORIES, THOUGHTS, AND EMOTIONS	110
SMELL, TASTE, AND TOUCH	112
EARS, HEARING, AND BALANCE	116
EYES AND VISION	120
NERVOUS SYSTEM DISORDERS	124



## ENDOCRINE SYSTEM

ENDOCRINE ANATOMY  
HORMONE PRODUCERS  
HORMONAL ACTION  
ENDOCRINE DISORDERS

## CARDIOVASCULAR SYSTEM

CARDIOVASCULAR ANATOMY  
BLOOD AND BLOOD VESSELS  
HEART STRUCTURE  
HOW THE HEART BEATS  
CARDIOVASCULAR DISORDERS

## RESPIRATORY SYSTEM

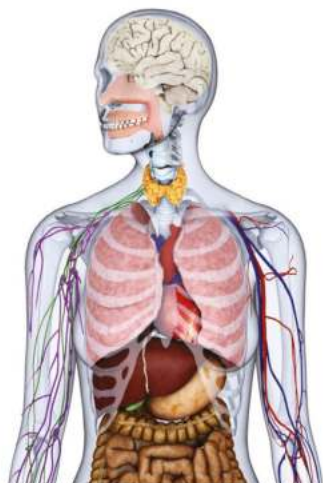
RESPIRATORY ANATOMY  
LUNGS  
GAS EXCHANGE  
BREATHING AND VOCALIZATION  
RESPIRATORY DISORDERS

## SKIN, HAIR, AND NAILS

SKIN, HAIR, AND NAIL STRUCTURE  
SKIN AND EPITHELIAL TISSUES  
SKIN DISORDERS

## LYMPH AND IMMUNITY

LYMPH AND IMMUNE SYSTEMS  
IMMUNE SYSTEM



<b>130</b>	INFLAMMATORY RESPONSE	198
132	FIGHTING INFECTIONS	202
134	IMMUNE SYSTEM DISORDERS	208

## **140** DIGESTIVE SYSTEM **210**

	DIGESTIVE ANATOMY	212
<b>144</b>	144 MOUTH AND THROAT	214
146	STOMACH AND SMALL INTESTINE	218
148	LIVER, GALLBLADDER, AND PANCREAS	220
150	LARGE INTESTINE	224
154	DIGESTION	228
156	NUTRIENTS AND METABOLISM	232
	DIGESTIVE TRACT DISORDERS	234

## **160** URINARY SYSTEM **240**


162	URINARY ANATOMY	242
164	KIDNEY STRUCTURE	244
166	URINARY DISORDERS	248

## **160** REPRODUCTION AND LIFE CYCLE **250**

<b>176</b>	MALE REPRODUCTIVE SYSTEM	252
178	FEMALE REPRODUCTIVE SYSTEM	256
182	CONCEPTION TO EMBRYO	260
188	FETAL DEVELOPMENT	264
	PREPARING FOR BIRTH	266
	LABOUR	268
192	DELIVERY	270
194	AFTER THE BIRTH	272
	GROWTH AND DEVELOPMENT	276
	PUBERTY	280
	AGEING	284
	INHERITANCE	286
	PATTERNS OF INHERITANCE	290
	MALE REPRODUCTIVE DISORDERS	294
	FEMALE REPRODUCTIVE DISORDERS	296
	SEXUALLY TRANSMITTED INFECTIONS	298
	INFERTILITY DISORDERS	300
	PREGNANCY AND LABOUR DISORDERS	302
	INHERITED DISORDERS	304
	CANCER	305

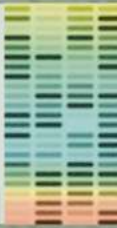
## **GLOSSARY AND INDEX** **306**

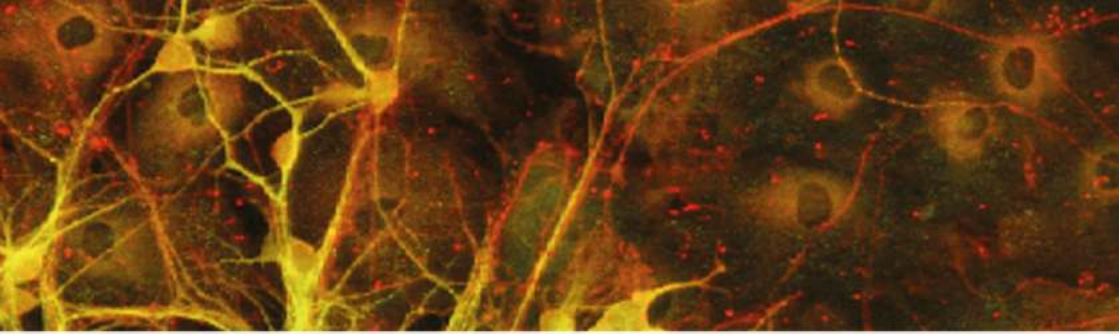
	GLOSSARY	306
	INDEX	312
	ACKNOWLEDGMENTS	320



THE HUMAN BODY IS THE MOST DEEPLY STUDIED AND FREQUENTLY PORTRAYED OBJECT IN HISTORY. DESPITE ITS FAMILIARITY, IT IS ETERNALLY ABSORBING AND FASCINATING. THE PAGES OF THIS BOOK REVEAL, IN AMAZING VISUAL DETAIL, AND IN BOTH HEALTH AND SICKNESS, THE INTRICATE INNERMOST WORKINGS OF THE BODY'S CELLS, TISSUES, ORGANS, AND SYSTEMS. MUCH OF THE FASCINATION LIES IN THE WAY THESE PARTS INTERACT AND INTEGRATE AS EACH RELIES ON THE OTHERS TO FUNCTION AND SURVIVE.

# INTEGRATED BODY





## INTRODUCTION

The number of humans in the world has raced past seven billion (7,000,000,000). More than 250 babies are born every minute, while 150,000 people die daily, with the population increasing by almost three humans per second. Each of these people lives and thinks with, and within, that most complex and marvellous of possessions – a human body.

### LEVELS OF ORGANIZATION

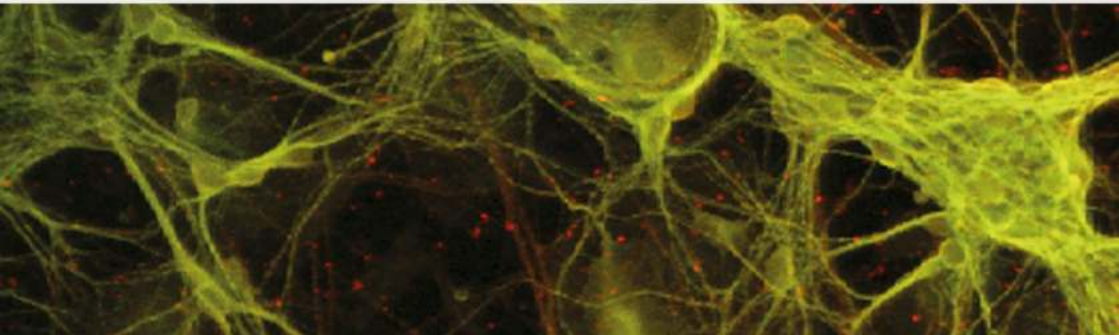
To understand the inner structure and workings of the human body, this book takes the “living machine” approach, borrowed from sciences such as engineering. This views the body as a series of integrated systems. Each system carries out one major task. In the cardiovascular system, for example, the heart pumps blood through vessels, to supply every body part with essential oxygen and nutrients. The systems are, in turn, composed of main parts known

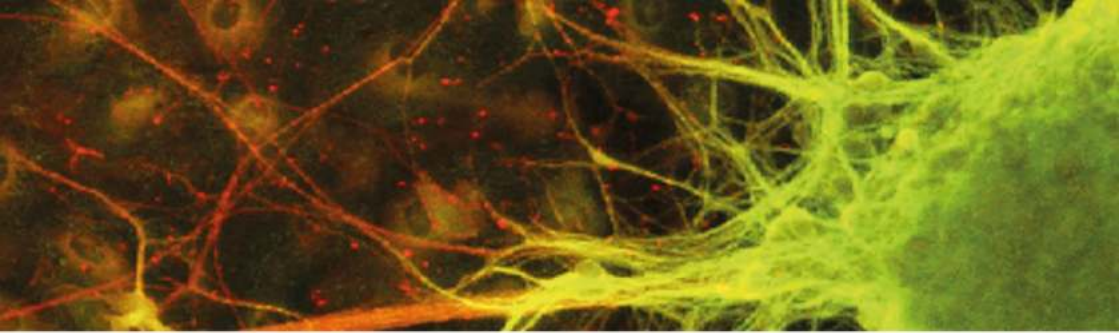
as organs. For example, the stomach, intestines, and liver are organs of the digestive system. Moving down through the anatomical hierarchy, organs consist of tissues, and tissues are made up of cells.

Cells are often called the building blocks of the body. Active and dynamic, they continually grow and specialize, function, die, and replenish themselves, by the millions every second. The whole body contains about 100 million million cells, of at least 200 different kinds. Science is increasingly able to delve deeper than cells, to the organelles within them, and onwards, to the ultimate components of ordinary matter – molecules and atoms.

### ANATOMY

The study of the body’s structure, and how its cells, tissues, and organs are assembled, is known as human anatomy. For clarity, its elements are often shown in isolation, because the inside of the body is





a crowded place. Tissues and organs press against one another. Body parts shift continually as we move, breathe, pump blood, and digest food. For example, swallowed food does not simply fall down the gullet into the stomach; it is forced down by waves of muscular contraction.

## PHYSIOLOGY

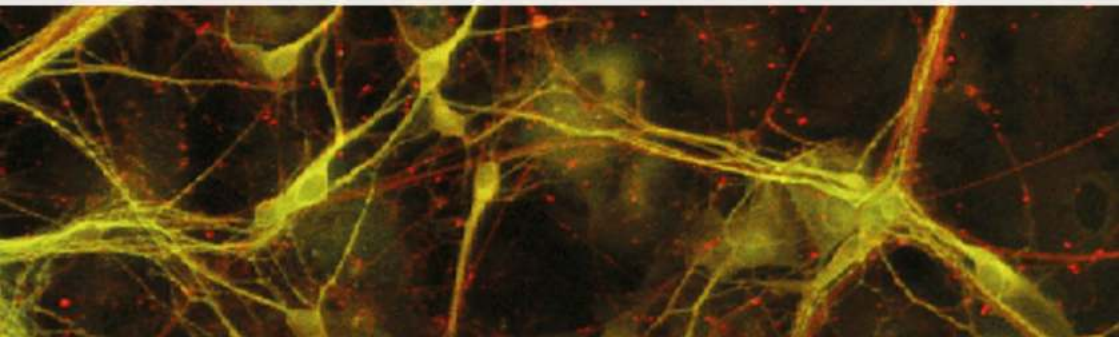
For a rounded understanding of the body, we need to see human anatomy in combination with physiology – the study of how the body functions. Physiology focuses on the dynamic chemical minutiae at atomic, ionic, and molecular levels. It investigates the workings of such processes as enzyme action, hormone stimulation, DNA synthesis, and how the body stores and uses energy from food. As researchers look closer, and unravel more biochemical pathways, more physiological secrets are unlocked. Much of this research work is aimed at preventing or treating disease.

## HEALTH AND ILLNESS

Medical science amasses mountains of evidence every year for the best ways to stay healthy. At present, an individual's genetic inheritance, which is a matter of chance, is the given starting point for maintaining health and well-being. In recent years, treatments such as pre-implantation genetic diagnosis (PIGN) – carried out as part of assisted reproductive techniques, such as in vitro fertilization (IVF) – and gene therapy are able to remove or negate some of these chance elements. Many aspects of upbringing have a major impact on health, including factors such as diet and whether it is too rich or too poor. The body can also be affected by many different types of disorders, such as infection by a virus or bacteria, injury, inherited faulty genes, or exposure to toxins in the environment.

## COMMUNICATION NETWORK

This microscopic image of nerve cells (neurons) shows the fibres that connect the cell bodies. Neurons transmit electrical signals around the body; each one links with hundreds of others, forming a dense web.



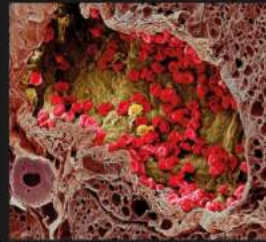
# IMAGING THE BODY

IMAGING IS A VITAL PART OF DIAGNOSING ILLNESS, UNDERSTANDING DISEASE, AND EVALUATING TREATMENTS. MODERN TECHNIQUES PROVIDING HIGHLY DETAILED INFORMATION HAVE LARGELY REPLACED SURGERY AS A METHOD OF INVESTIGATION.

The invention of the X-ray made the development of non-invasive medicine possible. Without the ability to see inside the body, many disorders could be found only after major surgery. Computerized imaging now helps doctors make early diagnoses, often greatly increasing the chances of recovery. Computers process and enhance raw data, for example re-interpreting shades of grey from an X-ray or scan into colours. However, sometimes direct observation is essential. Viewing techniques have also become less invasive with the development of instruments such as the endoscope (see opposite). This book makes extensive use of internal images from real bodies.

## MICROSCOPY

In light microscopy (LM), light is passed through a section of material and lenses magnify the view up to 2,000 times. Even higher magnifications are possible with scanning electron microscopy (SEM), in which light runs across a specimen coated with gold film. Electrons bounce off the surface, creating a three-dimensional image.

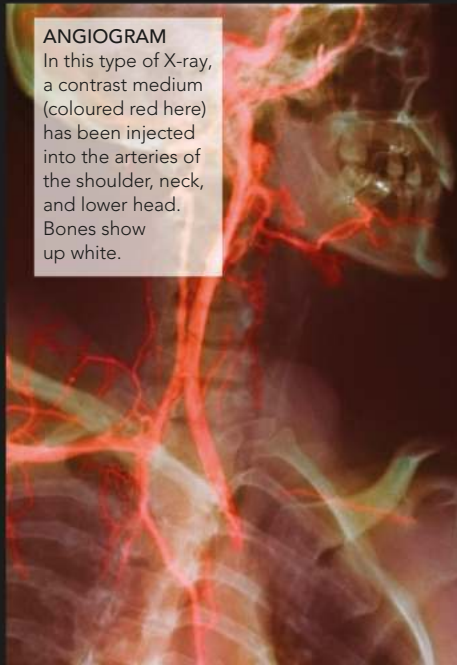


## SEM OF TUMOUR BLOOD SUPPLY

This image, in which the specimen has been frozen and split open, shows a blood vessel with blood cells growing into a melanoma (skin tumour).

## ANGIOGRAM

In this type of X-ray, a contrast medium (coloured red here) has been injected into the arteries of the shoulder, neck, and lower head. Bones show up white.

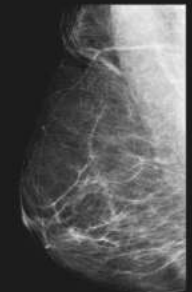


## X-RAY

X-rays are similar to light waves, but of very short wavelength. When passed through the body they create shadow images on photographic film. Dense structures such as bone show up white; soft tissues appear as shades of grey. To show up hollow or fluid-filled structures, these are filled with a substance that absorbs X-rays (a contrast medium). Fluoroscopy uses X-rays to gain real-time moving images of body parts, for instance to investigate swallowing.

## X-RAY OF THE BREAST

A plain X-ray of the female breast (mammogram) is used as a routine screening test for breast cancer, which may show up as an unusually white area. This mammogram shows a healthy breast.

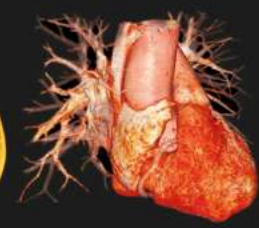
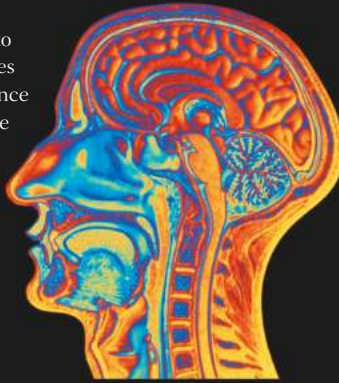


## MRI AND CT SCANNING

In computerized tomography (CT) an X-ray scanner is used with a computer to build up cross-sectional images of tissues of different density. In magnetic resonance imaging (MRI), magnets are used to line up atoms in the body, then radio waves throw the atoms out of alignment. As they realign, the atoms emit signals that are used to create an image.

### MRI SCAN OF HEAD

A coloured MRI scan of the mid-line of the head in side view; visible structures including the brain and spinal cord, the nasal cavity, and the tongue.



### CT SCAN OF THE HEART

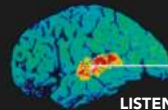
A 3-D CT scan of the heart from the right side; showing the large aorta (main artery, centre top) and some of the blood-vessels of the lungs.

## NUCLEAR MEDICINE IMAGING

In nuclear medicine imaging, a radioactive substance (radionuclide) is injected and absorbed by the area to be imaged. As the substance decays it emits gamma rays, which a computer forms into an image. This type of imaging can help to diagnose disorders such as cancers and heart diseases. Nuclear medicine imaging scans like positron emission tomography (PET) and single-photon emission computed tomography (SPECT) give data about the function of a tissue rather than detailed anatomy.

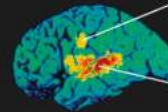
### PET SCAN

PET scans show function rather than anatomy. These images reveal the brain's activity as the subject listened to spoken words and then both listened to and repeated the words.



**Auditory cortex**  
Hearing region

**LISTENING**



**Motor control region**  
**Auditory cortex**  
Hearing region

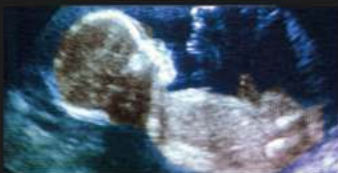**SPEAKING**

## ULTRASOUND

High-frequency sound waves emitted by a device called a transducer pass into the body and echo back as electrical signals. A computer processes the signals to create images.

### FETAL ULTRASOUND

Ultrasound is a very safe technique, commonly used to monitor fetal development in the uterus.

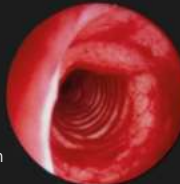


## ENDOSCOPY

Endoscopes are flexible or rigid tubes inserted into the body to view its interior, perform surgical procedures, or both. They carry a light source and instruments may be passed down them.

### TRACHEA

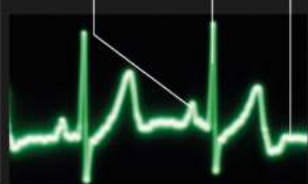An endoscopic view of the trachea (windpipe) shows the hoops of cartilage that maintain its shape.



## ELECTRICAL ACTIVITY

Sensor pads applied to the skin detect electrical activity in muscles and nerves. The signals are displayed as a trace line. This technique includes electrocardiography (ECG) of the heart (see below).

Upper chambers contract      Lower chambers contract      Heart muscle relaxes



# BODY SYSTEMS

THE HUMAN BODY'S SYSTEMS WORK TOGETHER AS A TRUE COOPERATIVE. EACH SYSTEM FULFILLS ITS OWN VITAL FUNCTION, BUT ALL WORK TOGETHER TO MAINTAIN THE HEALTH AND EFFICIENCY OF THE BODY AS A WHOLE.

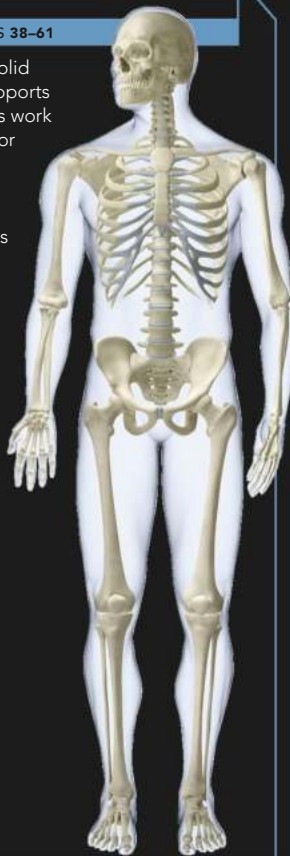The exact number and extent of the body's systems is debated – the muscles, bones, and joints are sometimes combined as the musculoskeletal system, for instance. Although these systems can be described as separate entities, each depends on all of the others for physical and physiological

support. Most systems have some “general” body tissues, such as the connective tissues, which delineate, support, and cushion many organs. All the systems – except, and somewhat ironically, the reproductive system – are essential for our basic survival.

## SKELETAL

EXPLORED ON PAGES 38–61

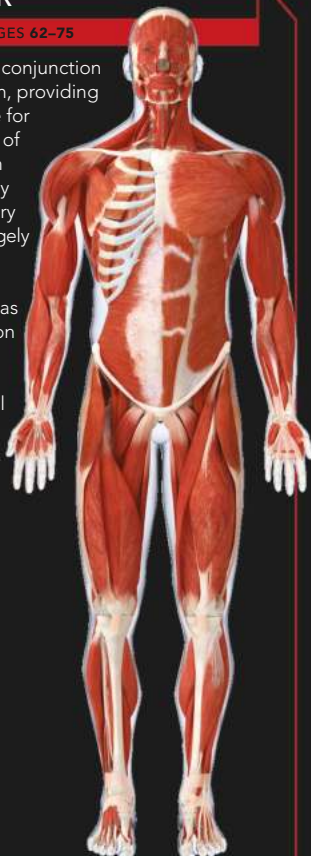The skeleton is a solid framework that supports the body. Its bones work as levers and anchor plates to allow for movement. Bones also have a role in other body systems – blood cells develop in their fatty inner tissue (red marrow), for example. The body draws from mineral stores in bones during times of shortage, such as when calcium is needed for healthy nerve function.



## MUSCULAR

EXPLORED ON PAGES 62–75

Muscles work in conjunction with the skeleton, providing the pulling force for varying degrees of movement, from powerful to finely tuned. Involuntary muscles work largely automatically to control internal processes, such as blood distribution and digestion. Muscles rely on nerves to control them and blood to keep them supplied with oxygen and energy.

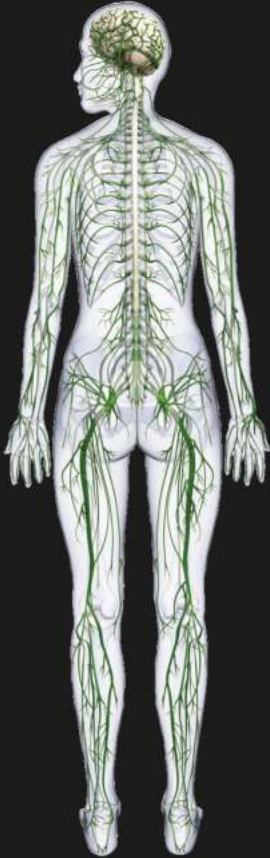




## NERVOUS

EXPLORED ON PAGES 76–129

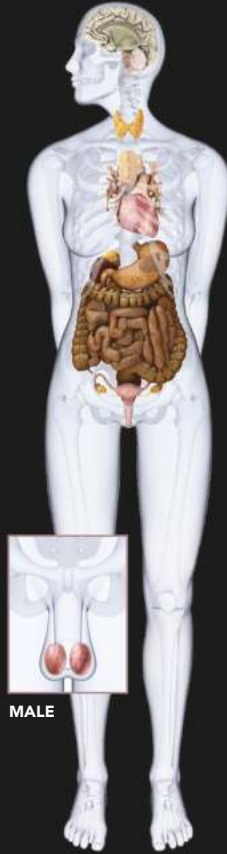The brain is the seat of both consciousness and creativity and, through the spinal cord and nerve branches, it controls all body movements with its motor output. The brain also receives sensory information from outside and within the body. Much of the brain's activity occurs unconsciously as it works with endocrine glands to monitor and maintain other body systems.



## ENDOCRINE

EXPLORED ON PAGES 130–143

The glands and cells of the endocrine system produce chemical messengers called hormones, which circulate in blood and other fluids. These maintain an optimal internal environment. Hormones also govern long-term processes such as growth, the changes that take place during puberty, and reproductive activity. The endocrine system has close links to the nervous system.

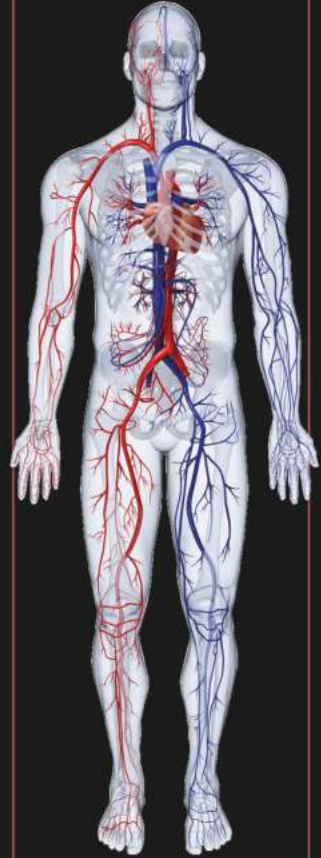


MALE

## CARDIOVASCULAR

EXPLORED ON PAGES 144–159

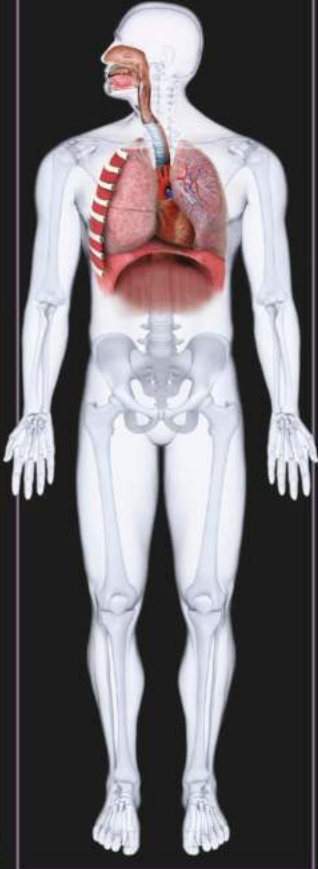
The most basic function of the cardiovascular, or circulatory, system is to pump blood around the body. It supplies all organs and tissues with freshly oxygenated, nutrient-rich blood. Any waste products of cell function are removed with the blood as it leaves. The circulatory system also transports other vital substances, such as nutrients, hormones, and immune cells.



## RESPIRATORY

EXPLORED ON PAGES 160–175

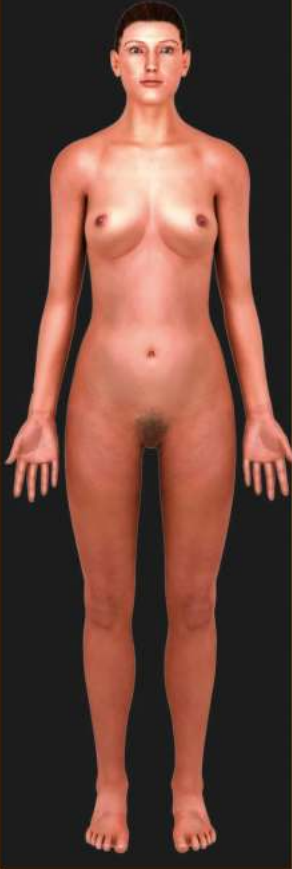The respiratory tract and its movements, powered by breathing muscles, carry air into and out of the lungs. Deep inside the lungs, gases are exchanged. On inhalation, life-giving oxygen is absorbed from air, while carbon dioxide waste is passed into the air, to be expelled from the body on exhalation. A secondary function of the respiratory system is vocalization.



## SKIN, HAIR, AND NAILS

EXPLORED ON PAGES 176–189

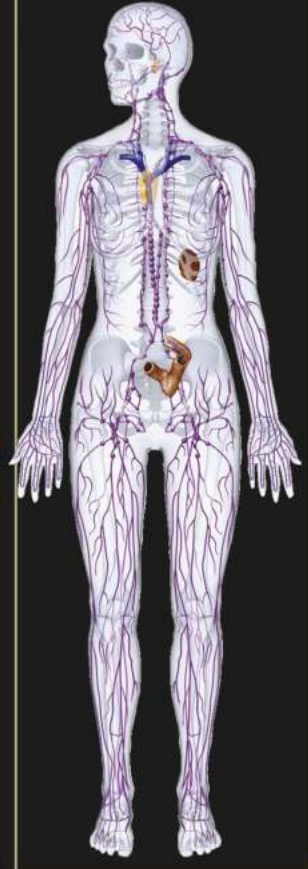
The skin, hair, and nails form the body's outer protective covering, and are together termed the integumentary system. They repel hazards such as physical injury, microorganisms, and radiation. The skin also regulates body temperature through sweating and hair adjustment. A layer of fat under the skin acts as an insulator, an energy store, and a shock absorber.



## LYMPH AND IMMUNITY

EXPLORED ON PAGES 190–209

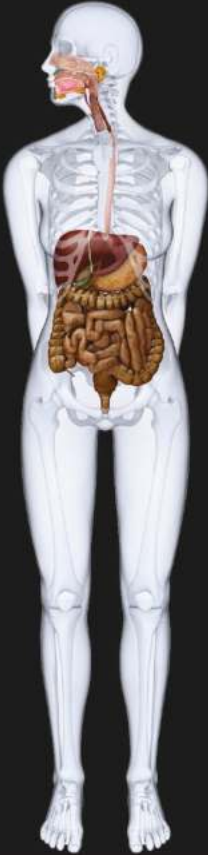The immune system's intricate interrelationships of physical, cellular, and chemical defences provide vital resistance to many threats, including infectious diseases and malfunctions of internal processes. The slowly circulating lymph fluid helps to distribute nutrients and collect waste. It also delivers immunity-providing white blood cells when needed.



## DIGESTIVE

EXPLORED ON PAGES 210–239

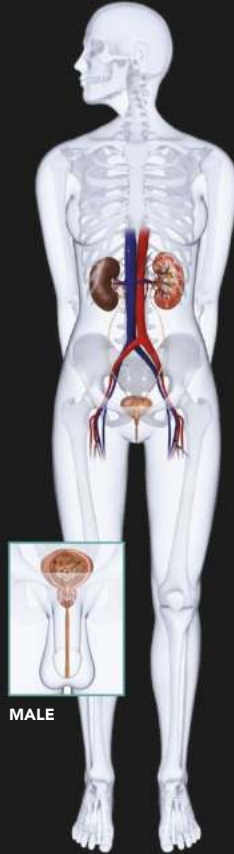The digestive tract's nine metres or so of tubing, which runs from the mouth to the anus, has a complex range of functions. It chops and chews food, stores and then digests it, eliminates waste, and passes the nutrients to the liver, which processes or stores the various digestive products. Healthy digestion depends on the proper functioning of the immune and nervous systems.



## URINARY

EXPLORED ON PAGES 240–249

The formation of urine by the kidneys eliminates unwanted substances from the blood, helping to maintain the body's correct balance of fluids, salts, and minerals. Urine production is controlled by hormones and influenced by blood flow and pressure, intake of water and nutrients, fluid loss (through sweating, for instance), external temperature, and bodily cycles such as sleeping and waking.

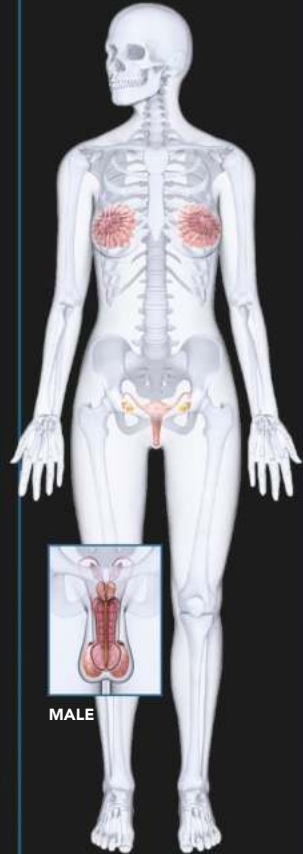


MALE

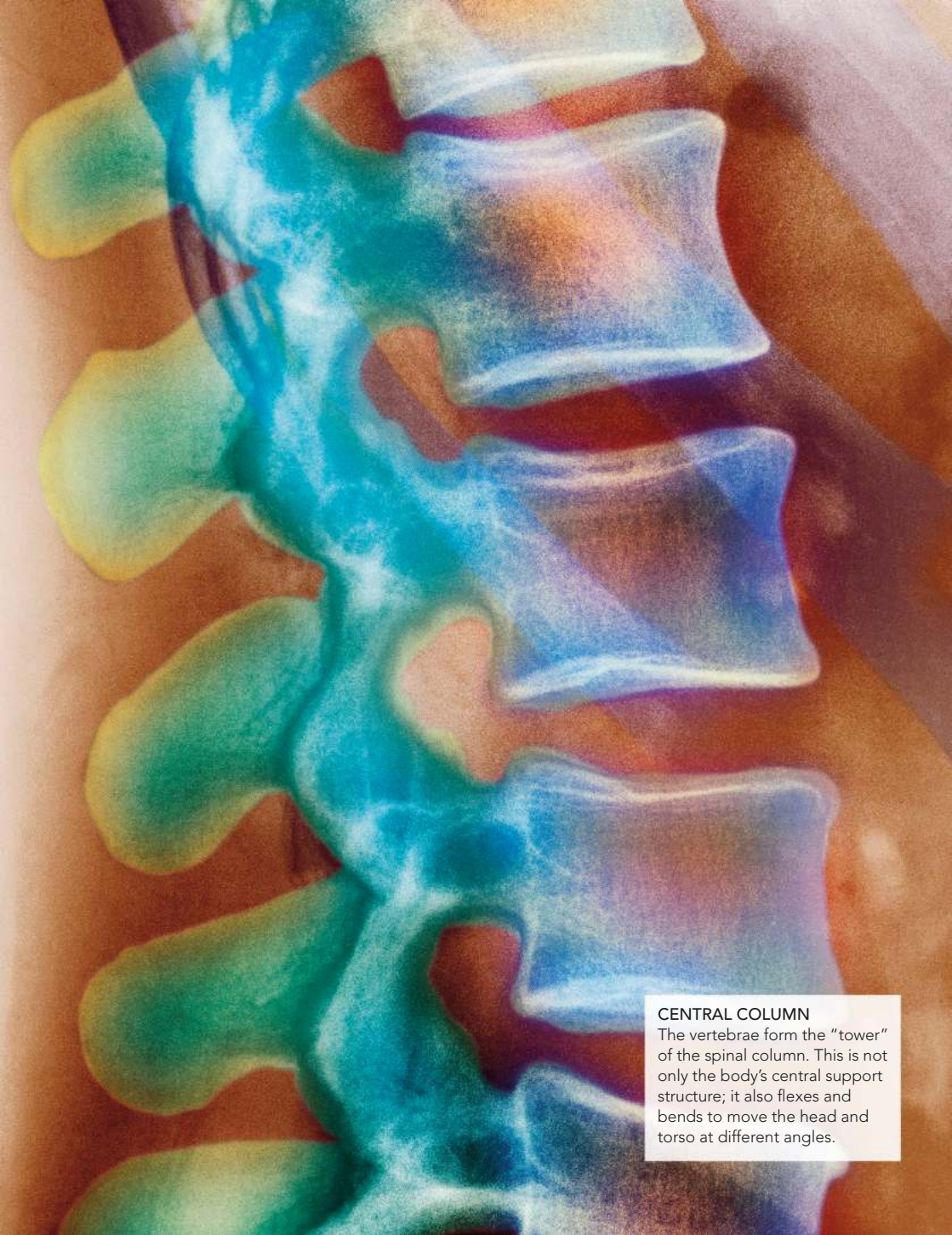## REPRODUCTIVE

EXPLORED ON PAGES 250–305

Unlike any other system, the reproductive system differs dramatically between female and male; it functions only for part of the human life span, and is not vital for maintaining life. The production of sperm in the male is continual while the female production of ripe eggs is cyclical. In the male, both sperm and urine use the urethra as an exit tube at different times.



MALE



#### **CENTRAL COLUMN**

The vertebrae form the "tower" of the spinal column. This is not only the body's central support structure; it also flexes and bends to move the head and torso at different angles.

# SUPPORT AND MOVEMENT

THE BODY'S MUSCLES, BONES, AND JOINTS PROVIDE A SUPPORTIVE FRAMEWORK CAPABLE OF AN ENORMOUS RANGE OF MOTION. MUSCLES AND BONES ALSO HAVE NUMEROUS INTERACTIONS WITH OTHER BODILY SYSTEMS, ESPECIALLY THE NERVES.

The body's muscular system is never still. Even as the body sleeps, breathing continues, the heart beats, the intestines squirm, and skeletal muscles contract occasionally to shift the body into a new position.

## MUSCLE TEAMWORK

Most movements are the result of multiple muscle contractions. A smile, for example, involves 20 facial muscles; writing utilizes more than 60 muscles in the arm, hand, and wrist. Muscles work in pairs: as one contracts to pull on a bone and initiate movement, an opposing muscle relaxes. Body action is a continuing sequence of split-second give-and-take.

## POSTURE AND FEEDBACK

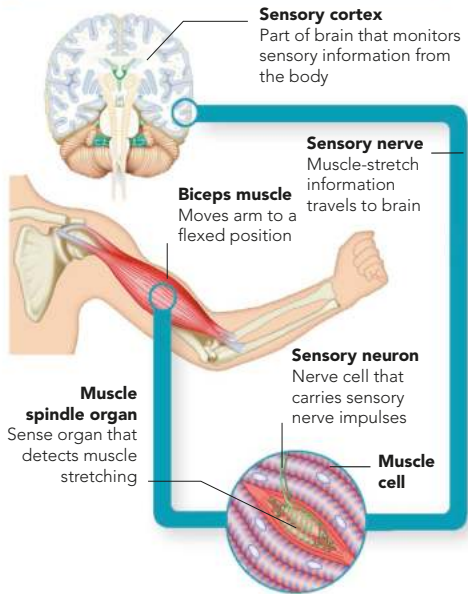
Sensory systems built into muscles provide the brain with information about the posture and position of the body and limbs. This is known as the proprioceptive sense, which allows us to "know", without having to look or feel, that fingers are clenched or a knee is bent. When we are learning a new motor skill, we concentrate on the movement as the brain adjusts muscle control through trial and error. With practice, the motor nerve patterns

### STAYING SUPPLE

Our potential for movement, and the health of the skeletal and muscular systems, is maximized by regular exercises for strength, stamina, and suppleness.



SPECIALIZED CELLS AND TISSUES	36-37
SKELETAL SYSTEM	38-61
MUSCULAR SYSTEM	62-75
SKIN, HAIR, AND NAILS	176-189



### SENSORY FEEDBACK

Within muscles, nerves end in sense organs (spindle organs). These respond to tension by firing signals along nerve fibres to tell the brain what is happening.

and their proprioceptive feedback become established, and eventually the movement becomes automatic. Sensory feedback also protects the muscular and skeletal systems against injury. If bones or muscles are under excessive stress, nerve messages registering discomfort or pain are sent to the brain. Awareness of the pain stimulates evasive or protective action by the body.

# INFORMATION PROCESSING

THE BODY IS A DYNAMIC MECHANISM WHOSE INTERACTING PARTS REQUIRE CONTROL AND COORDINATION. TWO BODY SYSTEMS ARE RESPONSIBLE FOR THESE INFORMATION-PROCESSING FUNCTIONS: THE NERVOUS AND ENDOCRINE SYSTEMS.

Information processing involves inputs, evaluation, and decision-making, followed by outputs. The body receives inputs from the senses. The brain is the central processing unit whose outputs control the physical actions of muscles and chemical responses of glands. Both nerves and hormones are involved in data management.

## ELECTRICAL AND CHEMICAL PATHWAYS

The “language” of the nervous system is tiny electrical impulses. Every second, millions pass through the body’s nerve network, conveying information to and from the brain. Information from the senses flows to the brain, where it is analysed. Decisions are reached, and command messages – also in the form of electrical impulses – travel along motor nerves to the muscles to stimulate and coordinate their contractions. In addition, microreceptors monitor conditions inside the body and feed data about it to the unconscious part of the brain, which automatically evaluates the data and sends out impulses to various parts of the body to keep the internal environment at the optimum for body functioning.



### SELECTIVE FOCUS

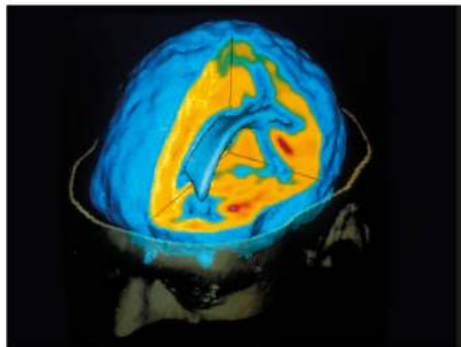
The nose sends streams of “smell” nerve signals to the brain. We can choose to ignore these or to focus on them, as part of the mind’s selective awareness.

NERVOUS SYSTEM

76–129

ENDOCRINE SYSTEM

130–143



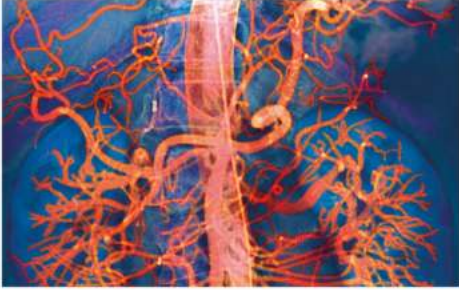
### BRAIN ACTIVITY

This image is a three-dimensional functional MRI scan showing brain activity during speech. Red indicates areas of high activity, yellow indicates medium activity, while blue indicates low activity.

Different information carriers called hormones are secreted by endocrine glands into the bloodstream to stimulate distant tissues to action. More than 50 hormones circulate in the bloodstream. The specific molecular structure of each hormone stimulates only those cells that have suitable receptors on their surface, instructing the cells to carry out certain processes. In general, nerves work fast – within fractions of a second. Most hormones function over longer time periods – minutes, days, or even months. Long-lasting effects, as in growth hormone for example, occur because the hormone is continuously secreted over a period of many years; an individual dose would last only a few days.

# THE FLUID BODY

ROUGHLY TWO-THIRDS OF THE BODY IS COMPOSED OF WATER AND THE VARIOUS ESSENTIAL SUBSTANCES DISSOLVED IN IT. THESE FLUIDS ARE FOUND IN CELLS, AROUND THE BODY'S TISSUES, AND, MOST OBVIOUSLY, IN BLOOD AND LYMPH.



## CIRCULATORY NETWORK

Blood is the fastest-circulating “fluid” in the body. Its liquid component, plasma, is constantly exchanging fluids with other body systems and structures.

There are about 40 litres (70 pints) of water in the average adult body, and it makes up the major part of most body parts. Tissues are 70–80 per cent water; blood plasma is more than 90 per cent; bones contain almost 25 per cent; and fat is 10–15 per cent water.

## TYPES AND FUNCTIONS OF FLUIDS

There are two major categories of body fluids – intracellular and extracellular. Intracellular fluid (also called cytoplasm) is found inside cells. Extracellular fluid accounts for all other fluids in the body. Its subcategories are: interstitial fluid in the spaces between cells and tissues; blood plasma and lymph; the fluids in bones, joints, and dense connective tissue; and transcellular fluid, which includes saliva, mucus, sweat, and urine.

Water is an excellent solvent and the thousands of substances dissolved in it are used in the biochemical reactions that are the very basis of life. Water also distributes

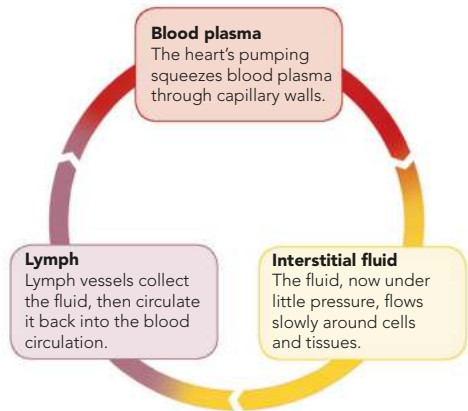
CARDIOVASCULAR SYSTEM 144–159

LYMPH AND IMMUNE SYSTEMS 190–209

nutrients around the body and collects and delivers wastes. Fluids spread heat from active areas to cooler ones, and act as shock absorbers to cushion sensitive areas such as the brain. Fluids also work as lubricants, so that tissues and organs slip past each other with minimal friction.

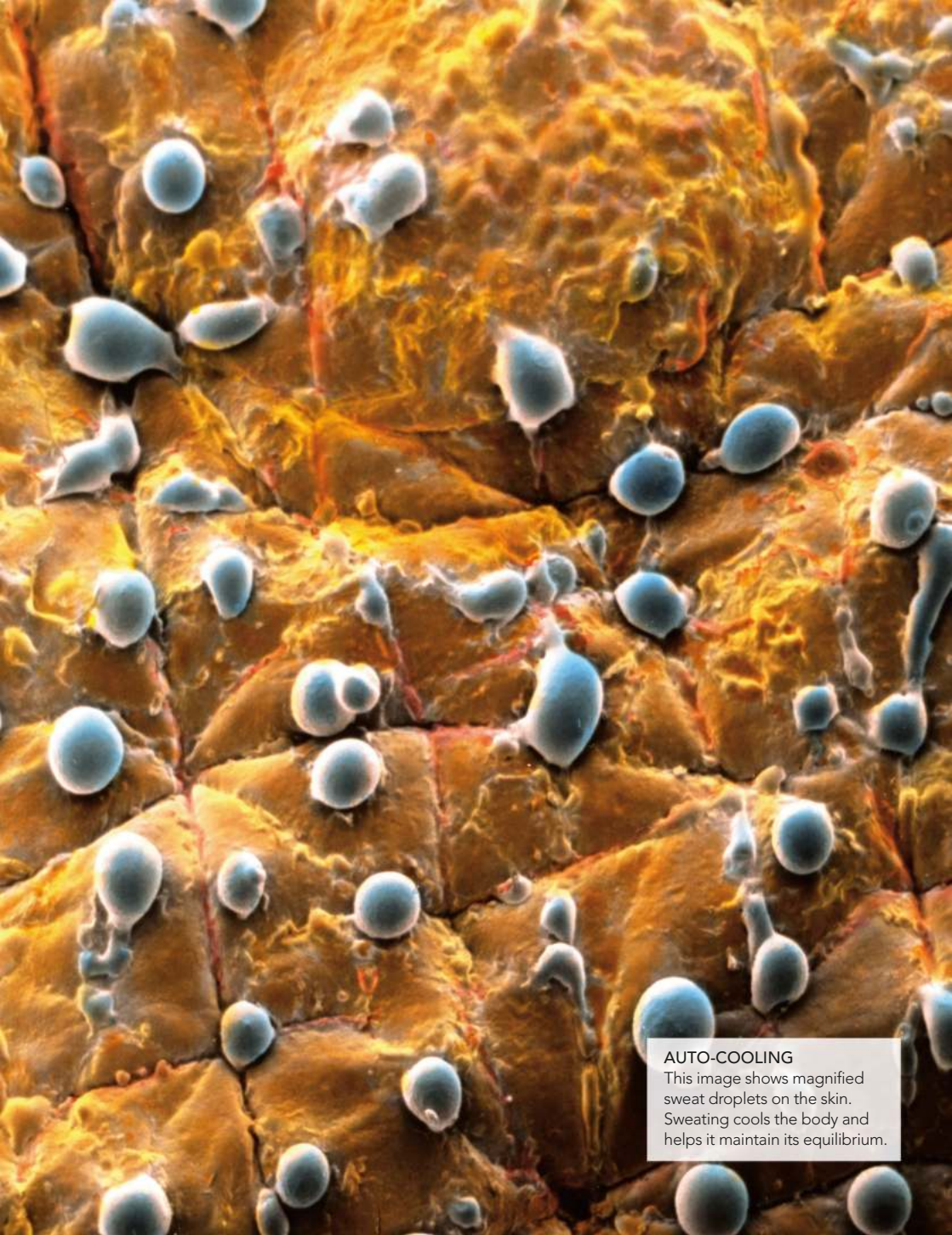## BLOOD AND LYMPH

The blood and lymphatic circulatory systems are constantly swapping fluids (see the illustration below). Blood plasma transports red blood cells, white blood cells, platelets, and a wide variety of nutrients and chemicals around the body. Lymph fluid carries white blood cells and other substances, such as fats and proteins.



## BLOOD PLASMA AND LYMPH CYCLE

Blood plasma leaks from capillaries to form interstitial fluid. Some of this drains into lymph vessels to become lymph fluid, which then returns to the blood circulation.



#### **AUTO-COOLING**

This image shows magnified sweat droplets on the skin. Sweating cools the body and helps it maintain its equilibrium.



# EQUILIBRIUM

THE BODY'S CELLS AND TISSUES ONLY FUNCTION WELL IF ALL ASPECTS OF THEIR ENVIRONMENT ARE KEPT STABLE AND IN EQUILIBRIUM. SEVERAL BODY SYSTEMS MAINTAIN A BALANCED INTERNAL ENVIRONMENT, A PROCESS CALLED HOMEOSTASIS.

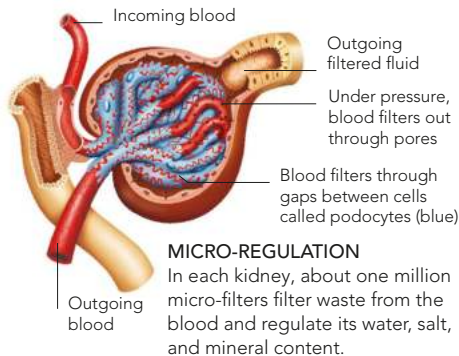
The biochemical reactions in cells are attuned to specific conditions, such as oxygen levels, acidity, water levels, and temperature. These must be maintained within the correct limits or the reactions go awry and the body malfunctions.

## HOMEOSTATIC SYSTEMS

Several systems contribute to homeostasis. For example, the respiratory system ensures that oxygen levels are maintained; the digestive system takes in and processes nutrients; and the circulatory system distributes oxygen and nutrients and gathers waste products, which are removed by the urinary and respiratory systems.

## CONTROL AND FEEDBACK

The body's major control systems, nerves and hormones, are mainly responsible for coordinating homeostatic mechanisms using feedback loops. For example, if water levels in the tissues fall, body fluids become more concentrated. Sensors detect this and feed back information to the brain, whose homeostatic centres

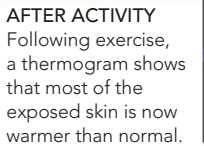


CARDIOVASCULAR SYSTEM	144-159
RESPIRATORY SYSTEM	160-175
SKIN, HAIR, AND NAILS	176-189
DIGESTIVE SYSTEM	210-239
URINARY SYSTEM	240-249



### BEFORE ACTIVITY

In this thermogram, temperature is graded from blue (cooler) to red (warmer).



### AFTER ACTIVITY

Following exercise, a thermogram shows that most of the exposed skin is now warmer than normal.

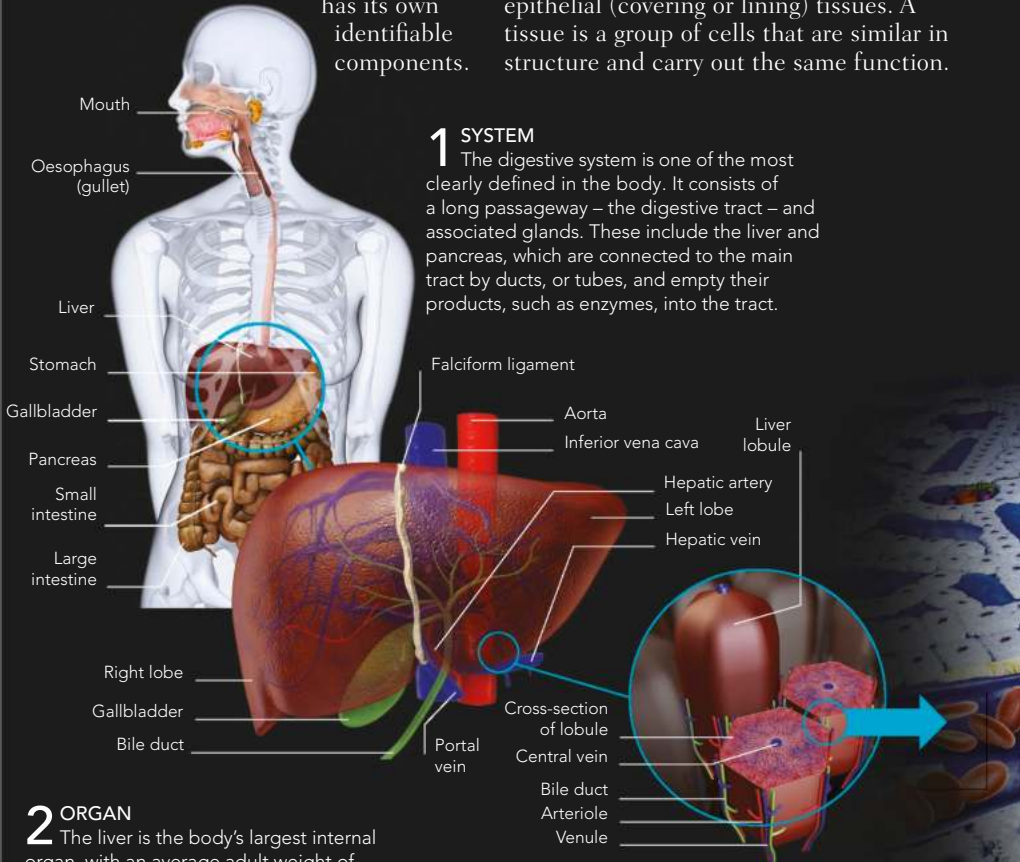
trigger regulating actions. Hormonal control of urinary excretion is adjusted to conserve water, and nervous activity produces thirst so that we drink. The sensors detect the changes as fluid concentrations return to normal, then they switch off until needed again. Thermoregulation – maintaining an approximately constant body temperature – uses the same feedback principles, with mechanisms such as sweating, blood flow to the skin, and shivering being used to regulate heat loss, conservation, and generation. In these ways, conditions inside the body are kept relatively stable, and an ongoing equilibrium is maintained.

# BODY SYSTEMS TO CELLS

EACH SYSTEM CAN BE SEEN AS A HIERARCHY. THE SYSTEM ITSELF IS AT THE TOP OF THE HIERARCHY; NEXT ARE ITS ORGANS; THEN THE TISSUES THAT MAKE UP THE ORGANS; AND AT THE BOTTOM ARE THE CELLS FROM WHICH TISSUES ARE MADE.

A body system is usually regarded as a collection of organs and parts designed for one important task. The systems are integrated and interdependent, but each has its own identifiable components.

The main parts of a system are its organs and tissues. Most organs are composed of different tissues. The brain, for example, contains nervous, connective, and epithelial (covering or lining) tissues. A tissue is a group of cells that are similar in structure and carry out the same function.



## 1 SYSTEM

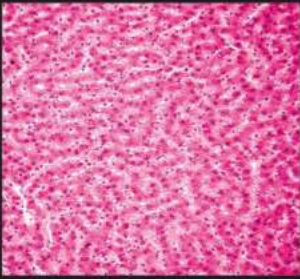
The digestive system is one of the most clearly defined in the body. It consists of a long passageway – the digestive tract – and associated glands. These include the liver and pancreas, which are connected to the main tract by ducts, or tubes, and empty their products, such as enzymes, into the tract.

## 2 ORGAN

The liver is the body's largest internal organ, with an average adult weight of 1.5kg (3½lb), which is slightly more than the brain. Within the liver is a system of tubes for carrying away its digestive product, bile, which is stored in the small sac under its right end, the gallbladder.

## 3 ORGAN SUBSTRUCTURE

The structural–functional units of the liver are hepatic lobules. The lobules are six-sided and have blood vessels and bile ducts inside and between them.



**MICRO-SECTION OF LIVER**

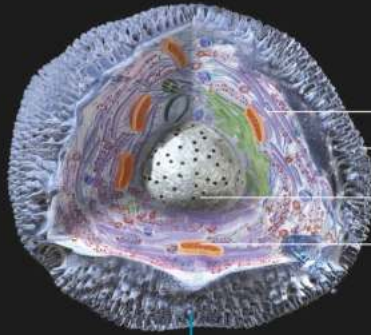
In this magnified section of liver tissue, the cells (pink) and their nuclei (dark purple) are visible. Blood cells lie in the lighter areas between the cells (hepatic sinusoids).

**Kupffer cell**

Also known as a hepatic macrophage, a type of white blood cell specific to the liver that engulfs and digests old worn-out blood cells and other debris

**4 TISSUE**

The unique tissue of the liver consists of branching sheets, or laminae, of liver cells (hepatocytes) arranged at angles. These are permeated by fluids and microscopic branches of two main kinds of tubes: blood vessels and bile ducts.



- Cytoplasm
- Cell membrane
- Nucleus
- Mitochondrion

**5 CELL**

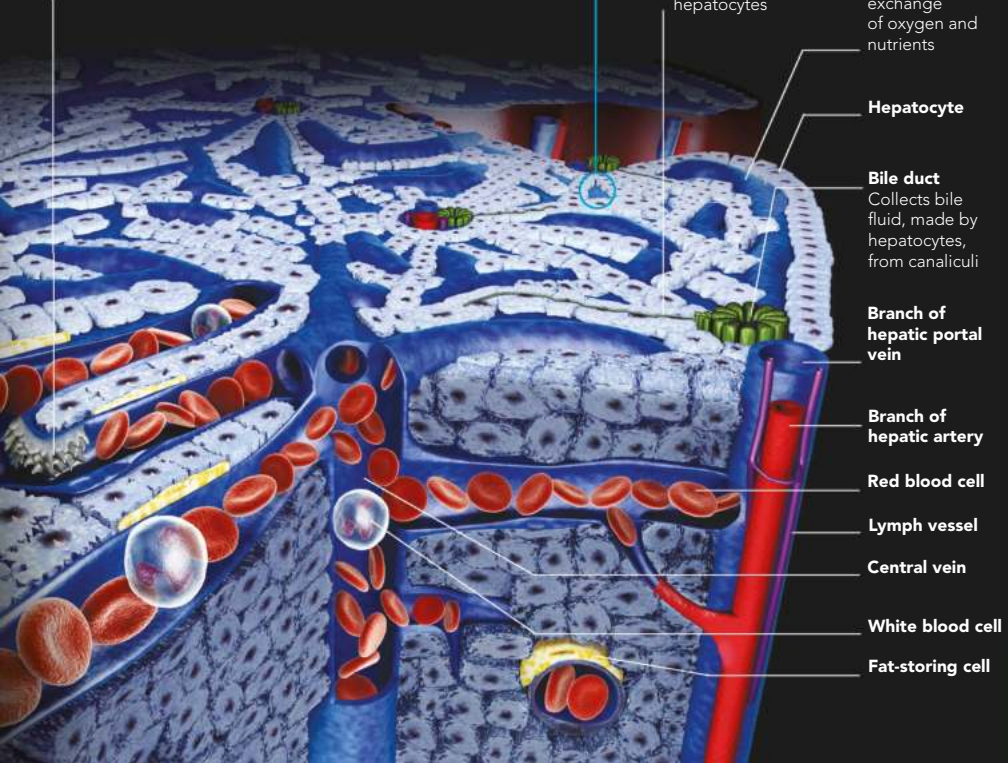
The fundamental living unit of all body tissues, a typical cell is capable of obtaining energy and processing nutrients. The hepatocytes of the liver are examples of body cells, containing most types of the miniature structures known as organelles inside them.

**Bile canaliculus**

Smallest branch of bile duct; snakes between hepatocytes

**Sinusoid**

A blood vessel with many pores that allow for the exchange of oxygen and nutrients



**Hepatocyte**

**Bile duct**

Collects bile fluid, made by hepatocytes, from canaliculi

**Branch of hepatic portal vein**

**Branch of hepatic artery**

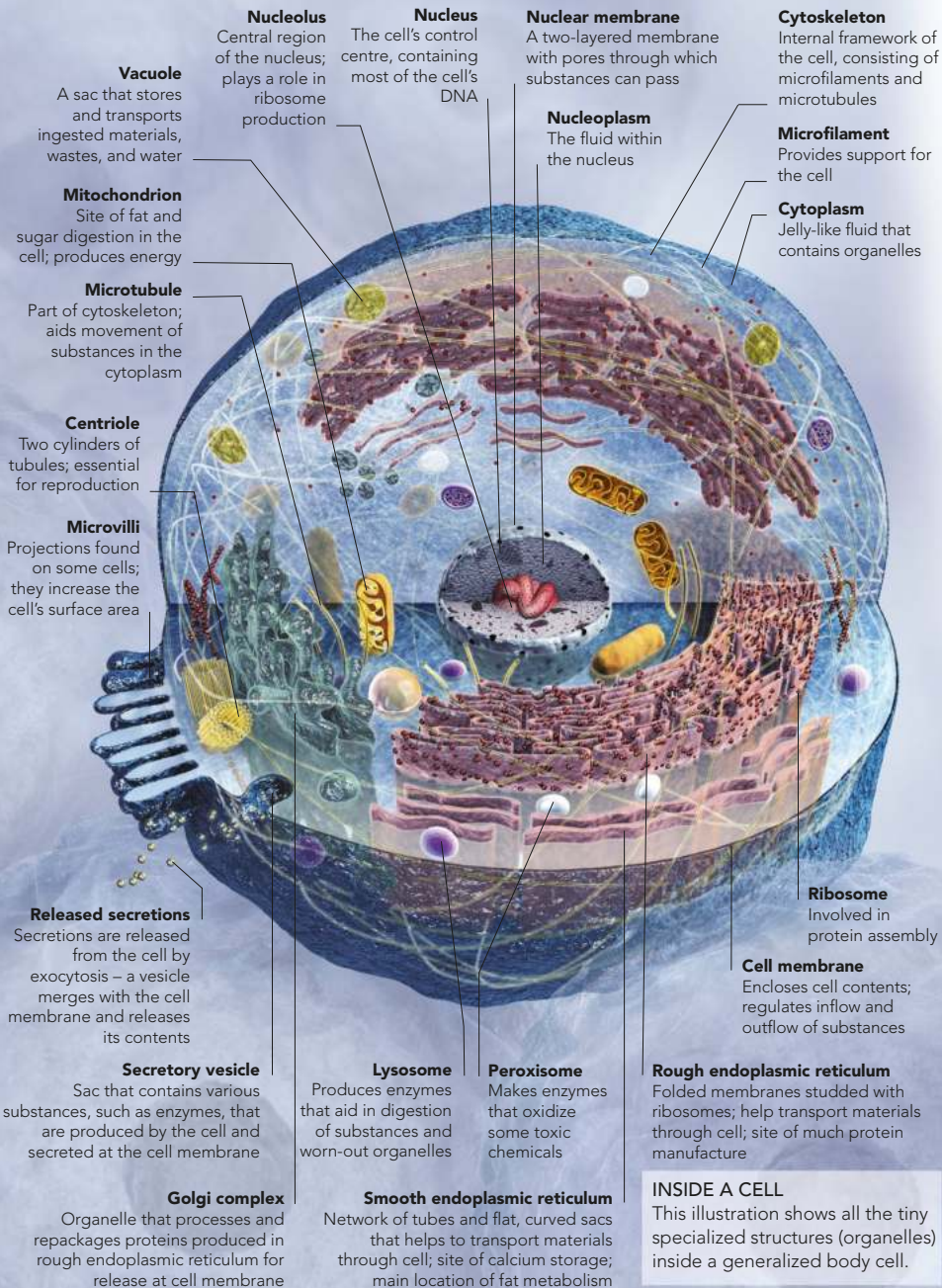**Red blood cell**

**Lymph vessel**

**Central vein**

**White blood cell**

**Fat-storing cell**



**Vacuole**

A sac that stores and transports ingested materials, wastes, and water

**Mitochondrion**

Site of fat and sugar digestion in the cell; produces energy

**Microtubule**

Part of cytoskeleton; aids movement of substances in the cytoplasm

**Centriole**

Two cylinders of tubules; essential for reproduction

**Microvilli**

Projections found on some cells; they increase the cell's surface area

**Released secretions**

Secretions are released from the cell by exocytosis – a vesicle merges with the cell membrane and releases its contents

**Secretory vesicle**

Sac that contains various substances, such as enzymes, that are produced by the cell and secreted at the cell membrane

**Golgi complex**

Organelle that processes and repackages proteins produced in rough endoplasmic reticulum for release at cell membrane

**Nucleolus**

Central region of the nucleus; plays a role in ribosome production

**Nucleus**

The cell's control centre, containing most of the cell's DNA

**Nuclear membrane**

A two-layered membrane with pores through which substances can pass

**Nucleoplasm**

The fluid within the nucleus

**Cytoskeleton**

Internal framework of the cell, consisting of microfilaments and microtubules

**Microfilament**

Provides support for the cell

**Cytoplasm**

Jelly-like fluid that contains organelles

**Ribosome**

Involved in protein assembly

**Cell membrane**

Encloses cell contents; regulates inflow and outflow of substances

**Lysosome**

Produces enzymes that aid in digestion of substances and worn-out organelles

**Peroxisome**

Makes enzymes that oxidize some toxic chemicals

**Rough endoplasmic reticulum**

Folded membranes studded with ribosomes; help transport materials through cell; site of much protein manufacture

**Smooth endoplasmic reticulum**

Network of tubes and flat, curved sacs that helps to transport materials through cell; site of calcium storage; main location of fat metabolism

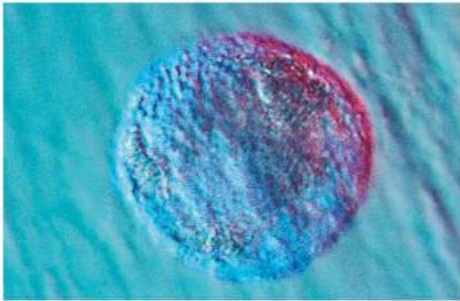
**INSIDE A CELL**  
This illustration shows all the tiny specialized structures (organelles) inside a generalized body cell.

# THE CELL

THE CELL IS THE BASIC UNIT OF THE BODY. IT IS THE SMALLEST PART CAPABLE OF THE PROCESSES THAT DEFINE LIFE, SUCH AS REPRODUCTION, MOVEMENT, RESPIRATION, DIGESTION, AND EXCRETION – ALTHOUGH NOT ALL CELLS HAVE ALL THESE ABILITIES.

## CELL ANATOMY

Most cells are microscopic – a typical cell is 20-30µm in diameter, which means 40 in a row would stretch across a full stop. Very specialized, long, thin cells include neurons (nerve cells) and muscle fibre



cells (myofibres), which may be more than 30cm (12in) long. Most cells have an outer flexible “skin”: the cell, or plasma, membrane. Inside are structures known as organelles, each with a characteristic shape, size, and function. These organelles do not float about at random. The cell is highly organized, with interior compartments linked by sheets and membranes and held in place by a flexible, lattice-like “skeleton” of even tinier tubules and filaments.

### EMBRYONIC STEM CELL

Stem cells are unspecialized “beginner” cells that can develop into specialized cells. Stem cells in the embryo can develop into any of the 200-plus types of specialized cells in the body.

## CELL TYPES

Cells come in many shapes and sizes, depending on their specialized functions within tissues. Speed of cell division also varies. It is most rapid in epithelial (covering and lining) cells, which are subjected to

physical abrasion and wear and which must continually replace themselves. It is slow or even nonexistent in some cells that are structurally complex, such as nerve cells (neurons).

### Epithelial cells

These cells form skin, cover most organs, and line hollow cavities such as the intestinal tract.



### Photoreceptor cell

A cone cell is a type of light- and colour-sensitive cell in the retina of the eye.



### Red blood cell

The double-dished (biconcave) red cell (erythrocyte) is a bag of oxygen-carrying haemoglobin molecules.



### Adipose (fat) cell

The main adipose cells, adipocytes, are bulky and crammed with droplets of fat (lipids), which store energy.



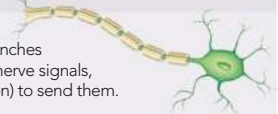
### Smooth muscle cell

The large, elongated, spindle-like cells of smooth muscle contract by sliding strands of protein inside.



### Nerve cell

Each cell has short branches (dendrites) to receive nerve signals, and a long “wire” (axon) to send them.



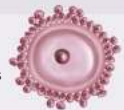### Sperm cell

Each sperm has a head that carries the paternal genetic material, and a whip-like tail for propulsion.



### Ovum (egg) cell

These giant cells contain the maternal genetic material, and energy resources for the embryo’s first cell divisions.



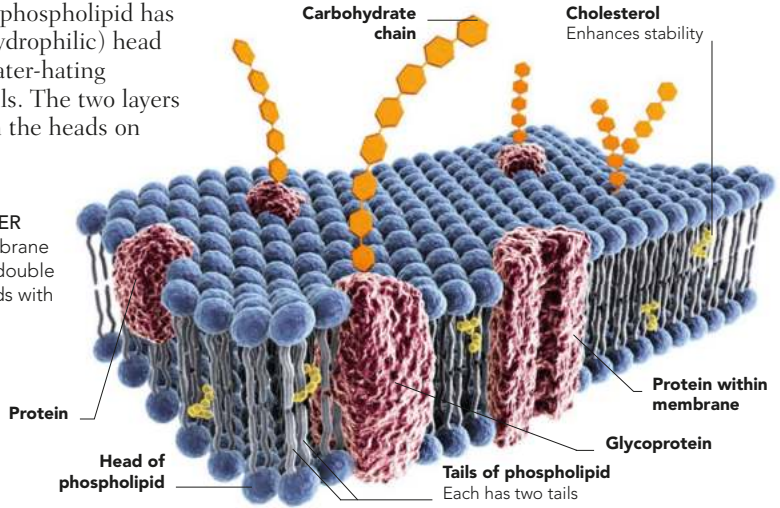
## CELL MEMBRANE

Several features allow the membrane to fulfil its dual functions of protecting the cell's contents and permitting movement of materials into and out of the cell. The primary component of this membrane is a double layer of phospholipid molecules. Each phospholipid has a water-loving (hydrophilic) head group and two water-hating (hydrophobic) tails. The two layers are arranged with the heads on

the outside and inside of the cell membrane, and the tails in between. The phospholipids are interspersed with protein molecules and carbohydrate chains that allow the cell to be recognized by other body cells.

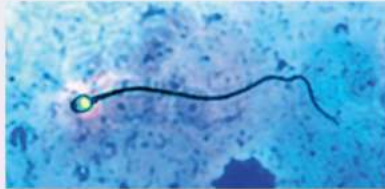
### PERMEABLE BI-LAYER

The typical cell membrane is characterized by a double layer of phospholipids with embedded proteins.



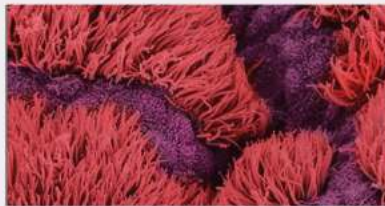
## SURFACE ORGANELLES

Some cells in the body have specialized structures projecting from their surface. Cells lining the small intestine have small, finger-like projections called microvilli, which increase the surface area for absorption of nutrients. Some cells in the female reproductive tract have small, hair-like cilia that wave to move the ovum along the oviduct; similar ciliated cells in the respiratory tract move small particles out of the airways. The sperm is unique in the human body in having a long, whip-like flagellum, used for propulsion.



### SPERM

The thin tail (flagellum) that extends from a human sperm cell is used like a propeller to help the sperm swim up the female genital tract.

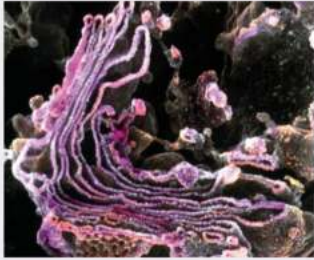

### CILIATED CELLS

Some of the cells lining the fallopian tubes have hair-like cilia (coloured pink in this micrograph) that brush an egg along towards the uterus.

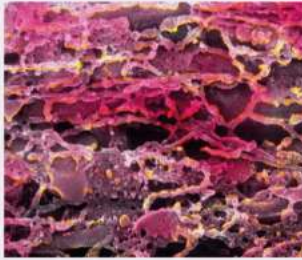
## MEMBRANES OF ORGANELLES

Membranes divide the cytoplasm into sections and control the passage of materials between these regions, act as attachment points and storage areas, and shape channels along which substances move.



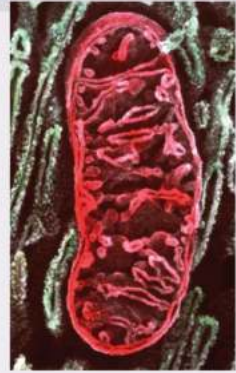### GOLGI COMPLEX

Within the membranous sacs of the Golgi complex, protein from the endoplasmic reticulum is processed.



### ENDOPLASMIC RETICULUM (ER)

A series of highly folded and curved ER membranes usually encloses one continuous labyrinthine space.



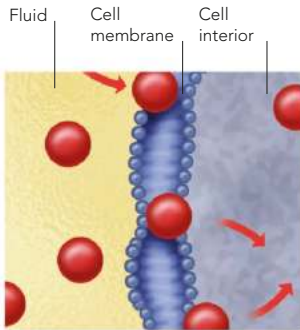
### MITOCHONDRION

The inner membrane is folded to increase the area for releasing energy.

## TRANSPORT

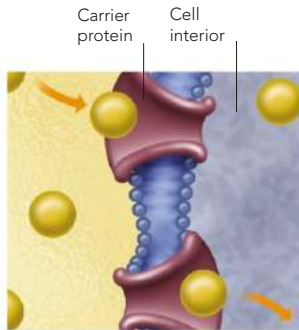
The transfer of materials through the cell membrane occurs by one of three processes. Small molecules, such as water, oxygen, and carbon dioxide, cross the membrane by diffusion. Molecules that cannot cross the

phospholipid layer must cross by facilitated diffusion. When substances (such as minerals and nutrients) are lower in concentration on the outside of the cell than on the inside, they can only be conveyed into the cell by active transport, which requires energy.



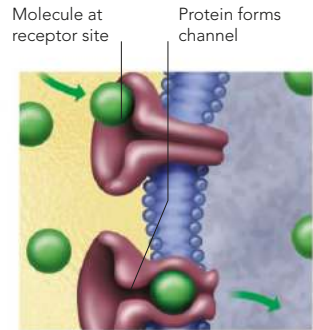
### DIFFUSION

Many molecules naturally move from an area where they are at high concentration to one in which their concentration is lower.



### FACILITATED DIFFUSION

A carrier protein binds with a specific molecule outside the cell, then changes shape and ejects the molecule into the cell.




### ACTIVE TRANSPORT

Molecules bind to a receptor site on the cell membrane, triggering a protein to change into a channel through which molecules travel.

# DNA

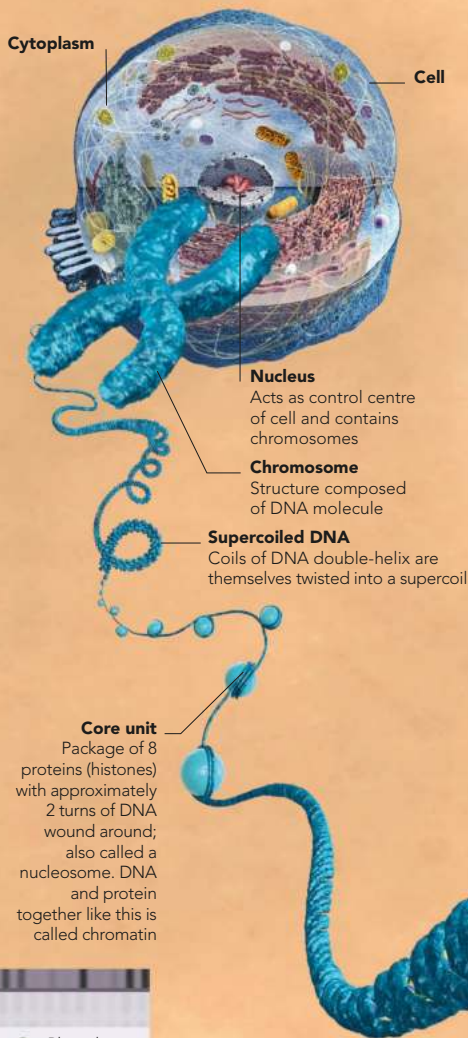
KNOWN AS THE "MOLECULE OF LIFE", THE CHEMICAL DNA (DEOXYRIBONUCLEIC ACID) CONTAINS THE INSTRUCTIONS, KNOWN AS GENES, FOR THE BODY'S GROWTH, FUNCTION, AND REPAIR.

In nearly all human cells, DNA is packaged into 46 coiled structures called chromosomes, situated in the cell's nucleus. DNA's list of instructions takes the form of long, thin molecules, one per chromosome, each forming a double-helix shape. Each double-helix has two long strands that corkscrew around each other. These are linked by rungs, like a ladder. The rungs are made of pairs of chemicals called bases: adenine (A), guanine (G), thymine (T), and cytosine (C). A always pairs with T, and G with C. The order of the bases contains the chromosome's genetic code, while the way the bases link enables DNA to make copies of itself.



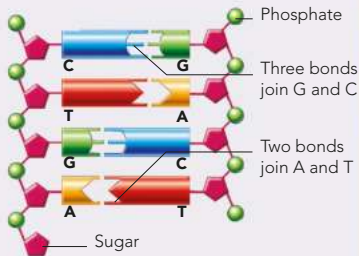
### DNA UNDER THE MICROSCOPE

This scanning tunnelling micrograph (STM) of DNA, magnified about one million times, shows the twists of the helix as a series of yellow peaks on the left.



### BASE PAIRS

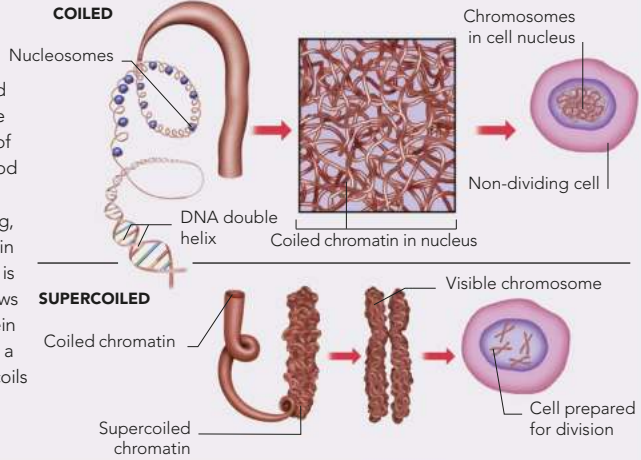
The four bases can pair in only two configurations due to their chemical structures. Adenine and thymine each have two positions for forming hydrogen bonds and so fit together, while guanine and cytosine each have three hydrogen-bond locations.





## COILS AND SUPERCOILS

DNA's coiled structure allows an incredible length to be packed into a tiny space. If unwound, the DNA in a chromosome would stretch about 5cm (2in). There are 46 chromosomes in the nucleus of each cell (except mature red blood cells, which have no nucleus or DNA). When cells are not dividing, the DNA (wrapped around protein to form what is called chromatin) is relatively loosely coiled. This allows portions to be available for protein assembly and other functions. As a cell prepares to divide, its DNA coils into supercoils, which are shorter and denser, and visible as the typical chromosome "X" shapes.



### DNA backbone

Constructed of alternating units of deoxyribose (a form of sugar) and phosphate chemicals

### Helical repeat

DNA helix twists once for every 10.4 rungs of base pairs

### Adenine-thymine link

Adenine always forms a base pair with thymine

### Cytosine

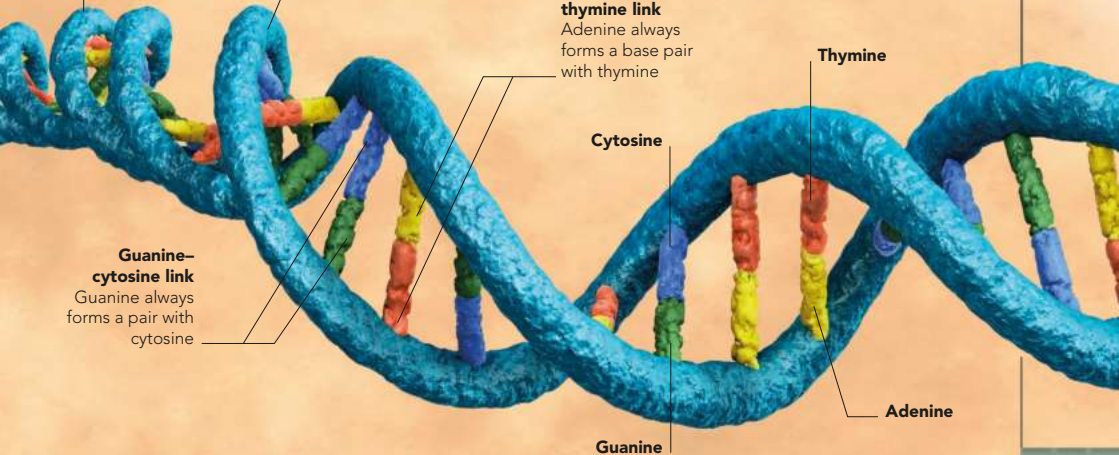
### Thymine

### Guanine-cytosine link

Guanine always forms a pair with cytosine

### Adenine

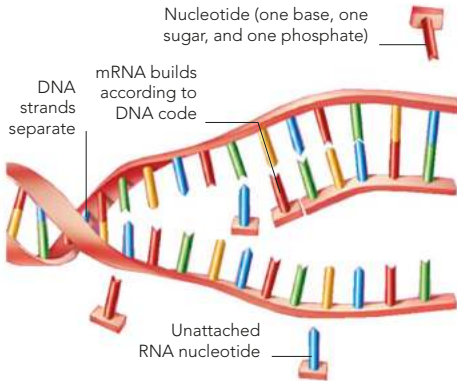
### Guanine



## HOW DNA WORKS

One of DNA's key functions is to provide the information to build proteins. Some proteins are the body's major structural molecules, while others form enzymes or hormones, which control chemical reactions within the body. Manufacture of proteins occurs in two main phases: transcription and translation. In transcription, information is taken from the DNA and copied to an intermediate type of molecule called mRNA (messenger ribonucleic acid). The mRNA moves out of the cell's

nucleus to protein assembly units called ribosomes. In the translation phase, the mRNA acts as a template for the formation of units of protein, known as amino acids. There are about 20 different amino acids. Their order is specified by lengths of mRNA three bases long, called triplet codons. The order of bases in each codon is the code for a particular amino acid (hence the term "genetic code"). The mRNA carries instructions to make a specific protein from a sequence of amino acids.

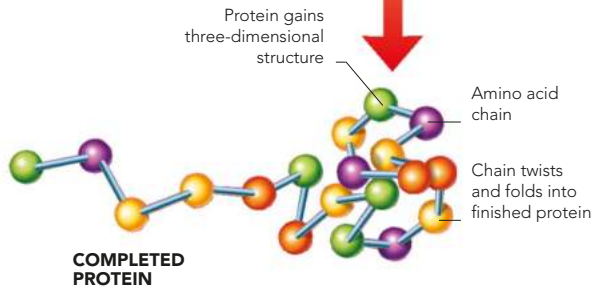
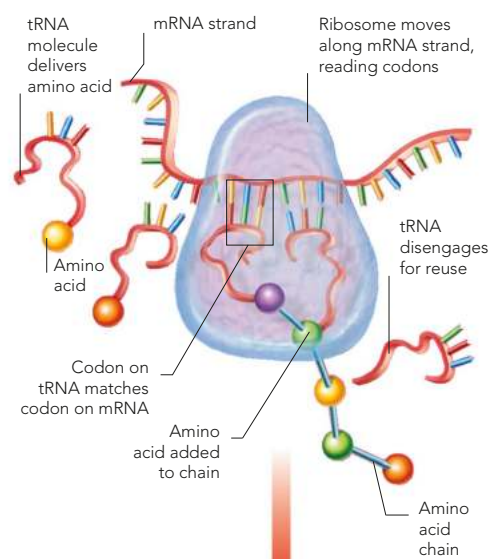


### 1 TRANSCRIPTION

In the cell's nucleus, the DNA strands temporarily separate, with one acting as the template for the formation of mRNA. Separate RNA nucleotides with the correct bases lock onto the exposed DNA bases in cross-linked fashion, thereby forming a mirror image of the DNA's information.

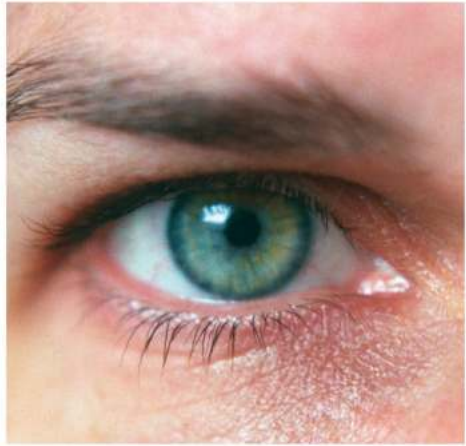### 2 TRANSLATION

In the cell's cytoplasm, the mRNA attaches to a ribosome. Individual tRNA (transfer ribonucleic acid) molecules have specific amino acids attached. They can slot onto the mRNA only if the order of their bases matches, ensuring they bring the correct amino acid. As the ribosome moves along the mRNA, the tRNAs bring the correct sequence of amino acids, which fit together to construct a protein.



## WHAT ARE GENES?

A gene is generally regarded as a unit of DNA needed to construct one protein. It consists of all the sections of DNA that code for all the amino acids for that protein. Usually, one gene is located on one chromosome. However, it may have several sections on the DNA molecule, each containing the code for one portion of the protein. Typically, lengths of DNA called introns and exons (see below) are both transcribed to form immature mRNA. The parts of mRNA made from the introns are then stripped out by the cell's molecular machinery, leaving mature mRNA for translation. There are also regulatory DNA sequences that code for their own proteins, affecting the rate of gene transcription.

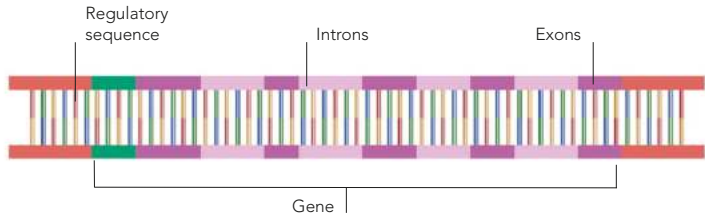


### EYE COLOUR

Iris colour is affected by at least 15 genes, including OCA2 and HERC2, both sited on chromosome 15.

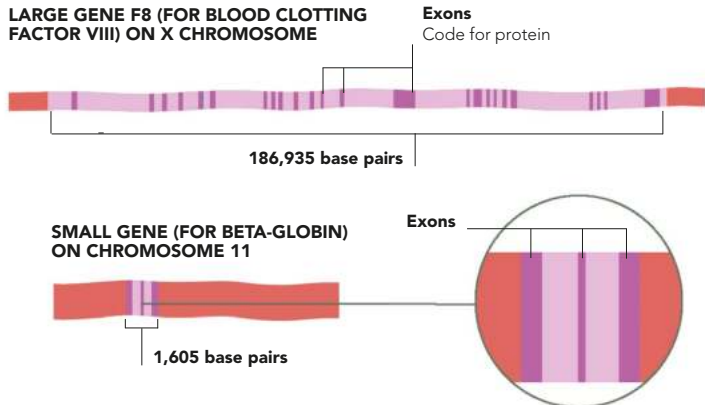
### PARTS OF A GENE

Regions called introns and exons both transcribe to form mRNAs for different portions of a protein. The lengths made from introns are then spliced out chemically, to leave exon-only portions, which go on to make the protein.



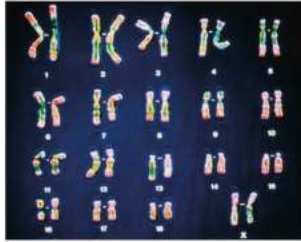### RANGE OF GENE SIZE

Genes vary enormously in their size, which is usually measured in numbers of base pairs. Small genes may be just a few hundred base pairs long, while others are measured in millions of base pairs. The gene for beta-globin is one of the smallest. It codes for part of the haemoglobin molecule. It is compared, right, with a larger gene.



# THE GENOME

A GENOME IS THE FULL SET OF GENETIC INSTRUCTIONS FOR A LIVING THING. THE HUMAN GENOME CONSISTS OF AN ESTIMATED 20,000 GENES FOR MAKING PROTEINS, CARRIED ON THE DOUBLE SET OF 46 CHROMOSOMES IN MOST BODY CELLS.



## KARYOTYPE


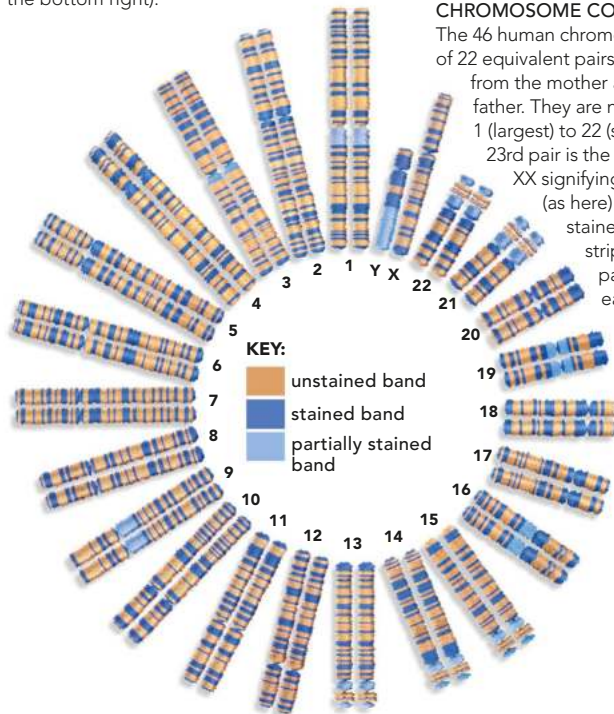
A karyotype is a photograph of all chromosomes from a cell arranged in a standard order. This example is from a female (note the two, equal-sized X chromosomes at the bottom right).

## CHROMOSOMES AND DNA

The Human Genome Project, a multinational effort to map the human genome, was completed in 2003. It led to the identification of more than 20,000 individual human genes within the 46 chromosomes that collectively include about 3.2 billion base pairs. Although much of the DNA that makes up the chromosomes does not code for proteins, known as non-coding and “junk” DNA, it may still regulate gene function. Junk DNA is different from non-coding DNA in that its structure does not resemble that of genes.

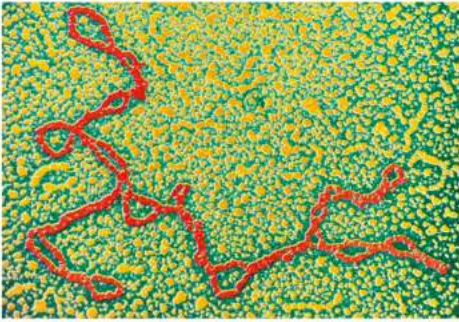
## CHROMOSOME COMPLEMENT

The 46 human chromosomes consist of 22 equivalent pairs, one of each pair from the mother and one from the father. They are numbered from 1 (largest) to 22 (smallest). The 23rd pair is the sex chromosomes, XX signifying female and XY (as here) male. When stained with chemicals, stripes called banding patterns show up on each chromosome.



## CHROMOSOME SEVEN

This chromosome contains more than 5 per cent of the genome's total DNA, with about 159 million pairs of bases. Almost 60 million are in the short arm, 7p, with the rest in the longer arm, 7q.



### MITOCHONDRIAL DNA

This electron microscope image shows that mitochondrial DNA forms a closed loop, unlike the DNA in the nucleus of the cell, which is linear.

## MITOCHONDRIAL GENES

Mitochondria, the powerhouses of the cell, have their own DNA. Unlike DNA in the nucleus, mitochondrial DNA (mtDNA) is circular, not linear. It contains just 37 genes which code for the proteins and RNA the mitochondrion needs for its functions. Mitochondrial DNA is unique in being inherited only from the maternal line, via the mitochondria present in the egg at fertilization. This type of DNA has been used to study genetic relationships and reunite families, as the high rate of mutation of mtDNA means unrelated people have very different mtDNA. Certain rare diseases are associated with changes in the mtDNA.

## GENETIC CONTROL OF CELLS

Not all genes are active in all cells. The process by which a gene is able to make its protein is called gene expression. The expression of each gene is regulated, or controlled, according to exposure to chemicals such as growth factors and regulators – products of other genes. Some genes are “switched on” and express themselves in most cells. These are concerned with basic processes such as utilizing glucose for energy. Other genes are “switched off” unless they are needed; these are for making specialized products, such as hormones. As cells’ genes are switched on and off in different circumstances, they differentiate, or become different.

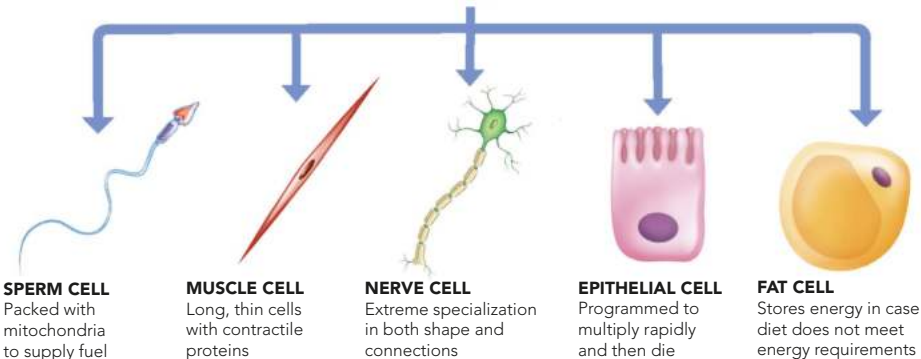
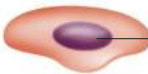
### CELLULAR DIFFERENTIATION

The first cells produced by divisions of a fertilized egg are “generalized” stem cells. As they multiply, pre-programmed instructions begin to act. Intercellular contacts and the chemical environment inform cells in certain parts of an embryo to differentiate into tissues such as nerves, muscle, and skin.

### PRECURSOR CELL

This can become any of a variety of cells. Some lines of offspring cells retain the ability to generalize, while others go on to become specialists

#### PRECURSOR CELL

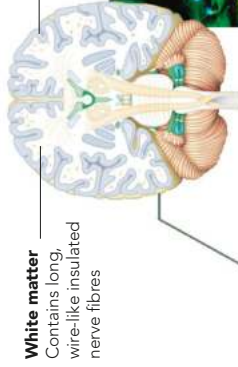


# SPECIALIZED CELLS AND TISSUES

MORE THAN 200 TYPES OF SPECIALIZED CELLS POPULATE THE HUMAN BODY. EACH TYPE FORMS CLOSELY KNIT CONFIGURATIONS, WHICH ARE RECOGNIZABLE AS SPECIFIC TISSUES. IN SOME CASES, TISSUES ARE MADE OF SEVERAL TYPES OF CELLS.

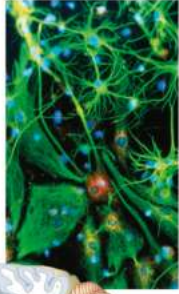
## TISSUE TYPES

The cells that form tissue all have much the same structure and perform the same function. Classically there are four primary tissue types, derived from specific cell layers in the early embryo: epithelial, connective, muscle, and nerve. Blood, bone, cartilage, tendons, and ligaments are forms of connective tissue. The epidermis and the tissues that line almost every organ are all types of epithelial tissues. Muscle and nerve tissues, of course, form muscles and nerves.



**White matter**  
Contains long, wire-like insulated nerve fibres

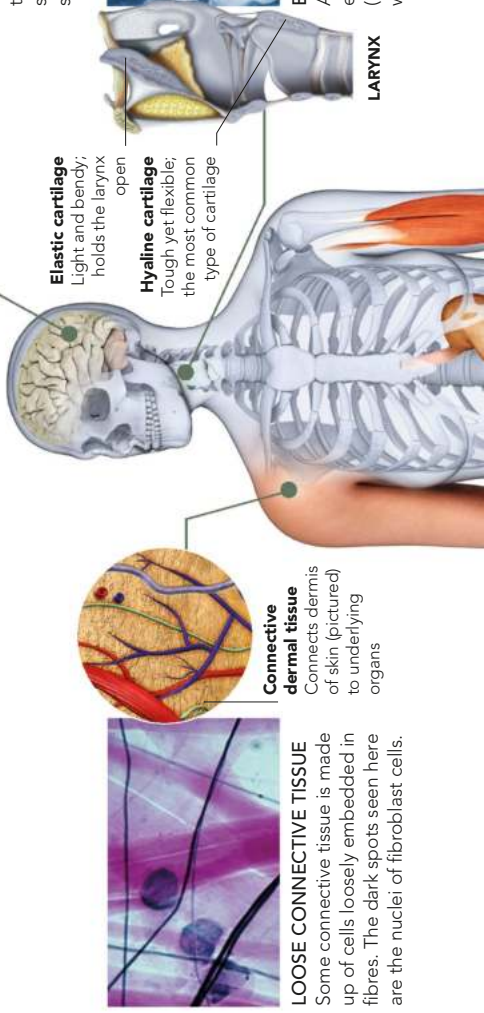
**Grey matter**  
Contains nerve-cell bodies and support cells



**NERVE TISSUE**

A microscope image of nerve tissue showing the glial cells that support nerve cells (neurons). The spider-like forms supply nutrients.

**CROSS-SECTION OF BRAIN FROM THE FRONT**




**Elastic cartilage**  
Light and bendy; holds the larynx open

**Hyaline cartilage**  
Tough yet flexible; the most common type of cartilage

**LARYNX**

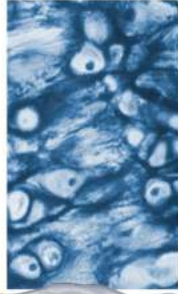
**Connective dermal tissue**  
Connects dermis of skin (pictured) to underlying organs

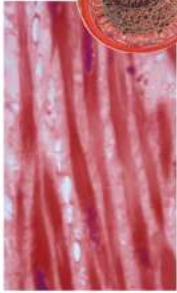
**LOOSE CONNECTIVE TISSUE**  
Some connective tissue is made up of cells loosely embedded in fibres. The dark spots seen here are the nuclei of fibroblast cells.



**ELASTIC CARTILAGE**

A sample of cartilage from the epiglottis reveals round cells (chondrocytes) in fibres of elastin, which make it light and flexible.

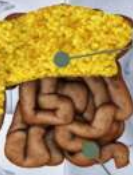



Longitudinal layer of smooth muscle

**SMOOTH MUSCLE TISSUE**

The long fibres in smooth muscle tissue contract involuntarily. They are found in many tubular internal parts, such as the intestines.



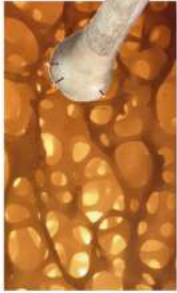
**SMALL INTESTINE**



**SKELETAL MUSCLE**

**SKELETAL MUSCLE TISSUE**

Each bundle of contractive filaments (seen here as stripes) is sheathed by white connective tissue. The dark spots are nuclei.

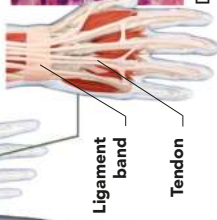


**SPONGY BONE TISSUE**

Spongy bone has a lightweight, honeycomb-like structure that accommodates bone marrow in its large open spaces.

Compact bone  
Spongy bone

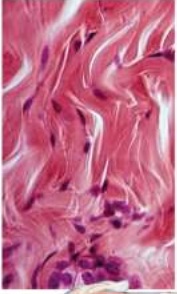
**STRUCTURE OF A LONG BONE**



Ligament band  
Tendon

**DENSE CONNECTIVE TISSUE**

This strong, dense tissue is found in ligaments, tendons, and, as shown above, in the lower layer of the skin (dermis).



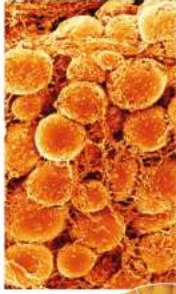**TENDONS OF THE HAND**

**Dermis**

Lower layer of skin

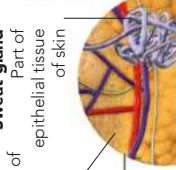
**Sweat gland**

Part of epithelial tissue of skin



**ADIPOSE TISSUE**

Adipocytes (shown here) are cells that form fatty connective tissue called adipose, found around internal organs and under the skin.

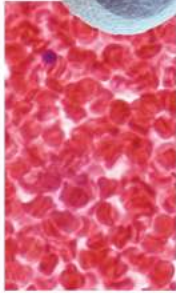


**Fat tissue**

Beneath dermis layer of skin

**SUBCUTANEOUS FAT**

WHITE BLOOD CELL

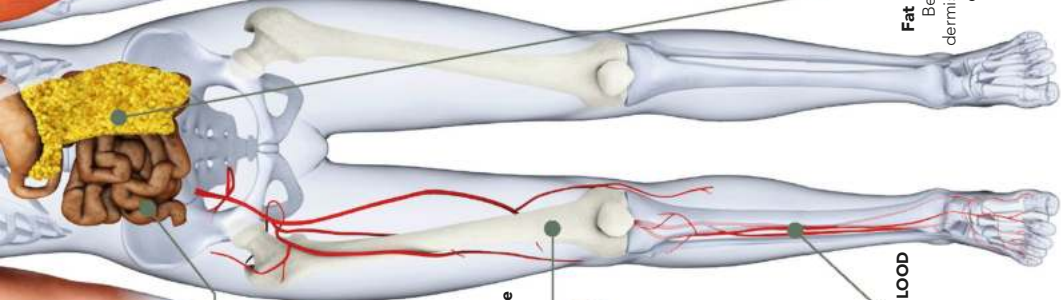


**BLOOD**

Blood is a fluid connective tissue. It comprises liquid plasma, carrying red and white blood cells, and cell fragments called platelets.

RED BLOOD CELL

PLATELET





THE LIVING SKELETON, WITH ITS VARIETY OF SPECIALIZED JOINTS, IS INTIMATELY CONNECTED WITH THE MUSCULAR SYSTEM. IT PROVIDES A FRAMEWORK OF STIFF LEVERS AND STABLE PLATES THAT PERMITS A MULTITUDE OF MOVEMENTS. THE SKELETON ALSO INTEGRATES FUNCTIONALLY WITH THE CARDIOVASCULAR SYSTEM – BONE MARROW CEASELESSLY MANUFACTURES FRESH BLOOD CELLS THAT POUR INTO THE BLOODSTREAM. A HEALTHY DIET AND REGULAR EXERCISE CAN HELP TO REDUCE THE RISKS OF BONE AND JOINT DISORDERS.



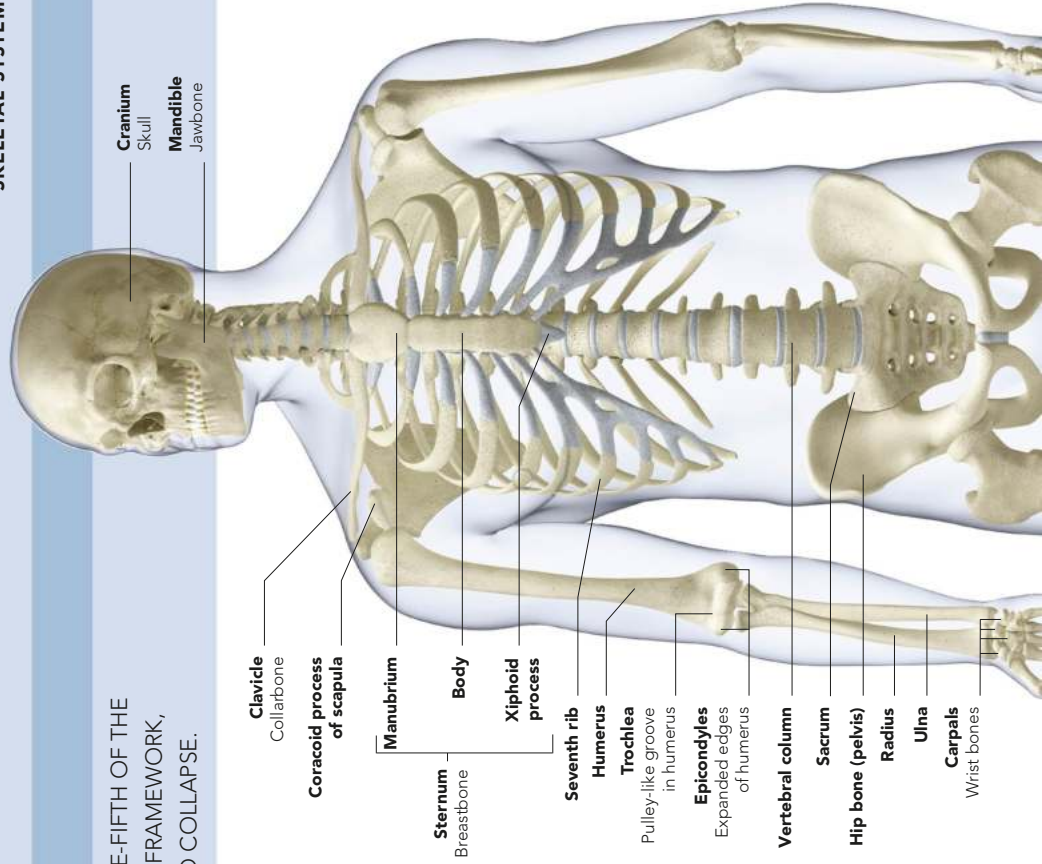
# SKELETAL SYSTEM



# SKELETON

THE SKELETON MAKES UP ALMOST ONE-FIFTH OF THE BODY'S WEIGHT. WITHOUT THIS INNER FRAMEWORK, ALL OTHER PARTS AND TISSUES WOULD COLLAPSE.

The average skeleton has 206 bones. There are natural variations: about one individual in 200 has an extra rib. Bone is an active tissue, and even though it is about 22 per cent water, it has an extremely strong yet lightweight and flexible structure. The skeleton has the advantage of being able to repair itself if damaged. It can also remodel its bones to thicken and strengthen them in areas of extra stress, as seen in some activities such as running and weight-lifting. The two major divisions of the skeleton are called the axial and appendicular skeletons. The axial skeleton consists of the skull, vertebral (spinal) column, ribs, and sternum. The appendicular skeleton includes the bones of the shoulder, arm, wrist, and hand, and the hips, legs, ankles, and feet. Of the 206 bones, 80 are in the axial skeleton, with 64 in the upper appendicular and 62 in the lower appendicular skeleton.





**PARIETAL BONES**  
**A FLAT BONE (PARIETAL)**  
**AN IRREGULAR BONE (SCAPULOID)**

**BONE SHAPES**

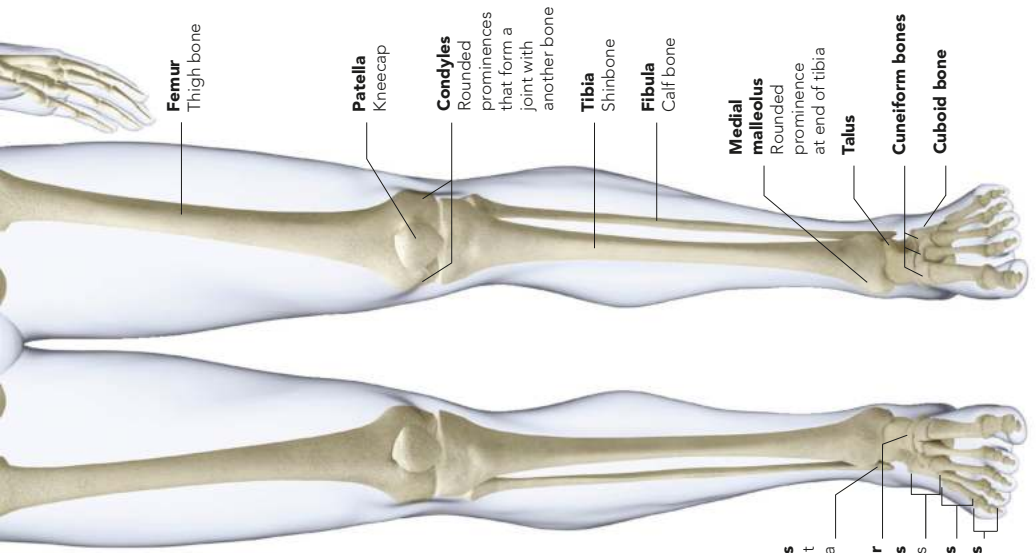
The shape of a bone indicates its function. Flat bones have large surface areas for the attachment of muscles; long bones work like levers; sesamoid bones are small and embedded within tendons.



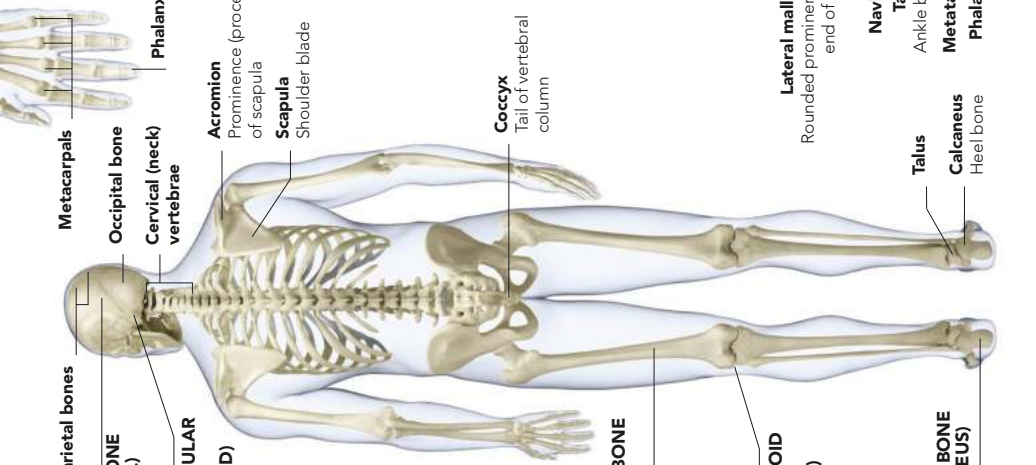
**A LONG BONE (FEMUR)**  
**A SESAMOID BONE (PATELLA)**



**A SHORT BONE (CALCANEUS)**



**Femur** Thigh bone  
**Patella** Kneecap  
**Condyles** Rounded prominences that form a joint with another bone  
**Tibia** Shinbone  
**Fibula** Calf bone  
**Medial malleolus** Rounded prominence at end of tibia  
**Talus**  
**Cuneiform bones**  
**Cuboid bone**



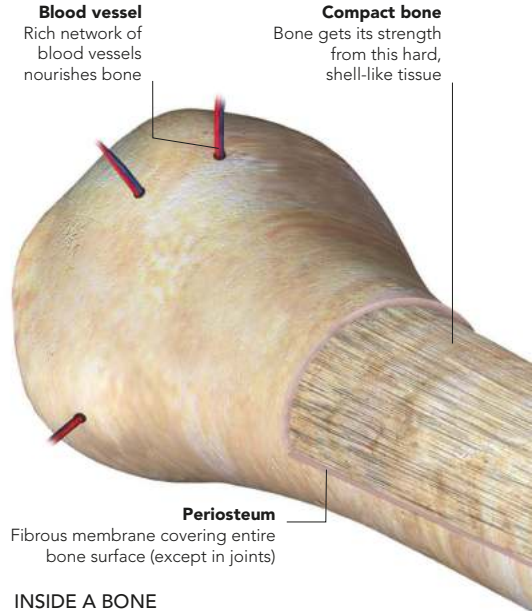
**Metacarpals**  
**Phalanx**  
**Acromion** Prominence (process) of scapula  
**Scapula** Shoulder blade  
**Coccyx** Tail of vertebral column  
**Lateral malleolus** Rounded prominence at end of fibula  
**Navicular**  
**Tarsals** Ankle bones  
**Metatarsals**  
**Phalanges**  
**Talus**  
**Calcaneus** Heel bone

# BONE STRUCTURE

BONE IS A TYPE OF CONNECTIVE TISSUE THAT IS AS STRONG AS STEEL BUT AS LIGHT AS ALUMINIUM. IT IS MADE OF SPECIALIZED CELLS AND PROTEIN FIBRES. NEITHER IMMOBILE NOR DEAD, BONE CONSTANTLY BREAKS DOWN AND REBUILDS ITSELF.

## STRUCTURE OF A BONE

Along the central shaft of a long bone (such as the femur or humerus) is the medullary canal or marrow cavity. This contains red bone marrow, which produces blood cells; yellow marrow, which is mostly fatty tissue; and blood vessels. Surrounding the marrow cavity is a layer of spongy (cancellous) bone, the honeycomb-like cavities of which also contain marrow. Around this is a layer of compact (cortical) bone, which is hard, dense, and strong. Small canals connect the marrow cavity with the periosteum – a membrane covering the bone surface. Bone tissue is made of specialized cells and protein fibres, woven into a matrix of water, mineral salts, and other substances. Bone cells include osteoblasts, which calcify bone as it forms; osteocytes, which maintain healthy bone structure; and osteoclasts, which absorb bone tissue where it is degenerating or not needed.



## INSIDE A BONE

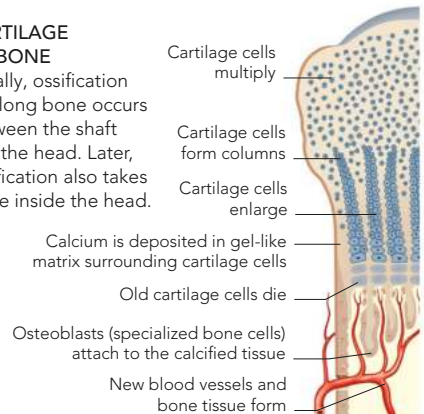
Long bones, for example those in the leg, comprise several different types of bone tissue.

## BONE GROWTH

During development in the womb and infancy, most bones develop from structures made of cartilage. Ossification is the process by which this cartilage is converted into bone tissue by the deposition of mineral salts and crystals. Near each end of a long bone is an area called the growth plate, where lengthening and ossification occur. Cartilage cells (see right) multiply here and form columns towards the bone shaft. As the cartilage cells enlarge and die, the space they occupied is filled by new bone cells.

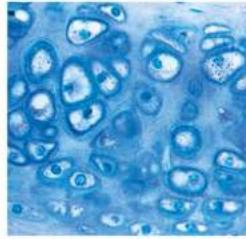
## CARTILAGE TO BONE

Initially, ossification in a long bone occurs between the shaft and the head. Later, ossification also takes place inside the head.



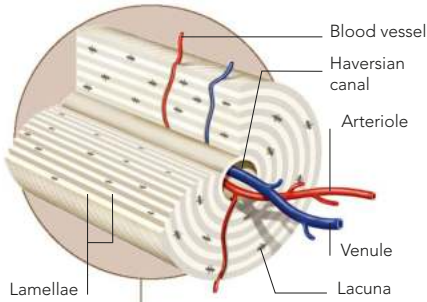
## CARTILAGE

Cartilage is a tough, adaptable form of connective tissue. It consists of a gel-like matrix containing many chemicals, such as proteins and carbohydrates. In this are embedded various types of fibres, and cells called chondrocytes, which make and maintain the whole tissue. There are several kinds of cartilage, including hyaline cartilage, fibrocartilage, and elastic cartilage, a springy material found at sites such as the outer ear flap and larynx.



### HYALINE CARTILAGE

Dense collagen fibres make this cartilage extra tough and resistant. It covers bone ends in joints, attaches ribs to the sternum, and is also found in the trachea and nose.



### OSTEON

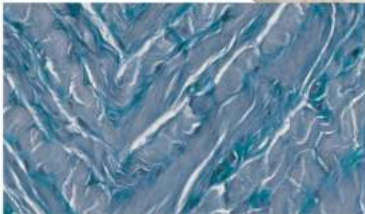
This rod-shaped unit is the building block of compact bone. Its central (Haversian) canal, containing blood vessels and nerves, is surrounded by concentric layers of tissue (lamellae). Gaps (lacunae) in the tissue contain osteocytes, which maintain bones.

### Bone marrow

Tissue filling a bone's central cavity; at first, long bones have red marrow – later this turns into yellow marrow

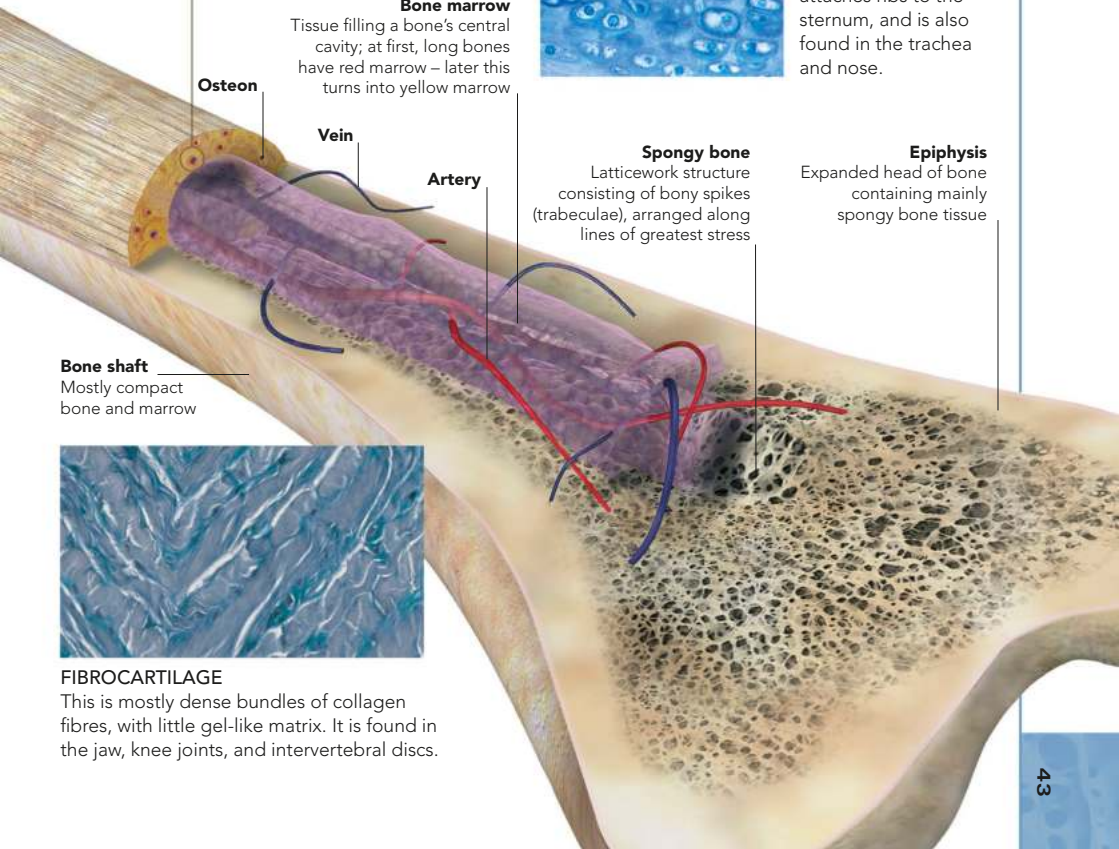
### Bone shaft

Mostly compact bone and marrow



### FIBROCARILAGE

This is mostly dense bundles of collagen fibres, with little gel-like matrix. It is found in the jaw, knee joints, and intervertebral discs.



Osteon

Vein

Artery

### Spongy bone

Latticework structure consisting of bony spikes (trabeculae), arranged along lines of greatest stress

### Epiphysis

Expanded head of bone containing mainly spongy bone tissue

# JOINTS

THE SITE AT WHICH TWO BONES LINK IS CALLED A JOINT OR AN ARTICULATION. JOINTS CAN BE CLASSIFIED ACCORDING TO THEIR STRUCTURE AND BY THE TYPES OF MOVEMENT THEY ALLOW. THE BODY HAS MORE THAN 300 DIFFERENT JOINTS.

## SYNOVIAL JOINTS

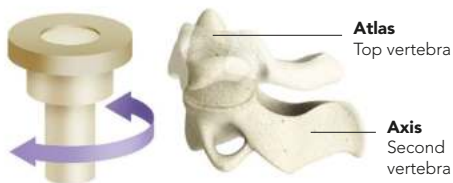
The body's most numerous, versatile, and freely moving joints are known as synovial joints. They can work well for many decades if kept in good use, but not overused. Synovial joints are enclosed by a protective outer covering – the joint capsule. The capsule's inner lining, called the synovial membrane, produces slippery, viscous synovial fluid that keeps the joint well lubricated so that the joint surfaces slide against each other with minimal friction and wear. There are around 230 synovial joints in the body.

## TYPES OF SYNOVIAL JOINT

A synovial joint's range of movement is determined by the shape of its articular cartilage surfaces (see p.46) and how they fit together.

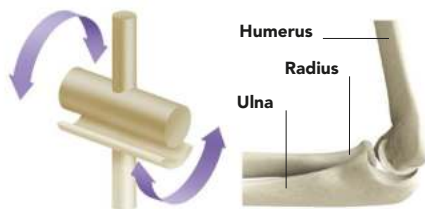
### Pivot joint

A peg-like projection from one bone turns in a ring-shaped socket of another bone; or, conversely, the ring turns around the peg. The pivot joint between the top two neck (cervical) vertebrae enables the skull to rotate on the spinal axis, and to move from side to side.



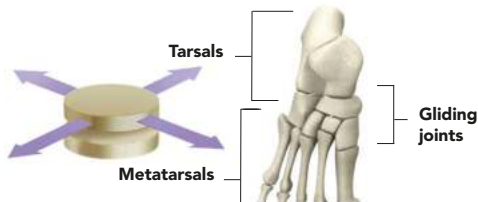
### Hinge joint

The convex surface of one bone fits into the concave surface of another bone to allow to-and-fro movement, mainly in one plane. The elbow is a modified hinge joint that permits limited rotation of the arm bones.



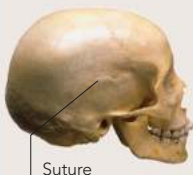### Gliding joint

The bone surfaces that meet in a gliding joint are almost flat and slide over one another. Movement is limited by ligaments. Some joints between the tarsals of the ankle and between the carpals in the wrist move in this way.



## SEMIMOVABLE AND FIXED JOINTS

Not all joints have a wide range of movement. Some allow for growth or for greater stability. The bones in these joints are usually linked by cartilage or tough fibres made of substances such as the protein collagen. In the fixed joints of the skull, once growth is complete, the separate bone plates are securely connected by interlocking fibrous tissue, forming suture joints.



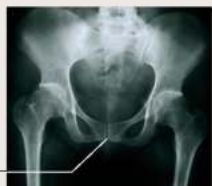### FIXED JOINT

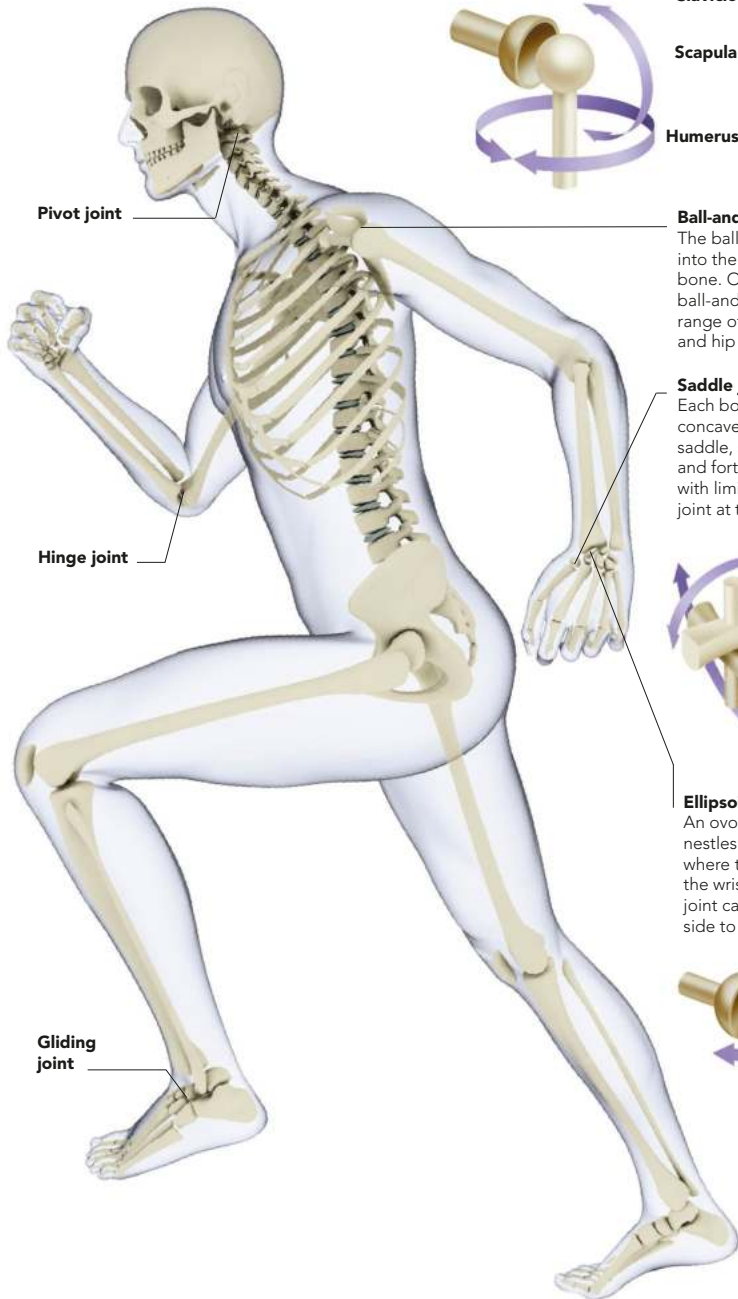The adult skull's suture joints show up as wiggling lines. In infancy, these joints are loosely attached to allow for expansion of the rapidly growing brain.

### SEMIMOVABLE JOINT

In partly flexible joints, bones are linked by fibrous tissue or cartilage, as in the pubic symphysis.

Pubic symphysis





Pivot joint

Hinge joint

Gliding joint

Clavicle

Scapula

Humerus

**Ball-and-socket joint**

The ball-shaped head of one bone fits into the cup-like cavity of another bone. Of all joint structures, a ball-and-socket joint gives the widest range of movement – the shoulder and hip are examples.

**Saddle joint**

Each bone's joint surface has both concave and convex areas, like a horse saddle, so the bones can slide back and forth and from side to side, but with limited rotation. There is a saddle joint at the base of the thumb.

Trapezium  
(wrist bone)First  
metacarpal  
of thumb**Ellipsoidal joint**

An ovoid (egg-shaped) bone end nestles in an ellipsoidal cavity, such as where the forearm's radius bone meets the wrist's scaphoid bone. This type of joint can be flexed and moved from side to side, but rotation is limited.

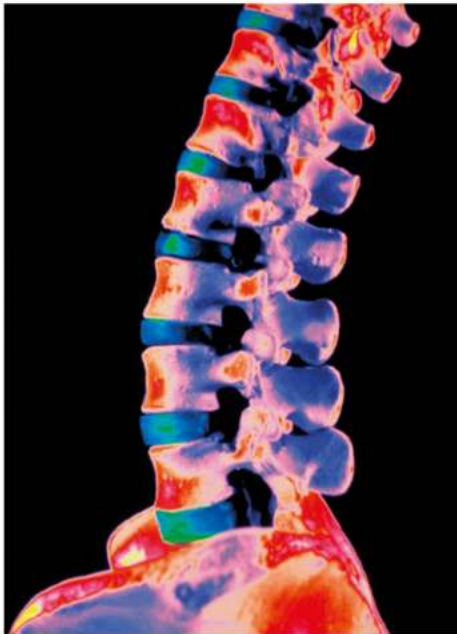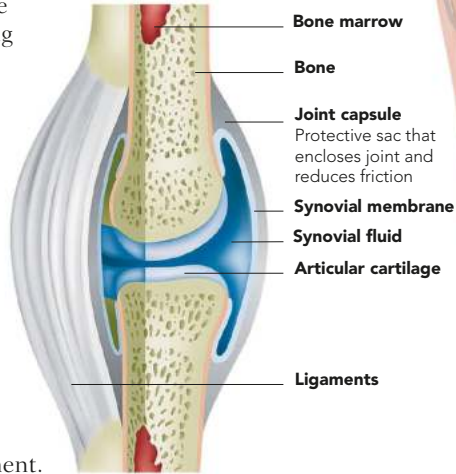
Radius  
Scaphoid

## INSIDE A JOINT

The bone ends in a synovial joint are covered by a smooth, slightly compressible tissue called articular cartilage. Surrounding the joint is the joint capsule, which is made of strong connective tissue and is attached to the bone ends. Its delicate inner lining, the synovial membrane, secretes viscous synovial fluid into the synovial cavity to keep the joint well oiled. The fluid also nourishes the cartilage with fats and proteins, and is constantly reabsorbed. Fibrous thickenings of the capsule, called ligaments, are anchored to the bones at each end and prevent unnatural movement of the joint. Muscles around the joint, which are connected to the bones by tendons, provide stability and produce movement.

## INSIDE A SYNOVIAL JOINT

A mere film of synovial fluid separates bone ends. There are just 1–2ml ( $\frac{3}{100}$ – $\frac{7}{100}$ fl oz) of this liquid in the knee joint.



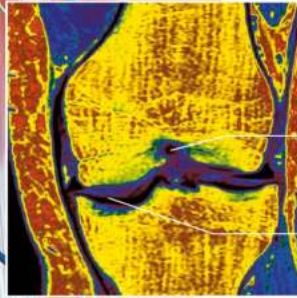
## CARTILAGE AS A SHOCK ABSORBER

The articular cartilage that coats the bone ends in a synovial joint is also known as hyaline cartilage (see p.43). If sudden knocks or vibrations jolt the joint, this cartilage works as a shock absorber to dissipate the force of the impact and prevent jarring damage to the much more rigid bones. In certain joints, the cartilage has especially tough fibres. Examples include the fibrocartilaginous pads, called intervertebral discs, that act as cushions between the vertebrae of the backbone. Fibrocartilage also occurs in the jaw and wrist joints and the menisci in the knee.

### SPINAL CARTILAGE

The fibrocartilage discs (blue) between the vertebrae help to stabilize and cushion the spinal column.





### INTERIOR OF THE KNEE

The meeting of the femur and tibia forms the body's largest joint (articulation), the knee.

#### Cruciate ligaments

Form a cross shape from back to front of joint to provide stability

#### Meniscus

One of the two wedges of cartilage that help to distribute weight across knee joint

#### Muscle

#### Nerve

#### Patellar tendon

Crosses over patella, which is embedded in it

#### Femur

Bone of the upper leg; also called the thighbone

#### Synovial membrane

Produces synovial fluid

#### Patella

Protective disc of bone and cartilage, also called the kneecap

#### Pad of fat

Acts as cushion between patella and knee, especially when kneeling

#### Articular cartilage

#### Artery

#### Ligament

#### Vein

#### Attachment of patellar tendon to tibia

#### Tibia

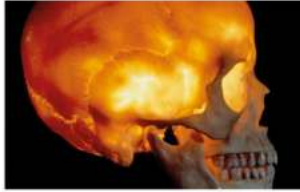Also called the shinbone; larger of the two lower leg bones

### INSIDE THE KNEE

The knee is stabilized by external ligaments and tendons, and can "lock" straight to save energy and maintain posture while standing. It also has internal cartilages (menisci) and internal ligaments (cruciates).

# SKULL

THERE ARE 29 BONES IN THE SKULL – 22 BONES FORM THE SKULL ITSELF, WITH 21 OF THEM, EXCLUDING THE LOWER JAW, FUSED TOGETHER. THE OTHER BONES ARE THE HYOID BONE IN THE NECK AND THREE PAIRS OF TINY EAR BONES, CALLED OSSICLES.



## SKULL SUTURES

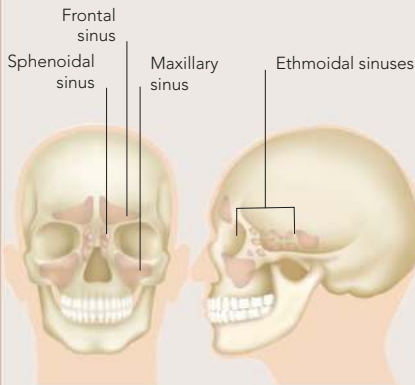
Lines on the skull's surface, highlighted here, are the fused margins of the skull bones.

## SKULL

Two groups of bones make up the skull. The upper set of eight bones forms the dome-like cranium (cranial skull or cranial vault), which encloses and protects the brain. The other 14 bones make the skeleton of the face. During growth in childhood, 21 of the 22 bones become strongly fused at faint joint lines, known as sutures. The lower jaw, or mandible, remains unfixed and is linked to the rest of the skull at the two jaw, or temporomandibular, joints.

## SINUSES

The four pairs of sinuses, known as paranasal sinuses, are air-filled cavities within the skull bones. They are named after the bones in which they are located: maxillary, frontal, sphenoidal, and ethmoidal sinuses. The first three pairs have fairly well-defined shapes. The ethmoidal sinuses are more honeycomb-like and variable.

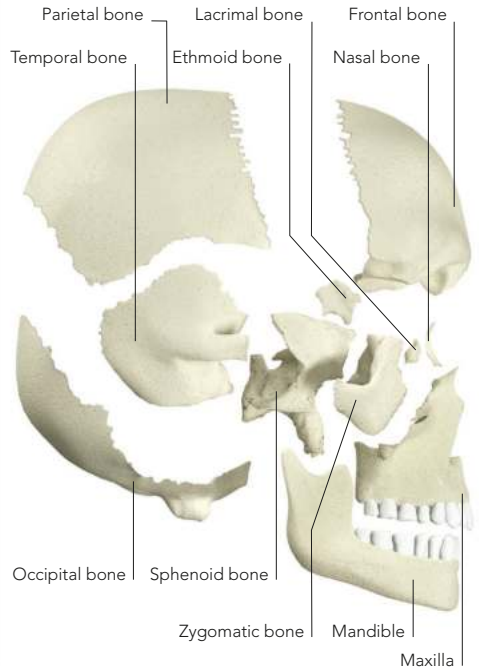


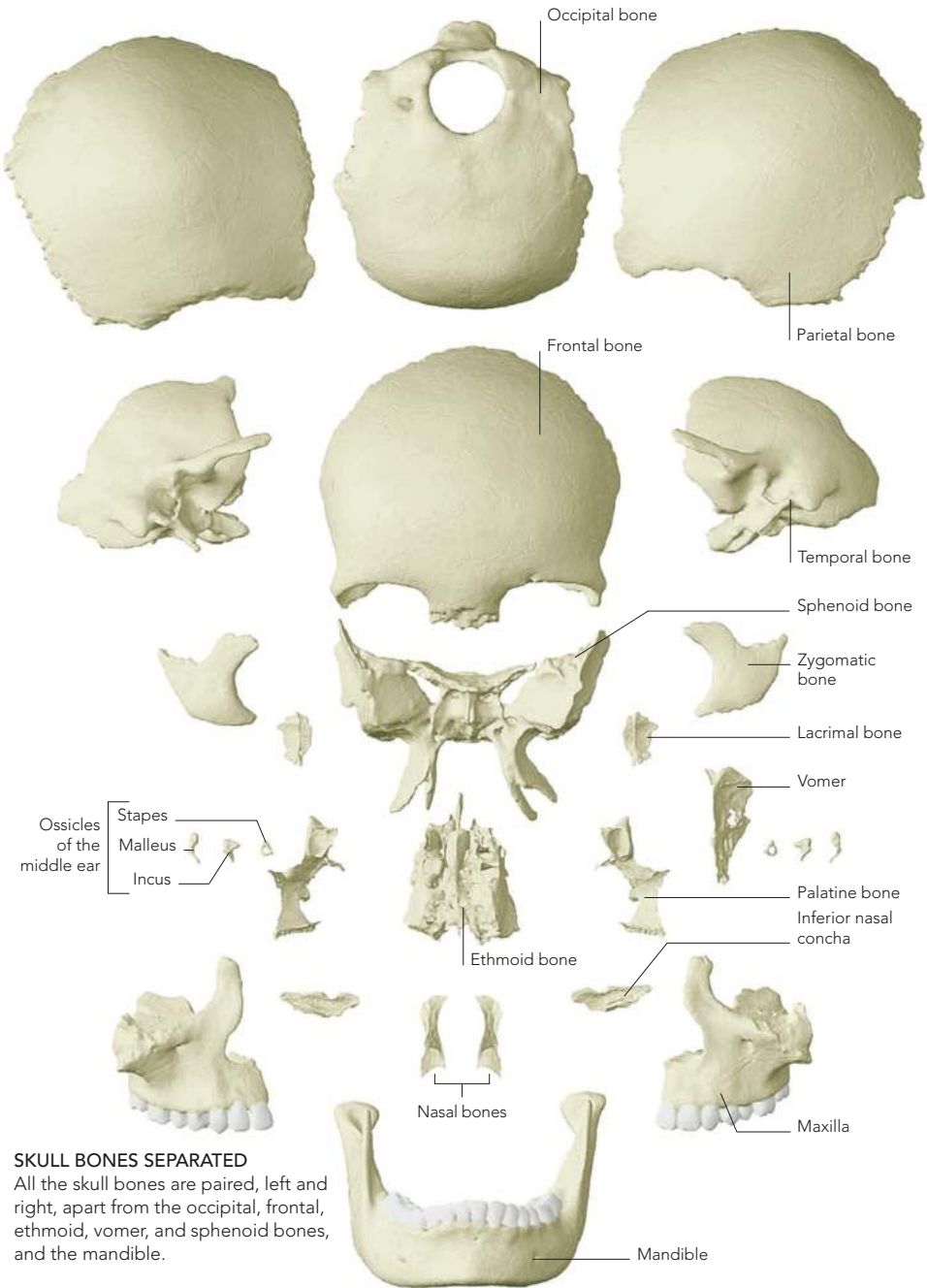
## RESONANT WEIGHT-SAVERS

The sinuses help to lighten the skull's overall weight, and also act as resonating chambers to give each person's voice an individual character.

## SKULL AND HEAD REGIONS

Two sets of bones form the structure of the skull. The eight bones that enclose the brain are called the cranial vault.





**SKULL BONES SEPARATED**

All the skull bones are paired, left and right, apart from the occipital, frontal, ethmoid, vomer, and sphenoid bones, and the mandible.

# SPINE

THE SPINE IS ALSO KNOWN AS THE SPINAL OR VERTEBRAL COLUMN, OR SIMPLY "THE BACKBONE". THIS STRONG YET FLEXIBLE CENTRAL SUPPORT HOLDS THE HEAD AND TORSO UPRIGHT, YET ALLOWS THE NECK AND BACK TO BEND AND TWIST.

## SPINE FUNCTION

The spine consists of 33 ring-like bones called vertebrae. The bottom nine vertebrae are fused into two larger bones termed the sacrum and the coccyx. The 26 movable components of the spine are linked by a series of mobile joints. Between the bones of each joint is an intervertebral disc – a springy pad of tough, fibrous cartilage that squashes slightly under pressure to absorb shocks. Ligaments and muscles around the spine provide stability and help to control movement. The spinal column also protects the spinal cord (see p.98).

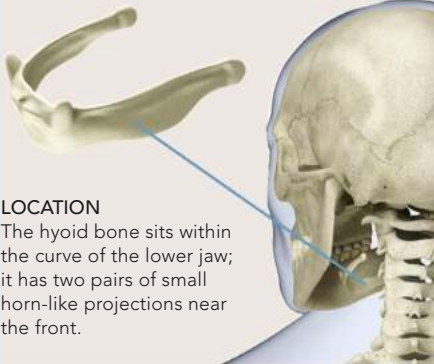
### FLEXIBLE COLUMN

Owing to the shape of the vertebrae, the spine can bend further forward than back, and twist on its axis.



## HYOID BONE

The single U-shaped hyoid bone is located at the root of the tongue, just above the larynx. It is one of the few bones in the body that does not join directly to another bone. It is held in position by muscles and by the strong stylohyoid ligament on each side of the bone, which links to the styloid process of the skull's temporal bone. The hyoid stabilizes several sets of muscles used in swallowing and speech.



### LOCATION

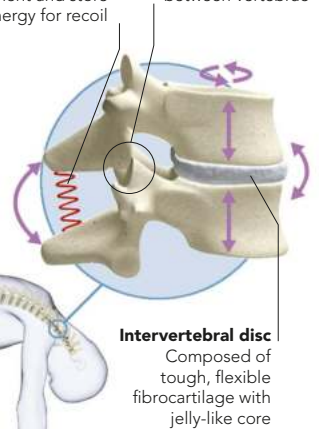
The hyoid bone sits within the curve of the lower jaw; it has two pairs of small horn-like projections near the front.

### Springy ligament

Ligaments between spinous processes limit movement and store energy for recoil

### Facet joint

Determines range of movement between vertebrae

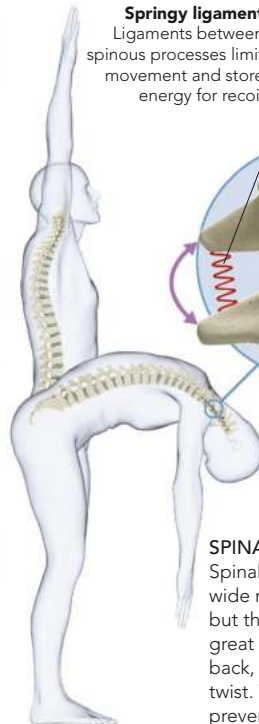

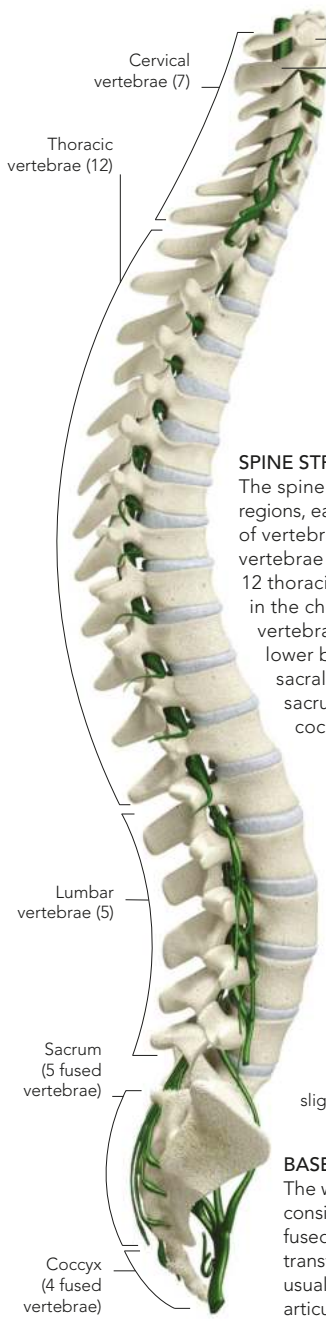
### Intervertebral disc

Composed of tough, flexible fibrocartilage with jelly-like core

### SPINAL JOINTS

Spinal joints do not have a wide range of movement, but they still allow the spine great flexibility, letting it arch back, curve forward, and twist. Two facet joints help to prevent slippage and torsion.





Atlas  
Axis

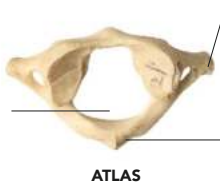**Vertebral foramen**  
Opening through which the spinal cord passes

**Transverse process**  
**Spinous process**  
Anchors muscles and forms "ridges" of spinal column felt under skin

**SPINE STRUCTURE**

The spine has five main regions, each with its own type of vertebrae: seven cervical vertebrae (C1–C7) in the neck; 12 thoracic vertebrae (T1–T12) in the chest; five lumbar vertebrae (L1–L5) in the lower back; five fused sacral vertebrae in the sacrum; and four fused coccygeal vertebrae.

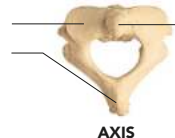
**BASE OF SPINE**  
The wedge-shaped sacrum consists of five vertebrae fused at faint grooves called transverse lines. The coccyx usually has four vertebrae and articulates with the sacrum.



**ATLAS**

**Transverse process**  
Wing-like structure that attaches to muscles

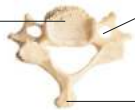**Posterior tubercle**



**AXIS**

**Dens**  
Peg-like projection forming pivot joint with atlas

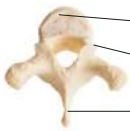**Body**



**CERVICAL VERTEBRA**

**Transverse foramen**  
Carries vertebral artery to brain

**Spinous process**

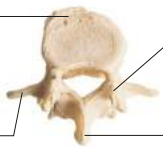

**THORACIC VERTEBRA**

**Body**  
**Hollow for rib**

**Spinous process**

**Body**  
Much enlarged to support extra weight



**LUMBAR VERTEBRA**

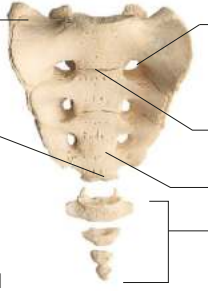
**Articular process**  
Slots into vertebra above

**Spinous process**

**Transverse process**

**Sacral ala (wing)**

**Facet for coccyx**  
Allows coccyx to move slightly in relation to sacrum



**SACRUM AND COCCYX**

**Sacral foramen**  
Allows passage of nerves through sacrum

**Transverse line**

**Sacrum**

**Coccyx**

# RIBS AND PELVIS

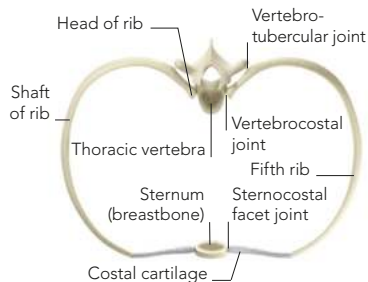
THE RIBS AND HIPBONE (PELVIS) GUARD VITAL CHEST AND ABDOMINAL ORGANS, AND DEMONSTRATE THE SKELETON'S FUNCTIONS OF SUPPORT AND PROTECTION. THE PELVIS PROVIDES SURFACES FOR ANCHORING THE HIP AND THIGH MUSCLES.

## RIBCAGE

Most people have 12 pairs of ribs, but about 1 in 200 is born with one or more extra pairs. All ribs attach to the spinal column at the rear. The upper seven pairs of "true ribs" link directly to the breastbone (sternum) by their cartilage extensions (costal cartilages). The next two or three pairs of "false ribs" connect to the cartilages of the ribs above. The remaining "floating ribs" do not link to the sternum.

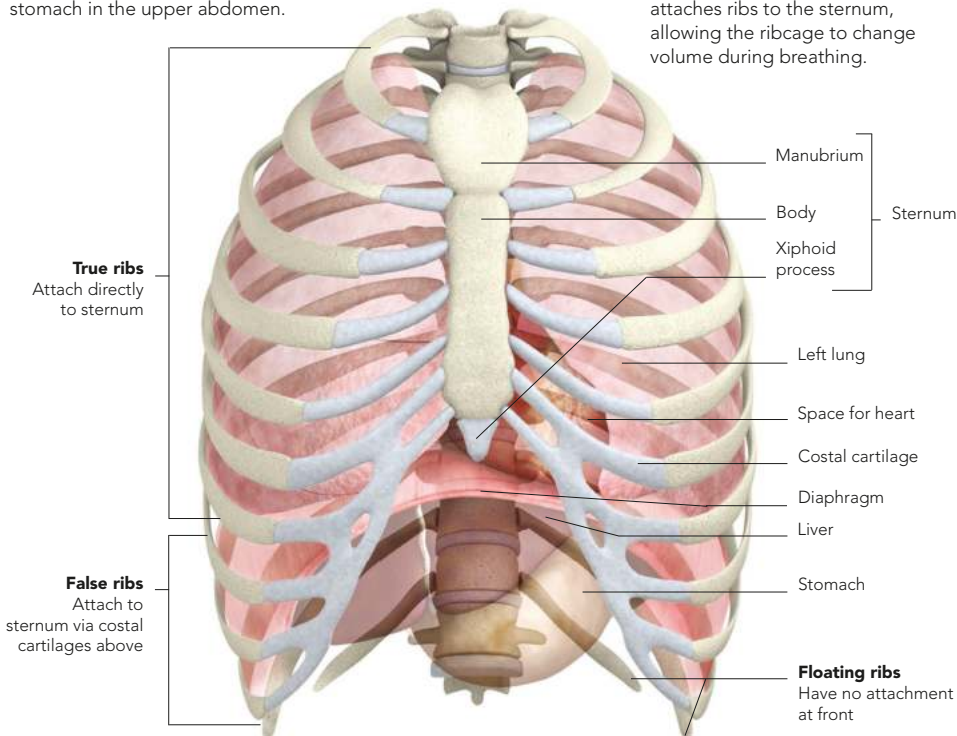
## SHIELDING VITAL ORGANS

The ribs, thoracic spine at the rear, and breastbone (sternum) at the front shield vital internal organs such as the heart and lungs in the chest, and the liver and stomach in the upper abdomen.



## ENCIRCLING RIBCAGE

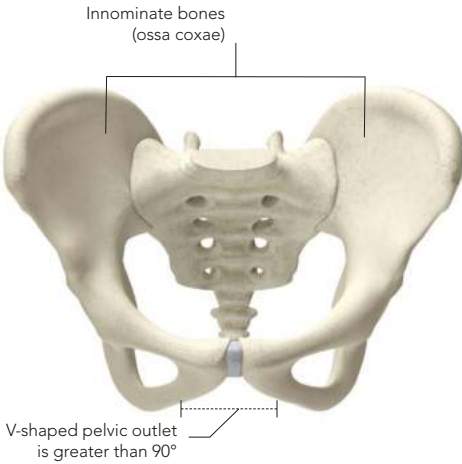
Each rib links to its corresponding chest (thoracic) vertebra at two points. Flexible costal cartilage attaches ribs to the sternum, allowing the ribcage to change volume during breathing.



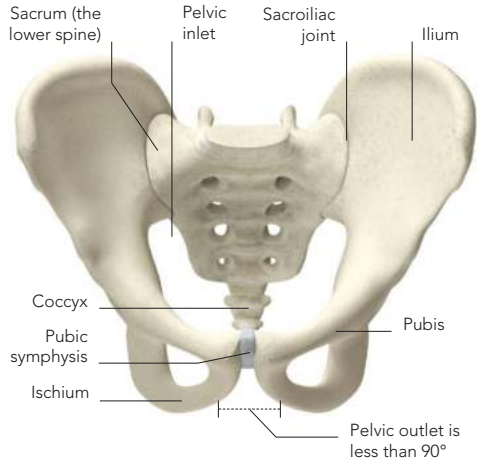
## PELVIS

Often referred to as the hipbone, the pelvis is a bowl-like structure consisting of the left and right innominate bones or ossa coxae, and the wedge-shaped sacrum and coccyx, which make up the “tailbone” at the rear. Each innominate bone has three fused bony elements: the large, flaring ilium at the rear, which forms the hipbone you can feel under the skin;

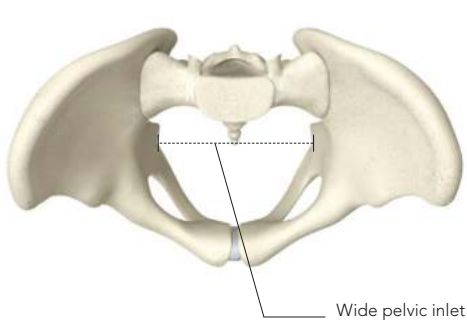
the ischium at the lower front; and the pubis above it. There are paired sacroiliac joints at the rear and the pubic symphysis, a semi-movable joint made of fibrocartilage, at the front. The shape of the pelvis is shallower and wider in females than in males, with a larger gap, or pelvic inlet, and a greater pelvic outlet, to allow a baby to pass through at birth.



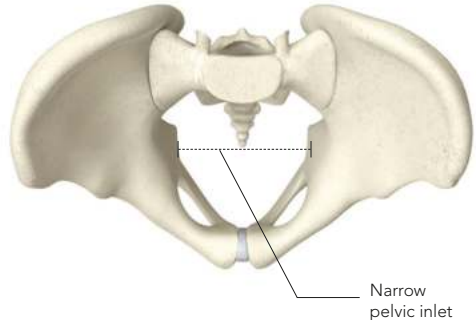
**FEMALE PELVIS FRONT**



**MALE PELVIS FRONT**



**FEMALE PELVIS TOP**



**MALE PELVIS TOP**

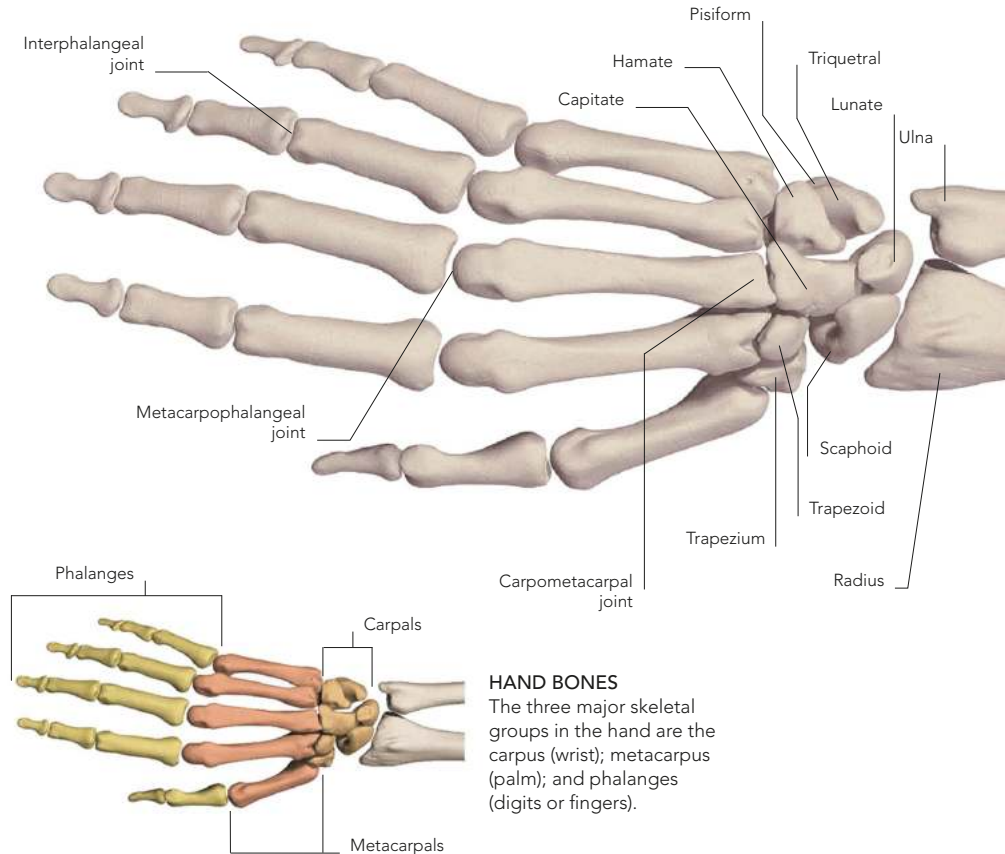
# HANDS AND FEET

THE WRISTS, HANDS, ANKLES, AND FEET COLLECTIVELY CONTAIN 106 BONES, WHICH IS MORE THAN HALF OF ALL THE 206 BONES IN THE BODY. TOGETHER WITH THEIR ASSOCIATED MUSCLES, THEY ARE VITAL FOR COORDINATED MOVEMENT.

## WRIST AND HAND

The wrist is made up of the eight carpal bones, arranged roughly in two rows of four. They are linked to each other chiefly by plane or gliding joints (see p.44), and to the forearm bones by the radiocarpal joint. The palm of the hand contains five metacarpal bones. Each of these joins at

its outer end to a finger bone (phalanx), of which there are two in the thumb (first digit, or pollex) and three each in the other four digits. The entire structure is moved by more than 50 muscles, including some in the forearm, to provide great flexibility and delicate manipulation.

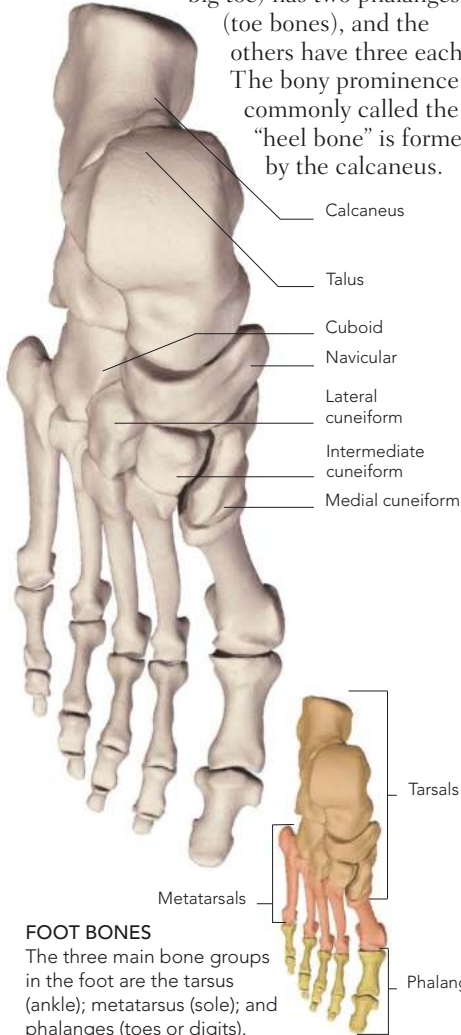




## ANKLE AND FOOT

The ankle and foot have a similar bone arrangement to the wrist and hand, except that there are only seven tarsal (ankle) bones. The build of the ankle and foot bones is heavier, for strength and weight-bearing stability. The sole is supported by the five metatarsal bones. The hallux (first digit or big toe) has two phalanges

(toe bones), and the others have three each. The bony prominence commonly called the "heel bone" is formed by the calcaneus.

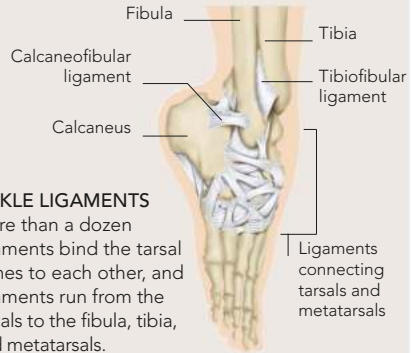


### FOOT BONES

The three main bone groups in the foot are the tarsus (ankle); metatarsus (sole); and phalanges (toes or digits).

## LIGAMENTS

Ligaments are strong bands or straps of fibrous tissue that provide support to the bones and link bone ends together in and around joints. Ligaments are made of collagen – a tough, elastic protein. A large number of ligaments bind together the complex wrist and ankle joints. Each ligament is named after the bones it links; for example, the calcaneofibular ligament links the calcaneus ("heel bone") and the fibula.



### ANKLE LIGAMENTS

More than a dozen ligaments bind the tarsal bones to each other, and ligaments run from the tarsals to the fibula, tibia, and metatarsals.

## WALKING PRESSURE

With each step, the weight of the body moves from the rear to the front of the foot. The heel bears the initial pressure as the foot is put down. The force passes along the arch, which transfers energy and pressure to the ball of the foot, and finally to the big toe for the push-off.



### LOAD AREAS ON THE FOOT

These footprint impressions show (from left to right) how the body's weight transfers from the heel to the ball to the big toe when walking.

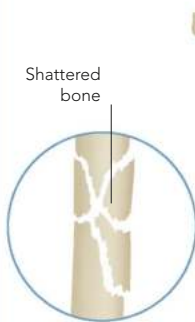
# BONE AND JOINT DISORDERS

BONES AND JOINTS ARE VULNERABLE TO INJURIES SUCH AS FRACTURES AND, DUE TO CONSTANT WEAR, TO DISORDERS SUCH AS OSTEOARTHRITIS. BONES MAY BE WEAKENED BY OSTEOPOROSIS, AND JOINTS MAY BE AFFECTED BY INFLAMMATORY CONDITIONS SUCH AS RHEUMATOID ARTHRITIS.

## FRACTURE

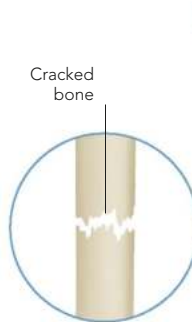
Fractures may be caused by a sudden impact, by compression, or by repeated stress. A displaced fracture occurs when the broken surfaces of bone are forced from their normal positions. There are various types of displaced fracture, depending on the angle and strength of the blow. A compression fracture occurs when spongy bone, such as in the vertebrae, is crushed. Stress fractures are caused by prolonged or repeated force straining the bone; they occur in long-distance runners and in the elderly, in whom minor stress, such as

coughing, may cause a fracture. Nutritional deficiencies or certain chronic diseases such as osteoporosis, which can weaken bone, may increase the likelihood of fractures. If a broken bone remains beneath the skin, the fracture is described as closed or simple, and there is a low risk of infection. If the ends of the fractured bone project out through the skin, the injury is described as open or compound, and there is a danger of dirt entering the bone tissue and causing microbial contamination.



### COMMINUTED FRACTURE

A direct impact can shatter a bone into several fragments or pieces. This type of fracture is likely to occur during a road traffic accident.

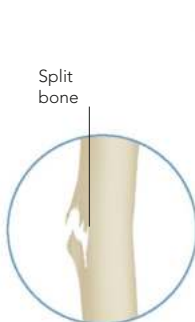


### TRANSVERSE FRACTURE

A powerful force may cause a break across the bone width. The injury is usually stable; the broken surfaces are unlikely to move.

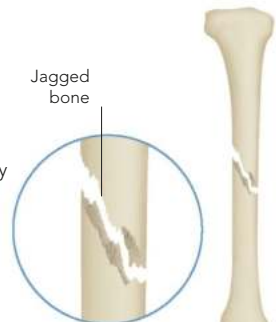
### GREENSTICK FRACTURE

If a long bone bends under force, a crack may occur on one side. This type of fracture is common in children, whose bones are flexible.



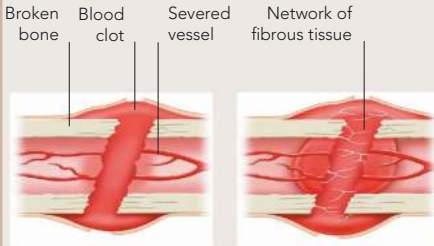
### SPIRAL FRACTURE

A sharp, twisting force may break a bone diagonally across the shaft. The jagged ends may be difficult to reposition.



## BONE REPAIR

Despite its image as dry, brittle, and even lifeless, bone is an active tissue with an extensive blood supply and its own restorative processes. After a fracture, blood clots as it does elsewhere in the body. Fibrous tissue, and then new bone growth, bridge the break and eventually restore strength. However, medical treatment is often required to ensure that the repair process is effective and the result is not misshapen. If the bones are displaced, manipulation to restore their normal position – known as reduction – may be performed under anaesthesia. The bone will also be immobilized to allow the ends to heal correctly.

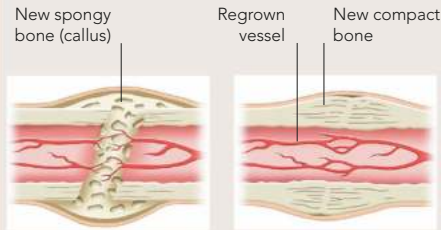


### IMMEDIATE RESPONSE

Blood leaks from the blood vessels and clots. White blood cells gather at the area to scavenge damaged cells and debris.

### AFTER SEVERAL DAYS

Fibroblast cells construct new fibrous tissue across the break. The limb is immobilized, usually in a plaster cast or splint.



### AFTER 1–2 WEEKS

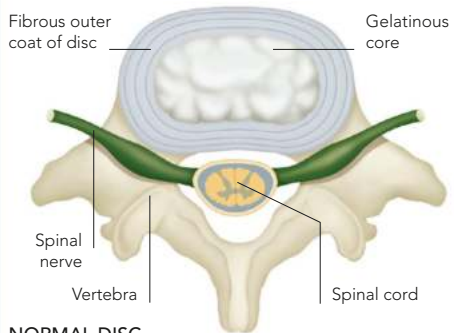
Bone-building cells (osteoblasts) multiply and form new bone tissue. Initially spongy, the new tissue infiltrates the site of the fracture as a callus.

### AFTER 2–3 MONTHS

Blood vessels reconnect across the fracture. The callus reshapes while the new bone tissue is “remodelled” into dense, compact bone.

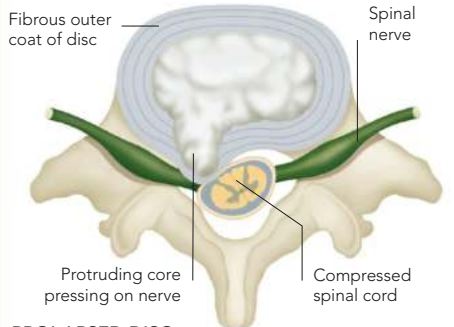
## DISC PROLAPSE

The cushion-like cartilage discs that separate adjacent vertebrae have a hard outer covering and a jelly-like centre. An accident, wear and tear, or excessive pressure when lifting awkwardly, may rupture the outer layer. This forces some of the core material to bulge out, or prolapse. The prolapsed (or herniated) portion may cause pressure on the nearby spinal nerve root. Symptoms of disc prolapse include dull pain, muscle spasm and stiffness in the affected area of the back, and pain, tingling, numbness, or weakness in the body part supplied by the nerve.



### NORMAL DISC

The outer casing (capsule) of the intervertebral disc is intact and encloses its gelatinous core. The disc sits between the bodies (centra) of adjacent vertebrae.



### PROLAPSED DISC

A weak site in the outer casing allows the gelatinous core to bulge through as the disc is compressed. The resulting pressure on the spinal nerve causes pain.

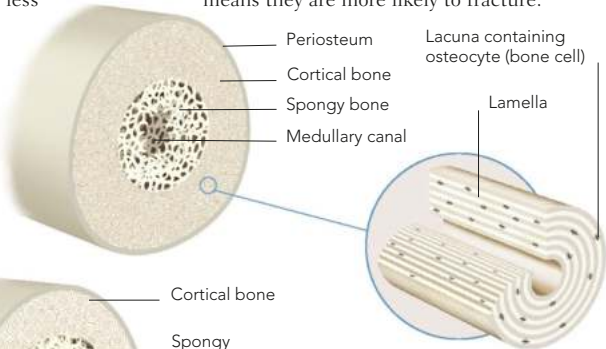
# OSTEOPOROSIS

For bones to stay healthy, bone tissue is continually being broken down and replaced. Sex hormones are essential for this process. With the decline in production of sex hormones in both sexes after middle age, bones become thinner and more porous. Oestrogen levels fall rapidly in women after the menopause, which can lead to severe thinning, or osteoporosis. The decline in testosterone in men is gradual and, in general, males are less

prone to osteoporosis. Exercise is essential for maintaining bone health, and a lack of activity is a predisposing factor to developing osteoporosis. Other factors influencing the development of osteoporosis include smoking, corticosteroid treatment, rheumatoid arthritis, an overactive thyroid, and long-term kidney failure. The decreased density of osteoporotic bones means they are more likely to fracture.

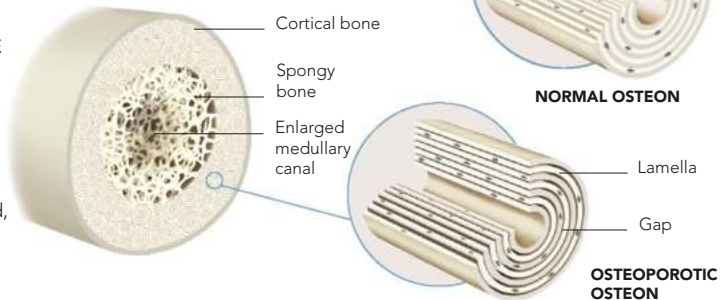
## STRUCTURE OF NORMAL BONE

The outer periosteum encloses a band of hard cortical bone. Within this is a layer of spongy, or cancellous, bone. Hard bone is composed of osteons, which are tightly packed, concentric layers (lamellae) formed by osteocytes.



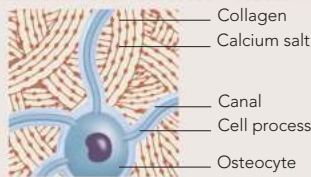
## STRUCTURE OF OSTEOPOROTIC BONE

The mineral density (mainly calcium and phosphorus) is reduced from two-thirds to one-third. The medullary canal through the bone's centre is enlarged, while gaps between the lamellae contribute to the fragility of the bone.



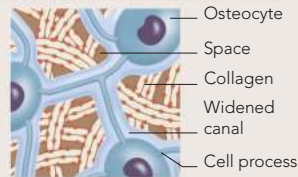
## WHY OSTEOPOROSIS OCCURS

Bone tissue is built up by the deposition of minerals (mainly calcium salts) on a framework of collagen fibres. It is continually broken down and rebuilt in order to allow growth and repair. Osteoporosis develops when the rate at which fibres, minerals, and cells are broken down becomes much greater than the formation of new tissue.



### NORMAL BONE

Osteocytes form collagen fibres and aid calcium deposition. Calcium moves in canals between bone and blood in response to hormones.



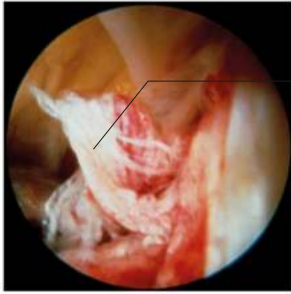### OSTEOPOROTIC BONE

In osteoporosis, collagen and minerals are broken down faster than they form. Canals widen, new spaces appear, and bone weakens.

## LIGAMENT INJURIES

Ligaments are strong, flexible bands of fibrous tissue that link bone ends together around a joint. If the bones in a joint are pulled too far apart, often as a result of a sudden or forceful movement, the ligament fibres may overstretch or tear. This commonly results in swelling, pain, and muscle spasm. A joint “sprain” is usually due to partial tearing of a ligament. Rest, ice,

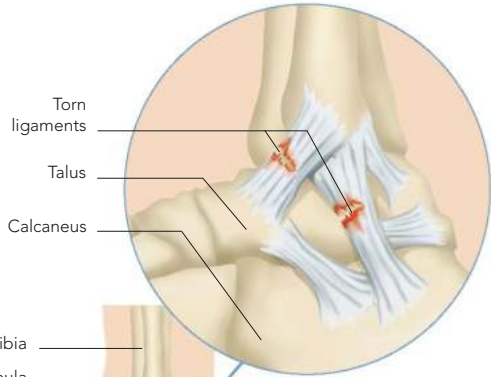
compression, and elevation of the joint is the usual treatment if a sprain is not serious. A severe injury may result in joint instability or dislocation.



Anterior cruciate ligament

### LIGAMENT FIBRES

This view through an arthroscope (a telescope-like tube for seeing into joints) reveals torn fibres of a knee’s anterior cruciate ligament.



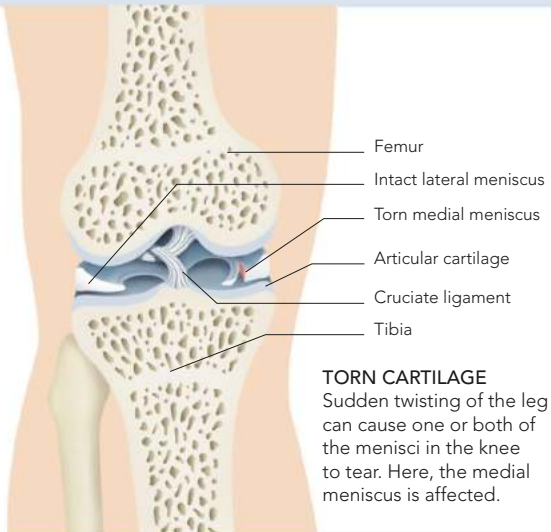
Tibia  
Fibula  
Navicular

### SPRAINED ANKLE

The ligaments in the ankle may be sprained if a fall forces the weight of the body on to the outer edge of the foot.

## TORN CARTILAGE

The knee joint contains pad-like, curved “discs” of cartilage called menisci. These are almost C-shaped and made of tough fibrous cartilage. The discs are situated between the lower end of the femur and upper end of the tibia, with the medial meniscus on the knee’s inner side and the lateral meniscus on the outside. These discs stabilize the joint, helping it to “lock” straight while standing, and cushion the bones. A meniscus may be crushed or torn by rapid twisting of the knee, often while playing sport. If such an injury is painful, surgery can remove the damaged piece of cartilage.



Femur  
Intact lateral meniscus  
Torn medial meniscus  
Articular cartilage  
Cruciate ligament  
Tibia

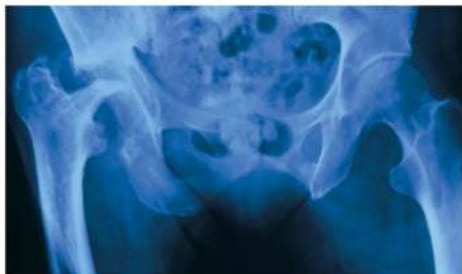### TORN CARTILAGE

Sudden twisting of the leg can cause one or both of the menisci in the knee to tear. Here, the medial meniscus is affected.

# OSTEOARTHRITIS

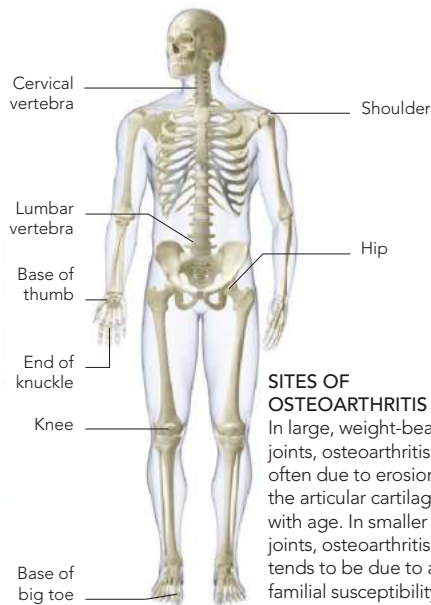
Osteoarthritis is often confused with rheumatoid arthritis (see opposite), but the two disorders have different causes and progressions. Osteoarthritis may affect only a single joint and can be triggered by localized wear and tear, resulting in painful inflammation from time to time. Joint degeneration may be hastened by a congenital defect, injury, infection, or obesity. Because cartilage normally wears away as the body ages, a mild form of osteoarthritis affects many people after about the age of 60 years. Typical symptoms of osteoarthritis include pain and swelling in the affected joint that worsen with activity and fade with rest; joint

stiffness for a short time after rest; restricted movement of the joint; crepitus (crackling noises) when moving the joint; and referred pain (pain in areas remote from the site of damage but on the same nerve pathway as the affected joint).



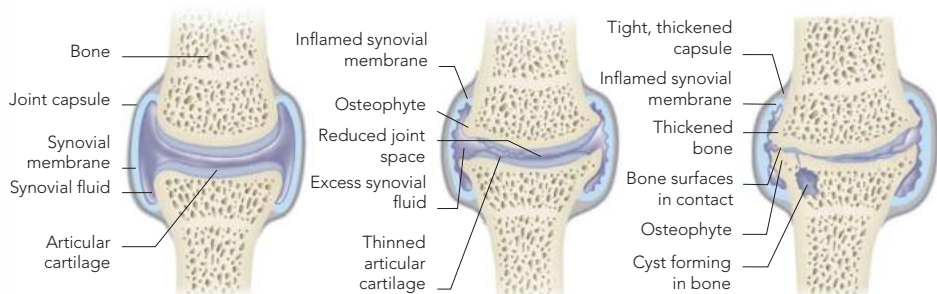
## OSTEOARTHRITIS OF THE HIP

The right hip, on the left of this X-ray, is badly eroded by osteoarthritis. The head of the femur, which is normally round, is flattened.



## SITES OF OSTEOARTHRITIS

In large, weight-bearing joints, osteoarthritis is often due to erosion of the articular cartilage with age. In smaller joints, osteoarthritis tends to be due to a familial susceptibility.



### HEALTHY JOINT

The articular cartilages coating the ends of the bones are smooth and compressible. They are lubricated by synovial fluid and slip past each other with minimal friction.

### EARLY OSTEOARTHRITIS

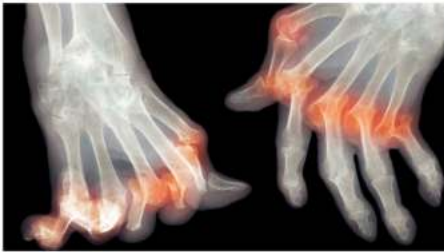The articular cartilage becomes thin and rough, with fissures in its surface. Bony outgrowths (osteophytes) form, and the synovial lining is inflamed, producing excess fluid.

### LATE OSTEOARTHRITIS

The articular cartilage and underlying bone crack and erode. The bones rub together, thicken, and overgrow, causing extreme discomfort. The joint capsule thickens.

## RHEUMATOID ARTHRITIS

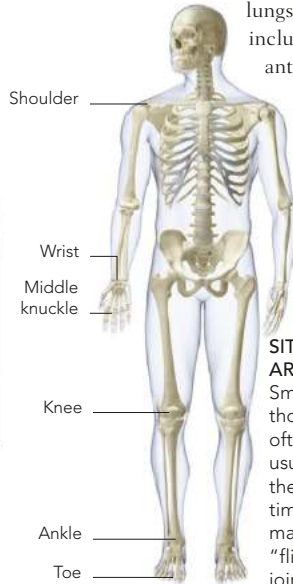Rheumatoid arthritis develops when the immune system produces antibodies that attack its own body tissues – especially the synovial membranes inside joints. The joints become swollen and deformed, with painful and restricted movement. Early general symptoms include fever, fatigue, and weakness. Characteristically, many of the small joints are affected in a symmetrical pattern; for example, the hands and feet may become inflamed to the same degree on both sides. Stiffness is often worse in the mornings but eases during the day. Painless small lumps or nodules (clusters of inflamed tissue cells), may form in areas of pressure, commonly on



### JOINT INFLAMMATION

In this X-ray, the middle knuckles of the hands are severely damaged by rheumatoid arthritis (red). Inflammation of the joints causes abnormal bending of the fingers.

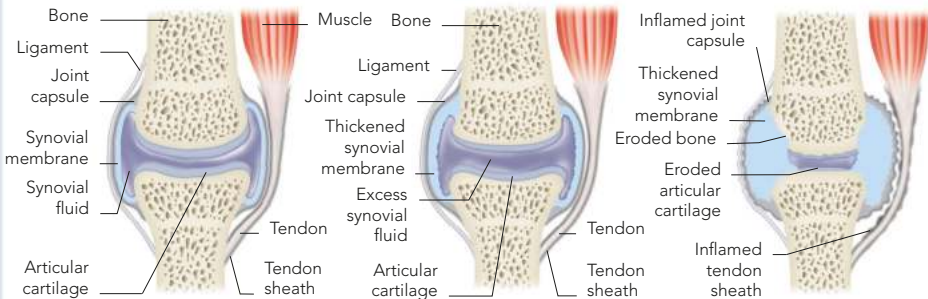
the forearms, and the skin over the joint is thin and fragile. The condition may flare up, then fade for a time. The diagnosis is supported if a blood test detects certain antibodies – RF and anti-CCP – associated with rheumatoid arthritis. The disease can also affect the eyes, skin, heart, nerves, and



lungs. Treatment includes simple anti-inflammatory drugs and disease-modifying antirheumatic drugs (DMARDs).

### SITES OF RHEUMATOID ARTHRITIS

Smaller joints, especially those in the hands, are often affected first, usually on both sides of the body at the same time. The inflammation may then transfer or “flit” to other, larger joints, such as the wrist.



### HEALTHY JOINT

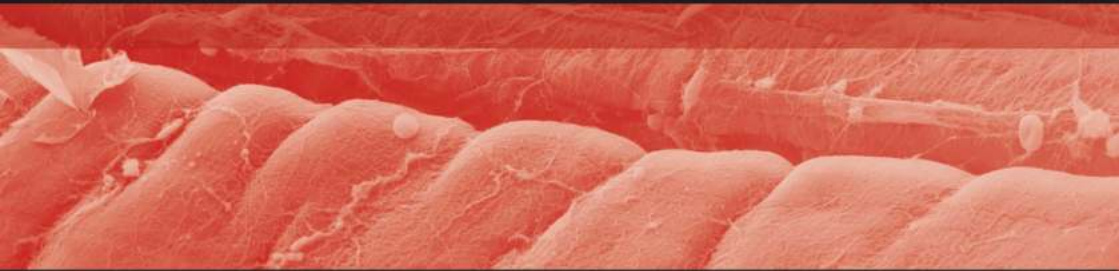
Cartilage is smooth and intact in a healthy joint. Ligaments aid stability, and tendons slide in sheaths as muscles pull on them.

### EARLY RHEUMATOID ARTHRITIS

The synovial membrane becomes inflamed and thickens, spreading across the joint. Excess synovial fluid accumulates in the joint.

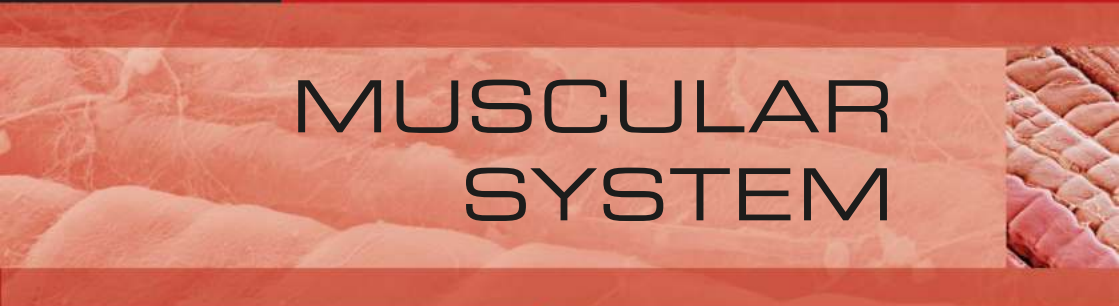
### LATE RHEUMATOID ARTHRITIS

As the synovial membrane thickens, the cartilage and bone ends are eroded. The joint capsule and tendon sheath become inflamed.



THE MUSCULAR SYSTEM PRODUCES AN ENDLESS VARIETY OF ACTIONS BY USING MUSCLES IN COORDINATED TEAMS. MUSCLE TISSUE CREATES BODILY MOVEMENTS AND ALSO POWERS INTERNAL PROCESSES, FROM THE HEARTBEAT AND THE MOVEMENT OF FOOD THROUGH THE INTESTINES TO THE ADJUSTMENT OF ARTERY DIAMETER AND THE FOCUSING OF THE EYE. HOWEVER, MUSCLES CANNOT FUNCTION WITHOUT THE NERVOUS SYSTEM TO STIMULATE THEIR ACTIVITIES. THE MUSCULAR SYSTEM IS MORE PRONE TO INJURY THAN TO DISEASE.



A horizontal band with a light orange background containing a microscopic image of muscle tissue. The image shows several muscle fibers with visible striations and nuclei. The band is framed by solid red bars above and below it.

# MUSCULAR SYSTEM

# MUSCLES OF THE BODY

THE MUSCLES ARE RESPONSIBLE FOR MOVEMENT. THEY ACHIEVE THIS BY CONTRACTING AND PULLING ON THE BONES TO WHICH THEY ARE ATTACHED.

The typical male body contains approximately 640 muscles, which compose around two-fifths of its total weight. The same number in a female body make up a slightly smaller proportion. A typical muscle spans a joint and tapers at each end into a fibrous tendon anchored to a bone. Some muscles divide to attach to different bones. Superficial muscles, those located just beneath the skin, are pictured here on the left side of a male body. On the right side of this body are the deeper layers – the intermediate and deep muscles.

**Zygomaticus major**  
Raises corners of mouth

**Occipitofrontalis**  
Raises eyebrows

**Orbicularis oculi**  
Closes eye

**Orbicularis oris**  
Narrows mouth and purses lips

**Scalenus**  
Aids breathing and neck flexion

**Sternocleidomastoid**  
Tilts and twists neck

**Trapezius**  
Rotates and retracts shoulder blade

**Pectoralis minor**  
Moves shoulder blade

**Deltoid**  
Raises arm away from body to front, side, and rear

**Pectoralis major**  
Draws arm towards body; rotates upper arm inward

**Biceps brachii**  
Flexes forearm at elbow and turns the palm upward

**Rectus abdominis**  
Flexes spine and draws pelvis forward

**External oblique abdominal**  
Flexes and rotates trunk

**Brachioradialis**  
Flexes arm at elbow

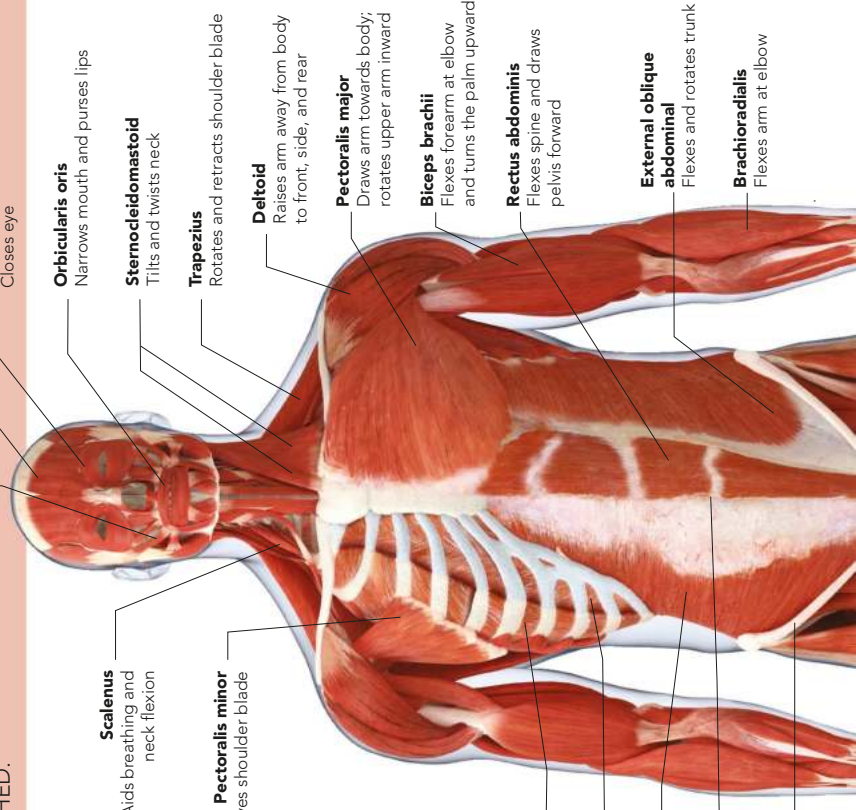
**External intercostal**  
Elevates ribs

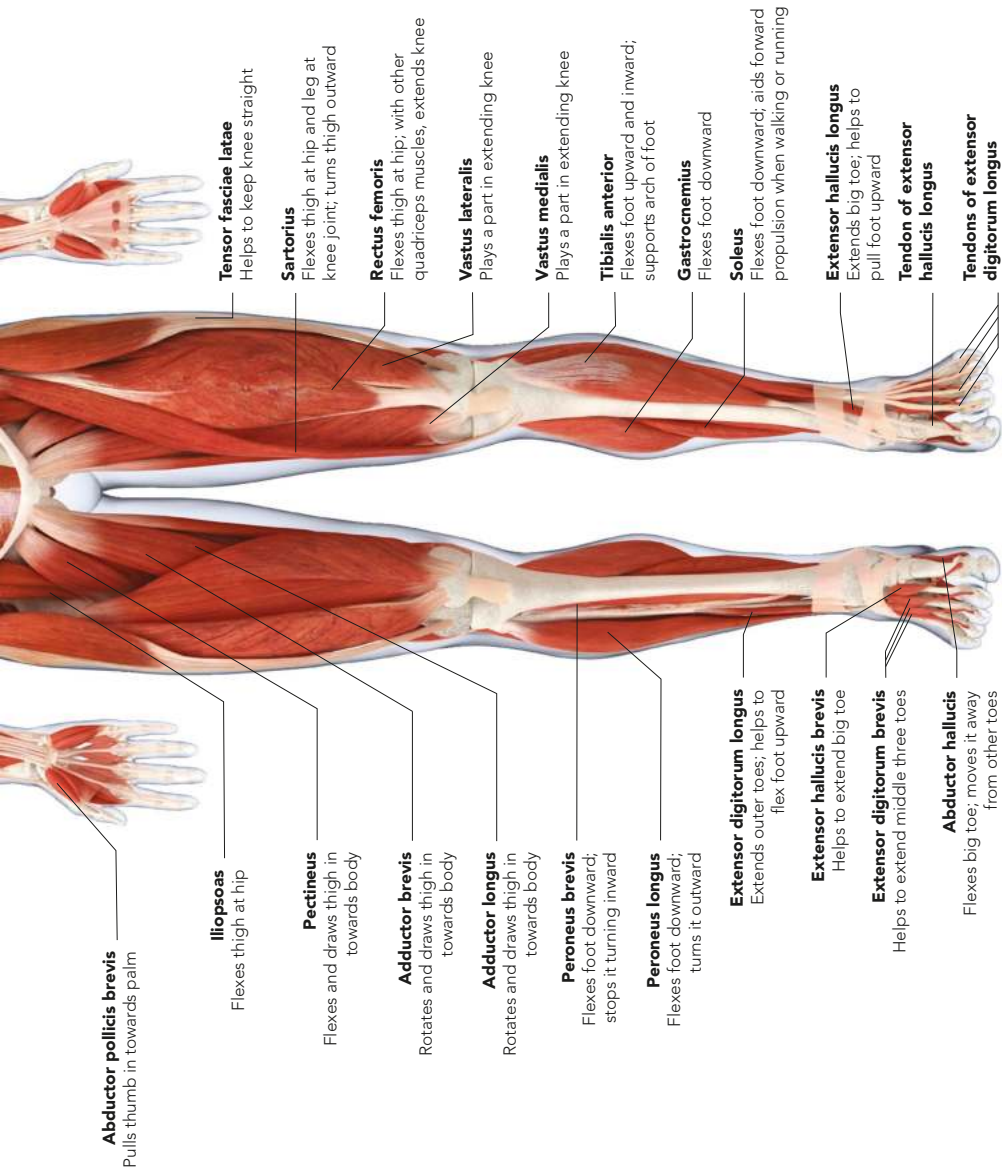
**Internal intercostal**  
Pulls adjacent ribs together

**Internal oblique abdominal**  
Flexes and rotates trunk

**Linea alba**  
Tendinous structure dividing left and right abdominal muscles

**Inguinal ligament**





**Abductor pollicis brevis**  
Pulls thumb in towards palm

**Iliopsoas**  
Flexes thigh at hip

**Pectineus**  
Flexes and draws thigh in towards body

**Adductor brevis**  
Rotates and draws thigh in towards body

**Adductor longus**  
Rotates and draws thigh in towards body

**Peroneus brevis**  
Flexes foot downward; stops it turning inward

**Peroneus longus**  
Flexes foot downward; turns it outward

**Extensor digitorum longus**  
Extends outer toes; helps to flex foot upward

**Extensor hallucis brevis**  
Helps to extend big toe

**Extensor digitorum brevis**  
Helps to extend middle three toes

**Abductor hallucis**  
Flexes big toe; moves it away from other toes

**Tensor fasciae latae**  
Helps to keep knee straight

**Sartorius**  
Flexes thigh at hip and leg at knee joint; turns thigh outward

**Rectus femoris**  
Flexes thigh at hip; with other quadriceps muscles, extends knee

**Vastus lateralis**  
Plays a part in extending knee

**Vastus medialis**  
Plays a part in extending knee

**Tibialis anterior**  
Flexes foot upward and inward; supports arch of foot

**Gastrocnemius**  
Flexes foot downward

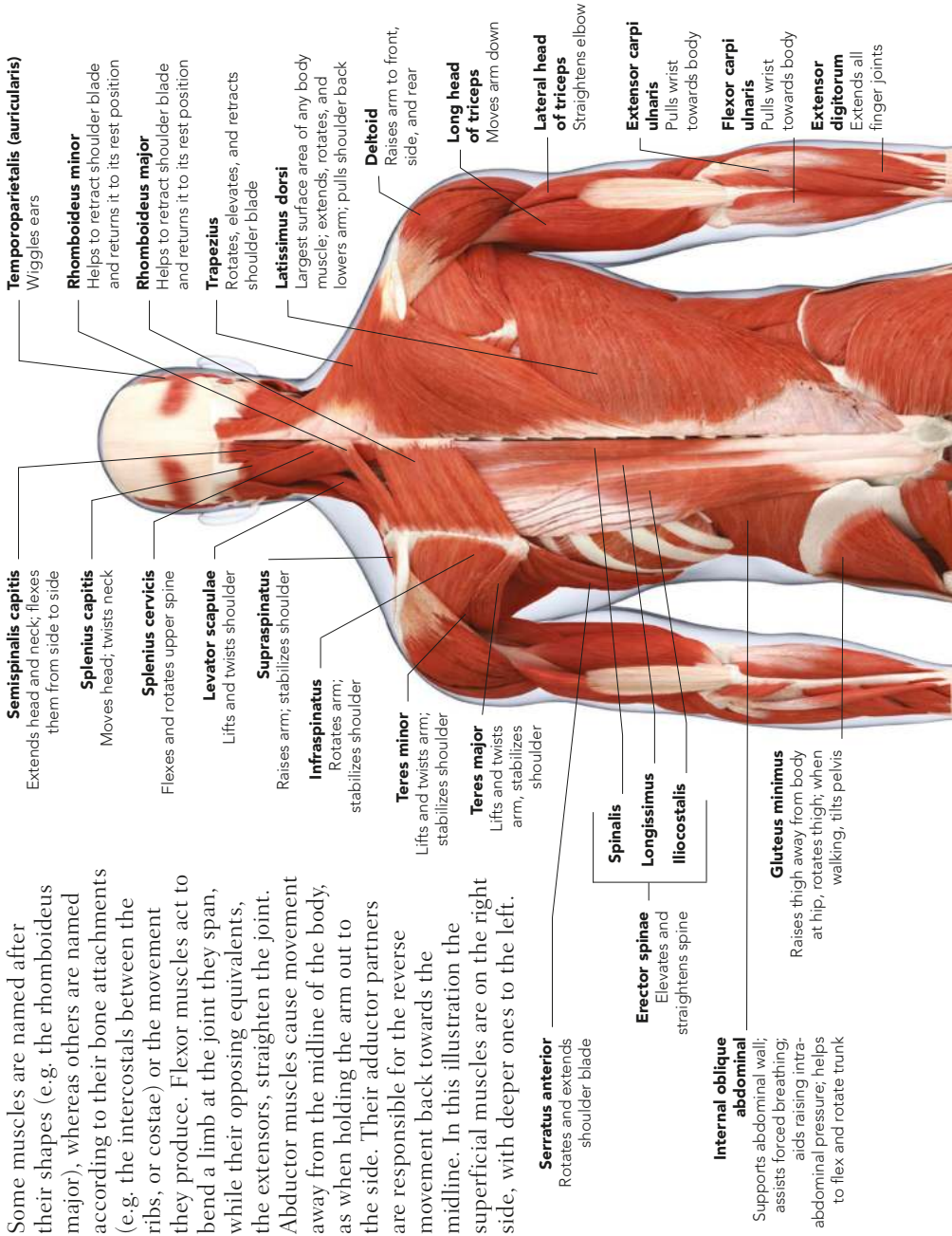
**Soleus**  
Flexes foot downward; aids forward propulsion when walking or running

**Extensor hallucis longus**  
Extends big toe; helps to pull foot upward

**Tendon of extensor hallucis longus**

**Tendons of extensor digitorum longus**

Some muscles are named after their shapes (e.g. the rhomboideus major), whereas others are named according to their bone attachments (e.g. the intercostals between the ribs, or costae) or the movement they produce. Flexor muscles act to bend a limb at the joint they span, while their opposing equivalents, the extensors, straighten the joint. Abductor muscles cause movement away from the midline of the body, as when holding the arm out to the side. Their adductor partners are responsible for the reverse movement back towards the midline. In this illustration the superficial muscles are on the right side, with deeper ones to the left.




## MUSCLE TISSUE

There are three main types of muscle tissue. What we usually think of as “muscles” are skeletal muscles. Also called voluntary or striated muscles, most skeletal muscles are joined to bones and produce bodily movements under conscious control. Smooth muscles; also called involuntary muscles as they are not under conscious control, occur in the walls of body parts such as the airways and blood vessels. Cardiac muscle forms the walls of the heart.

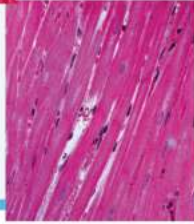
### SKELETAL

A microscope view shows pronounced stripes, bands, or striations, created by the alignment of muscle fibrils.



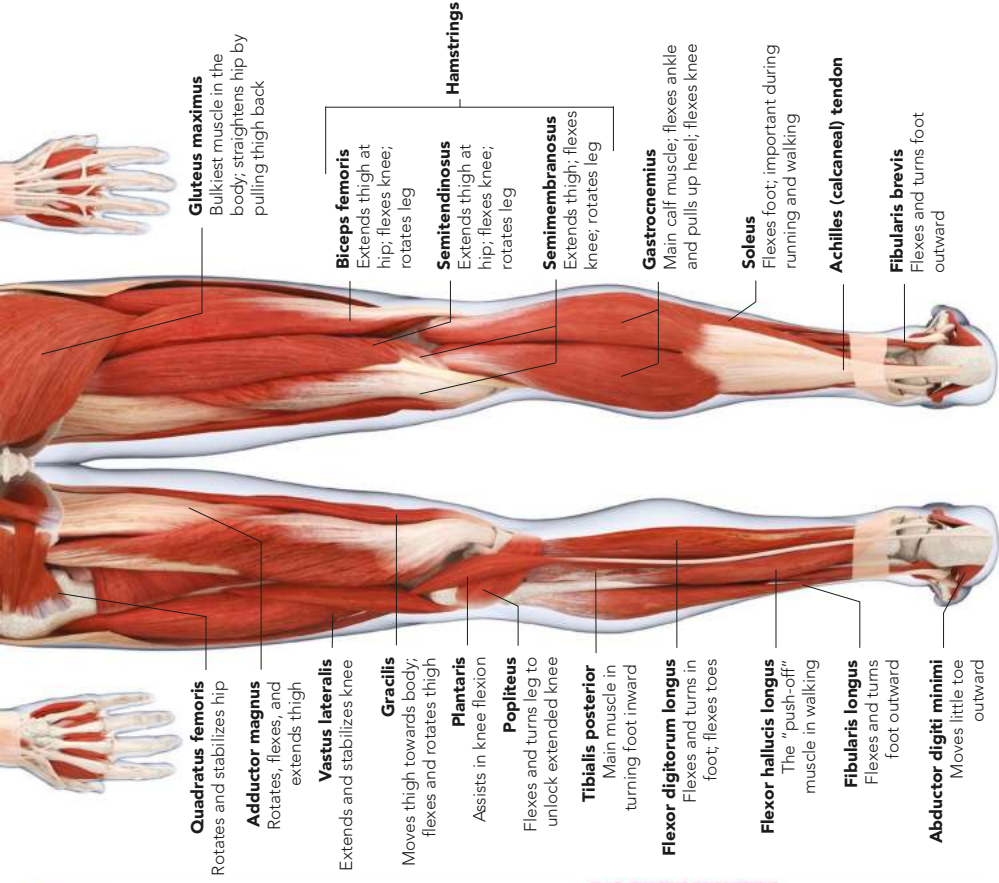
### SMOOTH

The light microscope reveals few features: principally tapered muscle cells with dark nuclei.



### CARDIAC

Fibres in heart (cardiac) muscle are short and branching, often Y- or V-shaped, with faint banding or striations.



#### **Quadratus femoris**

Rotates and stabilizes hip

#### **Adductor magnus**

Rotates, flexes, and extends thigh

#### **Vastus lateralis**

Extends and stabilizes knee

#### **Gracilis**

Moves thigh towards body; flexes and rotates thigh

#### **Plantaris**

Assists in knee flexion

#### **Popliteus**

Flexes and turns leg to unlock extended knee

#### **Tibialis posterior**

Main muscle in turning foot inward

#### **Flexor digitorum longus**

Flexes and turns in foot; flexes toes

#### **Flexor hallucis longus**

The “push-off” muscle in walking

#### **Fibularis longus**

Flexes and turns foot outward

#### **Abductor digiti minimi**

Moves little toe outward

#### **Gluteus maximus**

Bulkiest muscle in the body; straightens hip by pulling thigh back

#### **Biceps femoris**

Extends thigh at hip; flexes knee; rotates leg

#### **Semitendinosus**

Extends thigh at hip; flexes knee; rotates leg

#### **Semimembranosus**

Extends thigh; flexes knee; rotates leg

#### **Gastrocnemius**

Main calf muscle; flexes ankle and pulls up heel; flexes knee

#### **Soleus**

Flexes foot; important during running and walking

#### **Achilles (calcaneal) tendon**

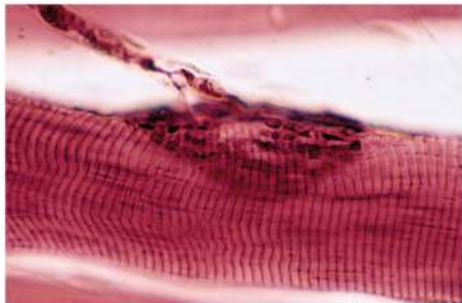
#### **Fibularis brevis**

Flexes and turns foot outward

#### **Hamstrings**

# MUSCLES OF THE FACE, HEAD, AND NECK

THE MUSCLES OF THE FACE, HEAD, AND NECK INTERACT TO STEADY AND MOVE THE HEAD AND TO MOVE THE FACIAL FEATURES. THE MUSCULATURE INVOLVED IS HIGHLY COMPLEX, MAKING POSSIBLE A HUGE RANGE OF FACIAL EXPRESSIONS.

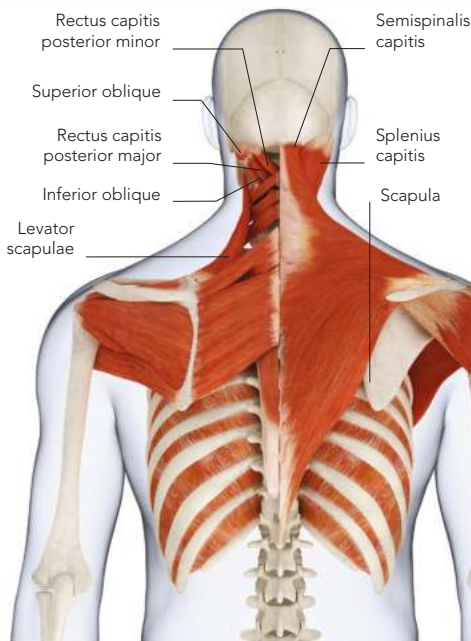


## NERVE-MUSCLE JUNCTION

In this microscope image, a nerve cell (top left) joins a facial muscle fibre. At the point of contact between the two is the motor end plate (centre), an area of highly excitable muscle fibre.

## FACIAL MUSCLES

Some facial muscles are anchored to bones. Others are joined to tendons or to dense, sheet-like clusters of fibrous connective tissue called aponeuroses. This means that some facial muscles are joined to each other. Many of these muscles have their other end inserted into deeper layers of the skin. The advantage of this complex system is that even a slight degree of muscle contraction produces movement of the facial skin, which reveals itself as a show of expression or emotion. Almost all facial muscles are controlled by the facial nerve called cranial VII (see p.102).



## HEAD AND NECK MUSCLES

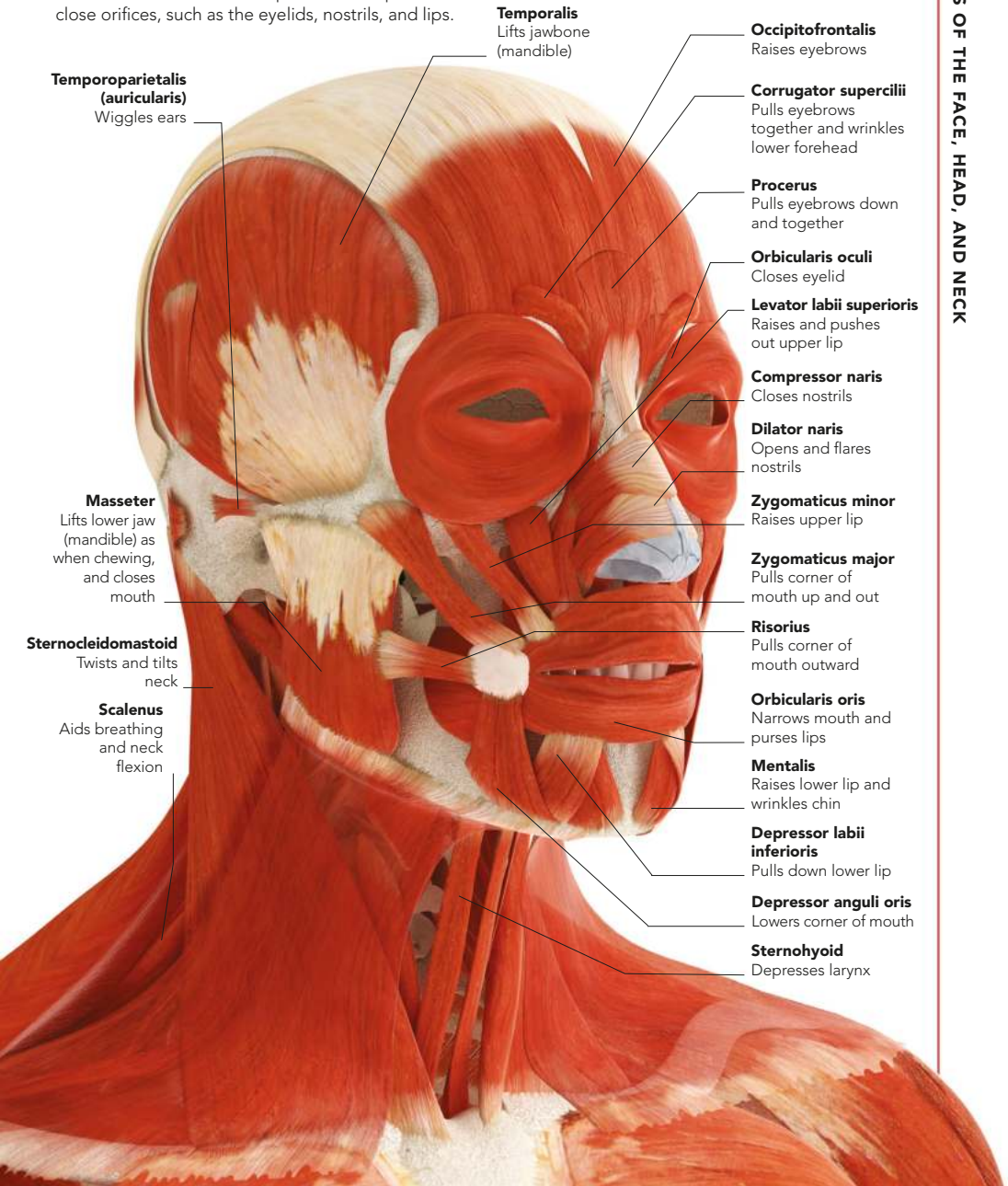
An adult's head weighs more than 5kg (11lb) and is, to some extent, "balanced" on top of the vertebral column. Strong, stabilizing muscles in the neck, inner shoulders, and upper back constantly tense to steady the head and contract in coordinated teams to produce complex movements of the neck. These muscles assist facial expressions and non-verbal communication, such as emphasizing doubt by cocking the head slightly to one side, or moving the head to indicate "yes" or "no".

## BACK MUSCLES

The neck and shoulder muscles support and steady the head. Upper-back muscles that attach to the shoulder blade (scapula) help to stabilize the shoulders.

**FACE AND NECK MUSCLES**

Intermeshing muscles around the lips are involved in speech, non-verbal expression, eating, and drinking. Some facial muscles act as sphincters to open and close orifices, such as the eyelids, nostrils, and lips.



**Temporoparietalis (auricularis)**  
Wiggles ears

**Masseter**  
Lifts lower jaw (mandible) as when chewing, and closes mouth

**Sternocleidomastoid**  
Twists and tilts neck

**Scalenus**  
Aids breathing and neck flexion

**Temporalis**  
Lifts jawbone (mandible)

**Occipitofrontalis**  
Raises eyebrows

**Corrugator supercilii**  
Pulls eyebrows together and wrinkles lower forehead

**Procerus**  
Pulls eyebrows down and together

**Orbicularis oculi**  
Closes eyelid

**Levator labii superioris**  
Raises and pushes out upper lip

**Compressor naris**  
Closes nostrils

**Dilator naris**  
Opens and flares nostrils

**Zygomaticus minor**  
Raises upper lip

**Zygomaticus major**  
Pulls corner of mouth up and out

**Risorius**  
Pulls corner of mouth outward

**Orbicularis oris**  
Narrows mouth and purses lips

**Mentalis**  
Raises lower lip and wrinkles chin

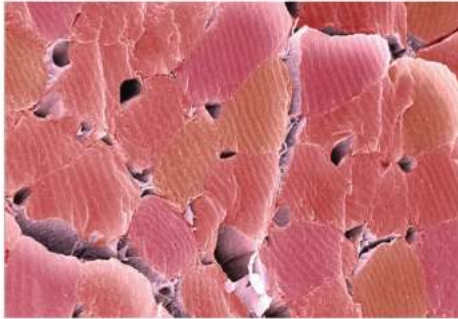**Depressor labii inferioris**  
Pulls down lower lip

**Depressor anguli oris**  
Lowers corner of mouth

**Sternohyoid**  
Depresses larynx

# MUSCLES AND TENDONS

MUSCLES CAN ONLY CONTRACT AND SHORTEN. TO RETURN TO THEIR ORIGINAL SHAPE, THEY RELAX AND LENGTHEN PASSIVELY AS OTHER MUSCLES CONTRACT. THE CONTRACTION OF SKELETAL MUSCLES AND TENDONS PRODUCES BODY MOVEMENTS.



## STRIATED MUSCLE

This electron micrograph shows a cross-section through skeletal muscle. The bundles of myofibers are interspersed with capillaries (dark areas).

### Z band

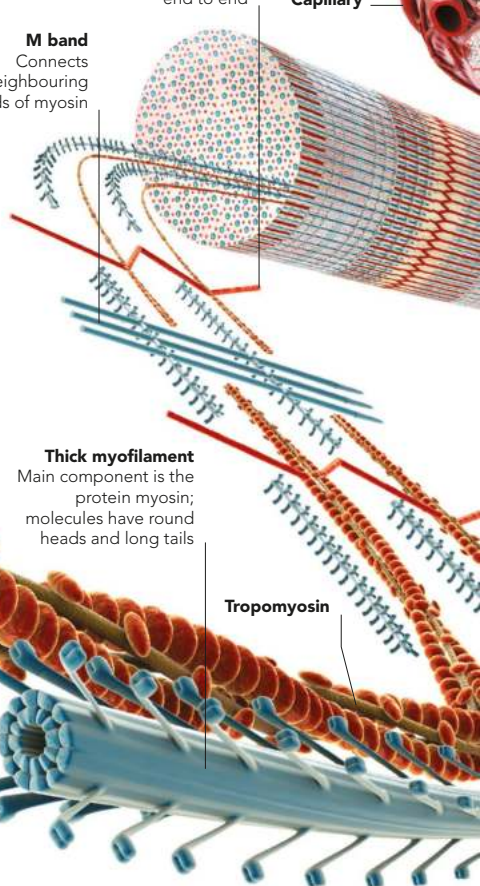
Where the contractile units (sarcomeres) join end to end

Capillary

**M band**  
Connects neighbouring strands of myosin

## MUSCLE STRUCTURE

Skeletal (striated or voluntary) muscle consists of densely packed groups of hugely elongated cells called myofibers. These are grouped into bundles (fascicles). A typical myofibre is 2–3cm ( $\frac{3}{4}$ –1 $\frac{1}{2}$ in) long and 0.05mm ( $\frac{1}{500}$ in) in diameter and is composed of narrower structures called myofibrils. These contain thick and thin myofilaments made up mainly of the proteins actin and myosin. Numerous capillaries keep the muscle supplied with the oxygen and glucose needed to fuel contraction.



### Thick myofilament

Main component is the protein myosin; molecules have round heads and long tails

### Thin myofilament

Consists of twisted strands of actin and tropomyosin (protein that inhibits contraction), plus occasional troponin complexes

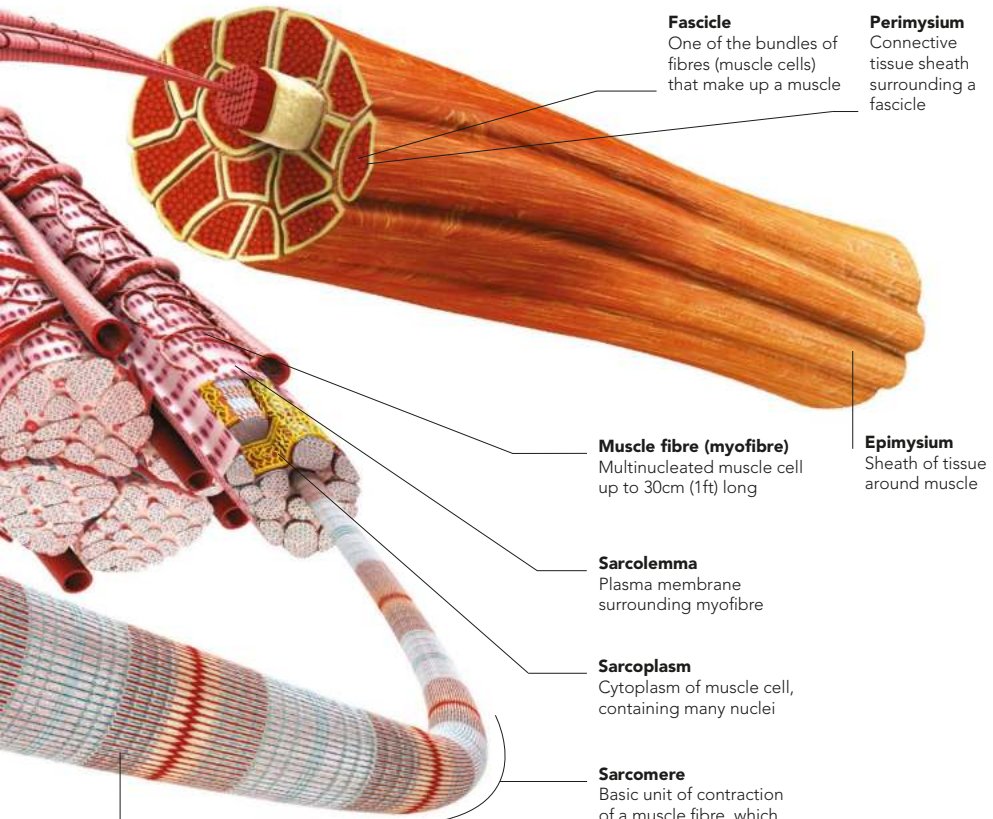
Actin

Tropomyosin

Tail of myosin molecule

Head of myosin molecule





**Fascicle**  
One of the bundles of fibres (muscle cells) that make up a muscle

**Perimysium**  
Connective tissue sheath surrounding a fascicle

**Muscle fibre (myofibre)**  
Multinucleated muscle cell up to 30cm (1ft) long

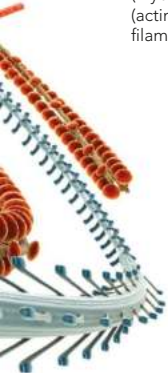**Epimysium**  
Sheath of tissue around muscle

**Sarcolemma**  
Plasma membrane surrounding myofibre

**Sarcoplasm**  
Cytoplasm of muscle cell, containing many nuclei

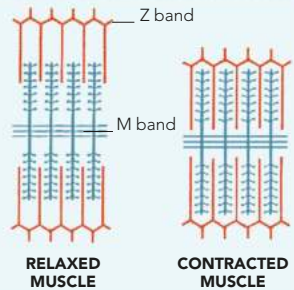
**Sarcomere**  
Basic unit of contraction of a muscle fibre, which extends from one Z band to the next

**Muscle fibril (myofibril)**  
Each muscle fibril is made up of both thick (myosin) and thin (actin) contractile filaments



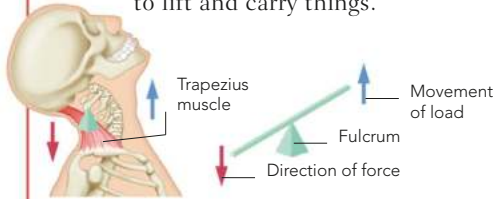
## HOW MUSCLES CONTRACT

In muscle that is relaxed, the myofilaments only partly overlap. When a muscle contracts, the myosin filaments slide in between the actin filaments, shortening the myofibrils and the entire muscle fibre. The more shortened muscle fibres there are, the greater the contraction in the muscle as a whole.



## BODY PARTS AS LEVERS

Body movements employ the mechanical principles of applying a force to one part of a rigid lever, which tilts at a pivot point (fulcrum) to move a weight (load) that is elsewhere on the lever. The muscles apply force, bones serve as levers, and joints function as fulcrums. The various lever systems in the body allow a wide range of movement as well as making it possible to lift and carry things.

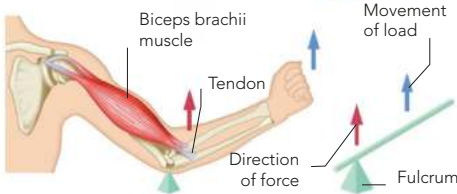
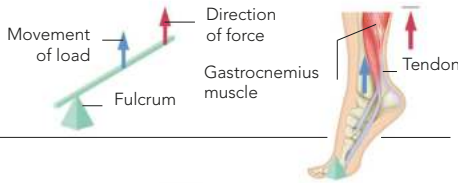


### FIRST-CLASS LEVER

The fulcrum is positioned between the force and the load, like a see-saw. An example of this type of lever in the body is seen in the posterior neck muscles that tilt back the head on the cervical vertebrae.

### SECOND-CLASS LEVER

The load lies between the force and the fulcrum. Standing on tip-toe, the calf muscles provide the force, the heel and foot form the lever, and the toes provide the fulcrum.

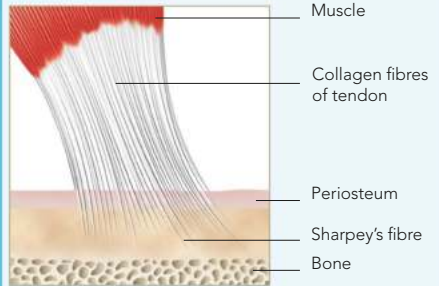


### THIRD-CLASS LEVER

The most common type of lever in the body; the force is applied between the load and the fulcrum. An example is flexing the elbow joint (the fulcrum) by contracting the biceps brachii muscle.

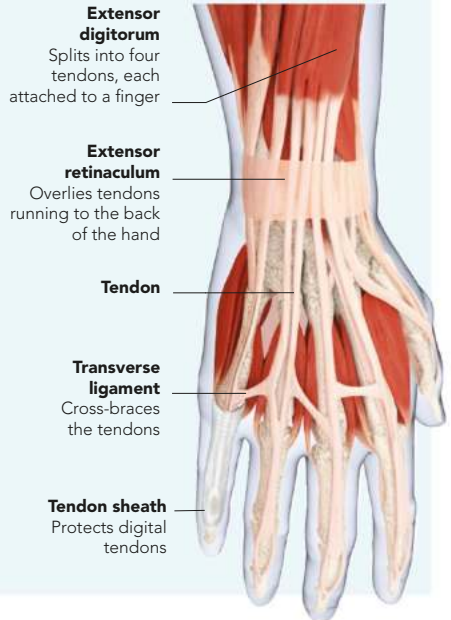
## TENDONS

Tendons are tough, fibrous cords of connective tissue that link skeletal muscles to bones. Within them, Sharpey's fibres pass through the bone covering (periosteum) to embed in the bone. Tendons in the hands and feet are enclosed in self-lubricating sheaths to protect them from rubbing against the bones. From the hand bones, tendons extend up to muscles near the elbow.



### BONE-TENDON ATTACHMENT

Sharpey's fibres, which are also known as perforating fibres, are extensions of the tendon's proteinaceous collagen fibres.

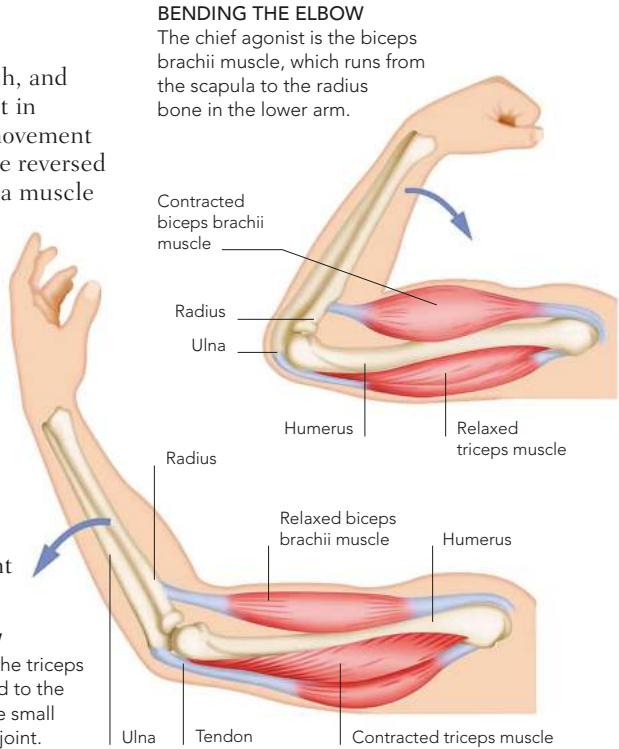


## HOW MUSCLES WORK TOGETHER

Muscles can only pull, not push, and so are arranged in pairs that act in opposition to one other. The movement produced by one muscle can be reversed by its opposing partner. When a muscle contracts to produce movement, it is called the agonist, while its opposite partner, called the antagonist, relaxes and is passively stretched. In reality, few movements are achieved by a single muscle contraction. Usually, whole teams of muscles act as agonists to give the precisely required degree and direction of motion, while the antagonists tense to prevent the movement over-extending.

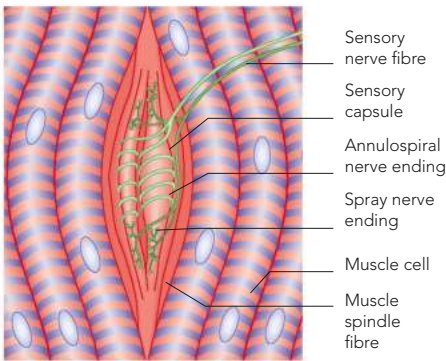
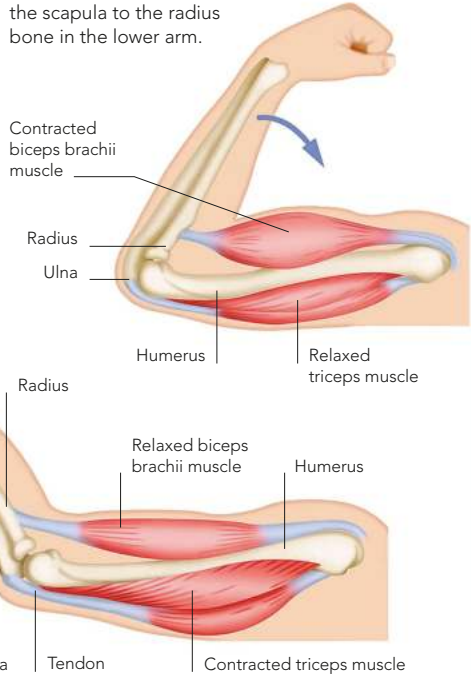
### STRAIGHTENING THE ELBOW

The biceps brachii relaxes and the triceps brachii, attached at its lower end to the ulna, contracts. It is aided by the small anconeus muscle on the elbow joint.



### BENDING THE ELBOW

The chief agonist is the biceps brachii muscle, which runs from the scapula to the radius bone in the lower arm.



### NEUROMUSCULAR SPINDLE

These stretch sensors lie between and in parallel with skeletal muscle fibres; information from them allows the brain to gauge the muscle's tension and elongation.

## POSITIONAL SENSE

Muscles contain many tiny sensors, known as neuromuscular spindles. These are modified muscle fibres with a spindle-shaped sheath or capsule and several types of nerve supply. The sensory or afferent nerve fibres, which are wrapped around the modified muscle fibres, relay information to the spinal cord and brain about muscle length and tension as the muscle stretches. Signals are then sent back through motor neurons to the muscle to tell it to contract, thus restoring muscle tension to normal. Similar receptors are found in ligaments and tendons. Together they provide the body's innate sense of its own position and posture, called proprioception.

# MUSCLE AND TENDON DISORDERS

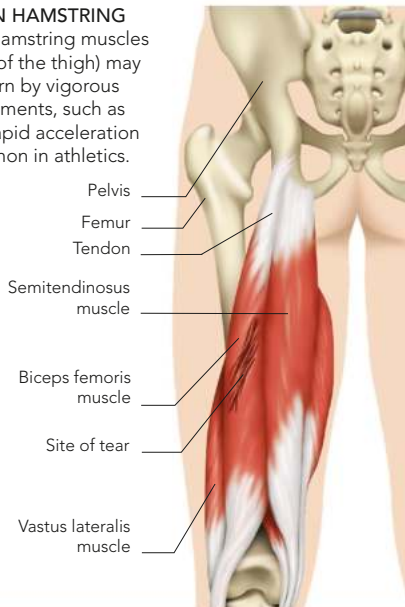
MUSCLES AND TENDONS MAY BE DAMAGED AS A RESULT OF PHYSICAL EXERTION DURING DAILY ACTIVITIES, FROM SUDDEN PULLING OR TWISTING MOVEMENTS SUCH AS THOSE OCCURRING IN SPORT OR AN ACCIDENT, OR FROM REPETITIVE ACTIONS, FOR EXAMPLE, DUE TO EMPLOYMENT.

## MUSCLE STRAINS AND TEARS

Muscle strain is the term used for a moderate amount of soft-tissue damage to muscle fibres, which is usually caused by sudden, strenuous movements. Limited bleeding inside the muscle causes tenderness and swelling, which may be accompanied by painful spasms or contractions. Visible bruising may follow. More serious damage, involving a larger number of torn or ruptured fibres, is called a muscle tear. A torn muscle produces severe pain and swelling. Following a medical check to gauge the severity of the injury, the usual treatment is rest, anti-inflammatory medication, and sometimes physiotherapy. Rarely, surgery may be needed to repair a muscle that has been badly torn.

### TORN HAMSTRING

The hamstring muscles (rear of the thigh) may be torn by vigorous movements, such as the rapid acceleration common in athletics.

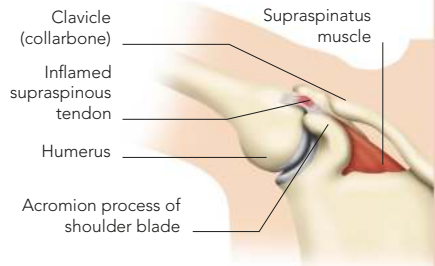


## TENDINITIS AND TENOSYNOVITIS

Tendinitis may occur when strong or repeated movement creates excessive friction between the tendon's outer surface and an adjacent bone. Tenosynovitis may be the result of overstretching or repeated movement causing inflammation of the lubricating sheaths that enclose some tendons. Both of these problems can occur together and may be part of the group of disorders known collectively as repetitive strain injuries (RSIs).

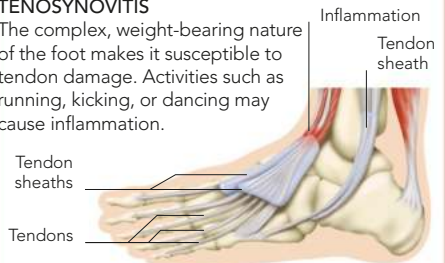### TENDINITIS

Repeated arm-lifting, such as in racquet sports, may force the supraspinatus tendon to rub against the shoulder blade's acromion process, causing tendinitis.



### TENOSYNOVITIS

The complex, weight-bearing nature of the foot makes it susceptible to tendon damage. Activities such as running, kicking, or dancing may cause inflammation.

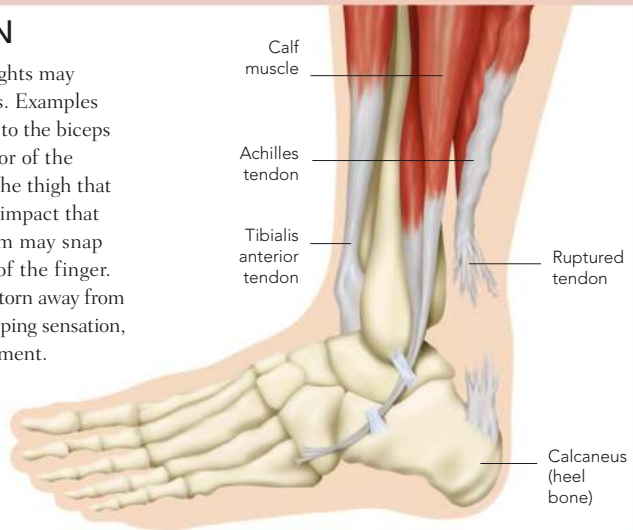


## RUPTURED TENDON

Playing sport and lifting heavy weights may result in torn, or ruptured, tendons. Examples are tearing of the tendons attached to the biceps brachii muscle in the upper arm, or of the quadriceps tendon at the front of the thigh that stretches over the knee. A sudden impact that bends a fingertip towards the palm may snap the extensor tendon on the back of the finger. In severe cases, the tendon may be torn away from the bone. Symptoms include a snapping sensation, pain, swelling, and impaired movement.

### TORN ACHILLES TENDON

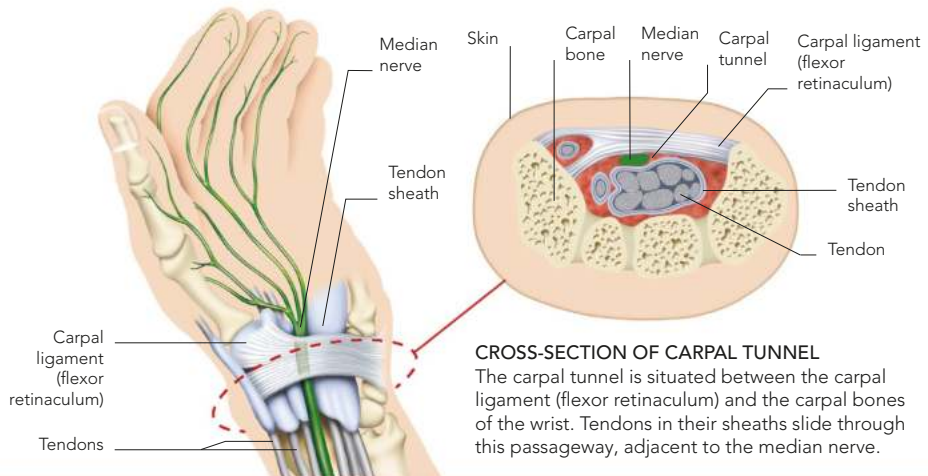
The Achilles tendon attaches the calf muscle to the heel bone. It can snap after sudden exertion and may need to be treated by surgery and immobilization in a cast.



## CARPAL TUNNEL SYNDROME

The carpal tunnel is a narrow passage formed by the carpal ligament (flexor retinaculum), on the inside of the wrist, and the underlying wrist bones (carpals). Tendons run through the tunnel from the forearm muscles to the hand. The median nerve also passes through the carpal tunnel, to

control hand muscles and convey sensations from the fingers. In carpal tunnel syndrome (CTS), the median nerve is compressed by swelling of the tissues around it in the tunnel. Causes include diabetes mellitus, pregnancy, a wrist injury, rheumatoid arthritis, and repetitive movements.



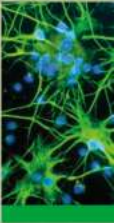### CROSS-SECTION OF CARPAL TUNNEL

The carpal tunnel is situated between the carpal ligament (flexor retinaculum) and the carpal bones of the wrist. Tendons in their sheaths slide through this passageway, adjacent to the median nerve.



IN SOME WAYS, THE HUMAN BRAIN RESEMBLES A COMPUTER. BUT IN ADDITION TO LOGICAL PROCESSING, IT IS CAPABLE OF COMPLEX DEVELOPMENT, LEARNING, SELF-AWARENESS, EMOTION, AND CREATIVITY. EVERY SECOND, MILLIONS OF CHEMICAL AND ELECTRICAL SIGNALS TRAVEL AROUND THE BRAIN AND THE BODY'S INTRICATE NERVE NETWORK. NERVOUS TISSUE IS DELICATE, AND NEEDS PHYSICAL PROTECTION AND A RELIABLE BLOOD SUPPLY. IF NERVES ARE DAMAGED, REPAIR MAY BE PAINSTAKINGLY SLOW OR IMPOSSIBLE.

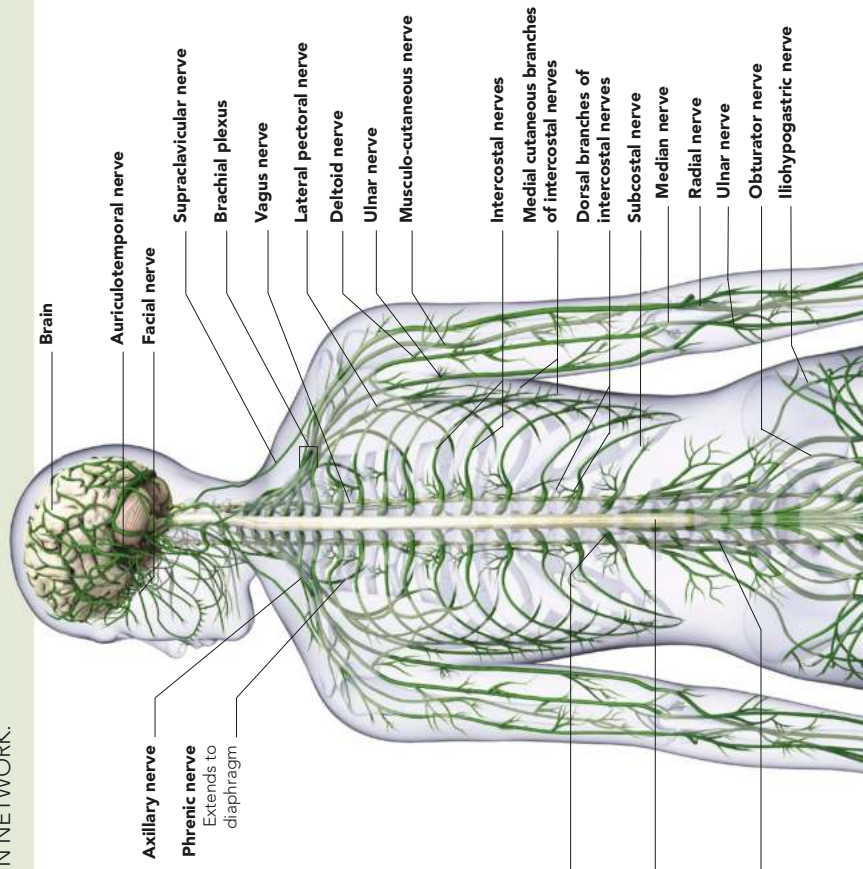
# NERVOUS SYSTEM



# NERVOUS SYSTEM

CONSTANTLY ALIVE WITH ELECTRICITY, THE EXTENSIVE AND COMPLEX NERVOUS SYSTEM IS THE BODY'S PRIME COMMUNICATION AND COORDINATION NETWORK.

The body's nervous system has three parts. The central nervous system, or CNS, is made up of the brain and spinal cord. The peripheral nervous system, or PNS, comprises 12 pairs of nerves from the brain and 31 pairs from the cord. These branching nerves go to each part of the body, relaying information to and from the CNS, which has the roles of coordination and decision-making. The autonomic nervous system, or ANS, has nerve pathways in the CNS and PNS. Its work is primarily "automatic": it deals with activities such as heart rate adjustment and blood pressure control, of which we are rarely aware.



Brain

Auriculotemporal nerve

Facial nerve

Axillary nerve

Phrenic nerve

Extends to diaphragm

Supraclavicular nerve

Brachial plexus

Vagus nerve

Lateral pectoral nerve

Deltoid nerve

Ulnar nerve

Musculo-cutaneous nerve

Intercostal nerves

Medial cutaneous branches of intercostal nerves

Dorsal branches of intercostal nerves

Subcostal nerve

Median nerve

Radial nerve

Ulnar nerve

Obturator nerve

Iliohypogastric nerve

## Spinal ganglion

One of many nodules that send sensory information to brain via spinal cord

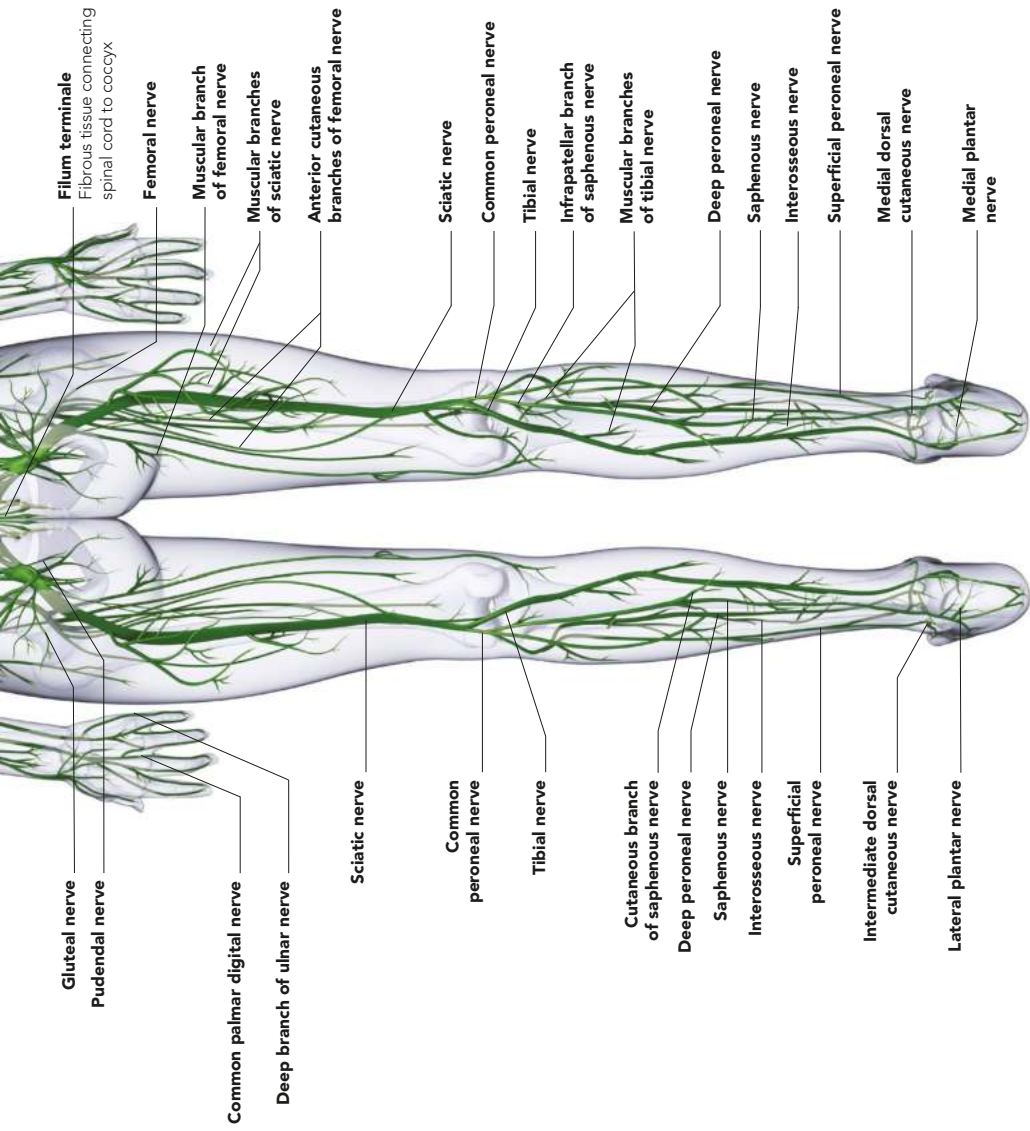
## Spinal cord

Part of central nervous system, extends from brain down the back, protected by vertebral column

## Sympathetic ganglia chain

Part of sympathetic nervous system, also called paravertebral ganglia; conveys stress signals to body





# NERVES AND NEURONS

NERVE CELLS, OR NEURONS, ARE HIGHLY SPECIALIZED IN THEIR STRUCTURE, FUNCTION, AND COMMUNICATION LINKS.

## NEURON STRUCTURE

Like all other cells, a typical neuron has a main cell body with a nucleus. But a neuron also has long, wire-like processes that connect the neuron to others, allowing messages to be passed at junctions called synapses. These processes are of two main kinds. Dendrites receive messages from other neurons, or from nerve-like cells in sense organs, and conduct them towards the cell body of the neuron. The axon conveys messages away from the cell body, to other neurons or to muscle or gland cells. Dendrites tend to be short and have many branches, while axons are usually longer and branch less along their length. Neurons in the brain and spinal cord are protected and nurtured by supporting nerve cells known as glial cells.



### MICROSCOPE VIEW

Nerve cells under the microscope display their cell bodies with nuclei (left) and processes (right).

- Mitochondrion**  
Involved in cell respiration and production of energy
- Nucleus**  
Located towards the middle of the cell body

**Cell body**

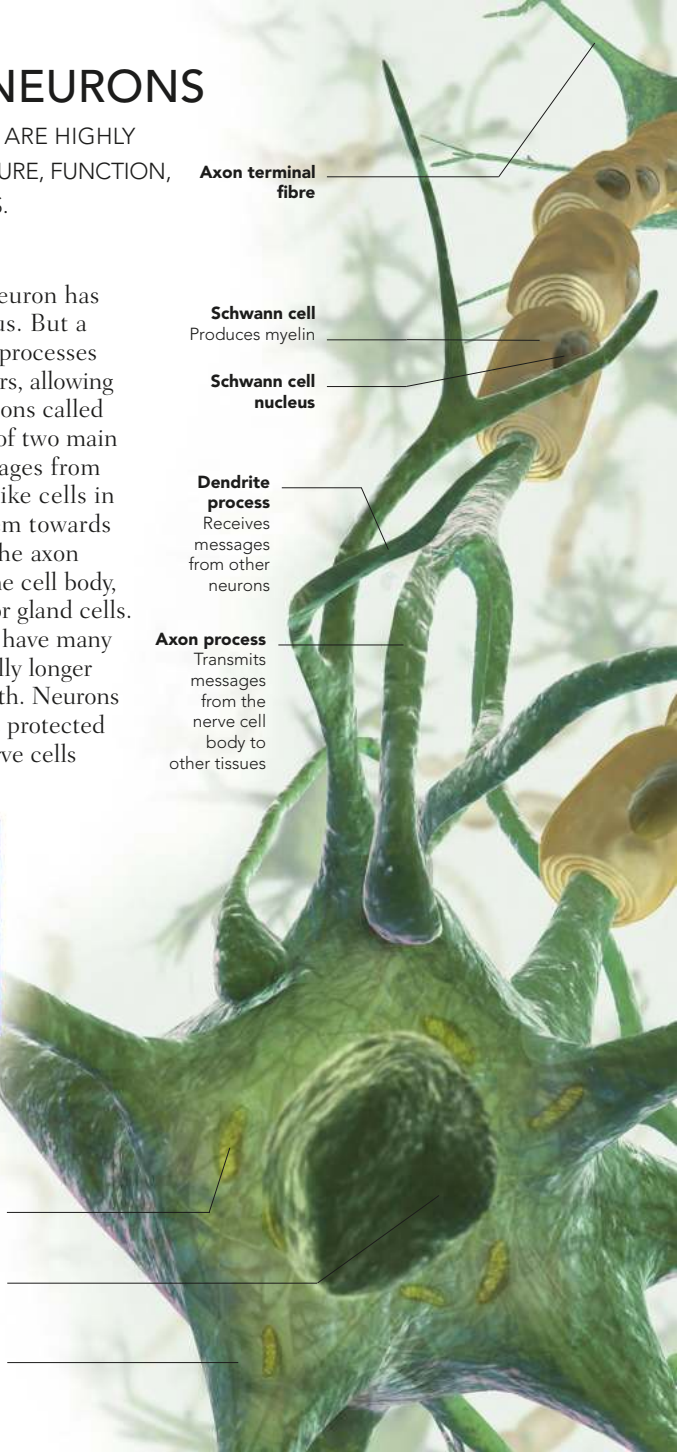
**Axon terminal fibre**

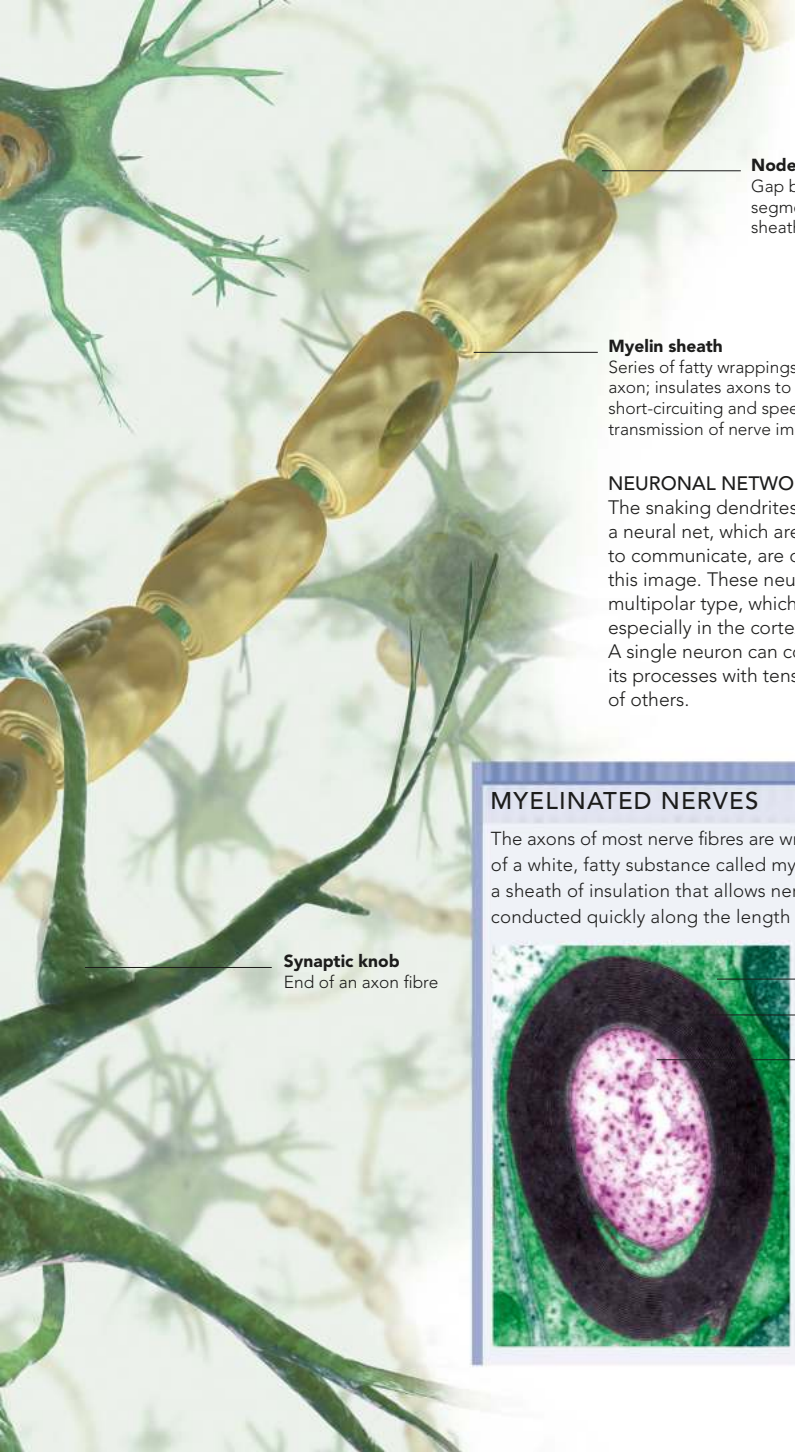
**Schwann cell**  
Produces myelin

**Schwann cell nucleus**

**Dendrite process**  
Receives messages from other neurons

**Axon process**  
Transmits messages from the nerve cell body to other tissues





**Node of Ranvier**

Gap between segments of myelin sheath on an axon

**Myelin sheath**

Series of fatty wrappings along an axon; insulates axons to prevent short-circuiting and speeds up the transmission of nerve impulses

**NEURONAL NETWORK**

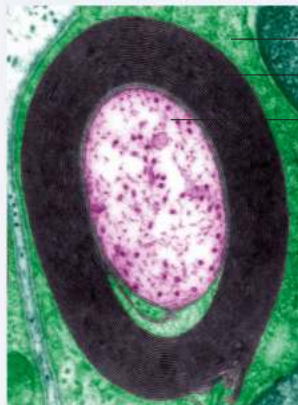
The snaking dendrites and axons of a neural net, which are reaching out to communicate, are clearly visible in this image. These neurons are of the multipolar type, which are found especially in the cortex of the brain. A single neuron can correspond via its processes with tens of thousands of others.

**Synaptic knob**

End of an axon fibre

**MYELINATED NERVES**

The axons of most nerve fibres are wrapped in thin layers of a white, fatty substance called myelin. These create a sheath of insulation that allows nerve impulses to be conducted quickly along the length of the nerve fibre.



Schwann cell

Myelin layer

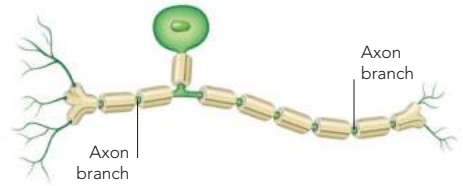
Axon

**SCHWANN CELL**

The myelin sheath that insulates a nerve fibre in the peripheral nervous system is produced by a Schwann cell, which is wrapped spirally around the body of the axon.

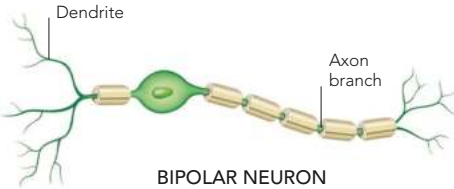
## TYPES OF NEURON

Neuron cell bodies vary greatly in size and shape, as do the type, number, and length of their projections. Neurons can be unipolar, bipolar, or multipolar. Unipolar neurons are found mainly in the sensory nerves of the PNS. Bipolar neurons exist mostly in the embryo, but adults have some in the retina of the eye and the olfactory nerve in the nose. Most neurons in the brain and spinal cord are multipolar.



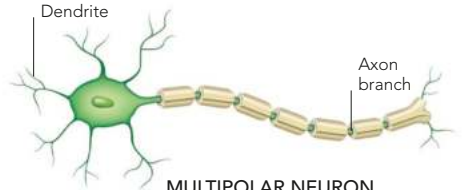
### UNIPOLAR NEURON

A single short process, an axon, extends from the nerve cell body and splits into two.



### BIPOLAR NEURON

The nerve cell body is located between two processes – an axon and a dendrite.



### MULTIPOLAR NEURON

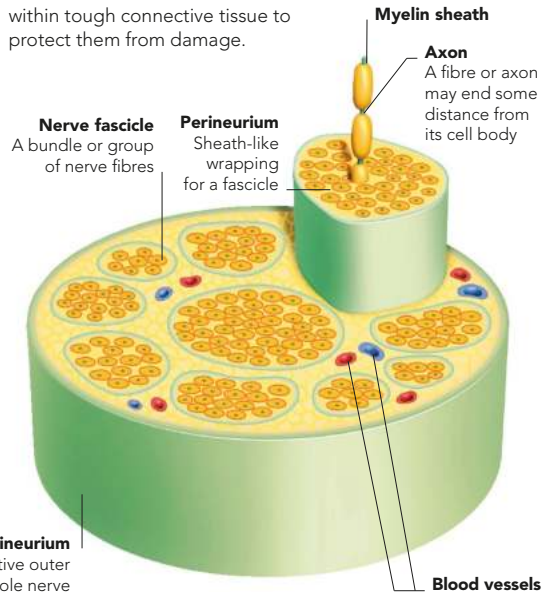
These nerve cell bodies have three or more processes – one axon and several dendrites.

## NERVES

Nerves, which resemble rope-like cords, pass between and branch into the body's organs and tissues. They are composed of bundles of communication strands – the elongated axons or nerve fibres of neurons. Each bundle is known as a fascicle. Most nerves carry two types of fibre. Sensory, or afferent, fibres bring messages from receptors in the sense organs and other structures to the spinal cord and brain. Motor, or efferent, fibres convey signals from the brain or spinal cord to a muscle or gland. Some nerves contain just sensory fibres, such as the optic nerve, while others have solely motor fibres.

### INSIDE A NERVE

Bundles of nerve fibres are embedded within tough connective tissue to protect them from damage.



### Epineurium

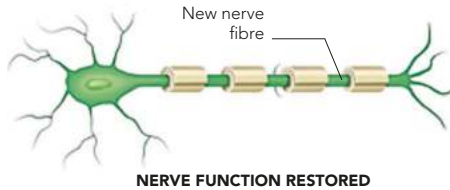
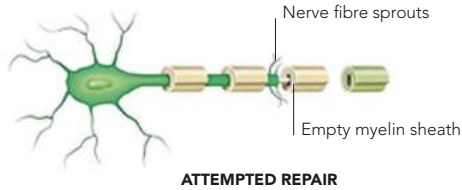
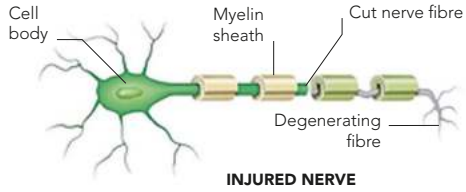
Strong, protective outer covering for the whole nerve

## NERVE REGENERATION

Peripheral nerve fibres that have been crushed or partly cut may slowly regenerate if the cell body is undamaged. The damaged section of fibre degenerates, leaving the myelin sheath hollow. The healthy remaining fibre begins to grow along the empty sheath at a rate of 1–2mm ( $\frac{1}{25}$ – $\frac{2}{25}$ in) daily. Natural regeneration is much less likely in the nerve fibres of the brain and spinal cord, where the neurons are so specialized that generally they cannot replicate themselves or recreate their highly developed connections.

### REGROWTH

The stump end of a damaged nerve fibre sends out several sprout-like growths. One of these finds the empty but intact myelin sheath and grows inside it.



## SUPPORT CELLS

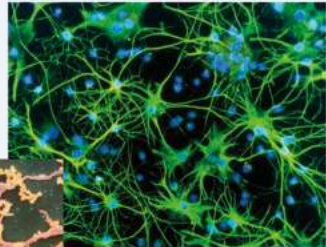
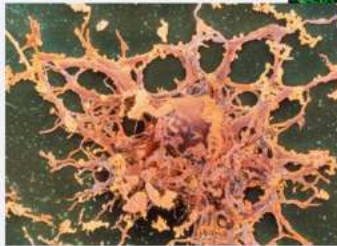
Supporting nerve cells, known as glial cells or neuroglia, protect and nourish the neurons. There are several types of glial cell.

The smallest are microglia, which destroy microorganisms, foreign particles, and cell debris from disintegrating neurons.

Ependymal cells line cavities that are filled with cerebrospinal fluid, which surrounds both the brain and spinal cord (see p.89). Other glial cells insulate the axons and dendrites or regulate the flow of cerebrospinal fluid.

### ASTROCYTE

Named after their star-like appearance, they provide support and nutrition.



### OLIGODENDROCYTE

These cells provide a support framework, and produce and nourish myelin sheath segments for certain axons.

# NERVE IMPULSE

WHEN NERVE CELLS, OR NEURONS, ARE STIMULATED THEY UNDERGO CHEMICAL CHANGES THAT PRODUCE TINY WAVES OF ELECTRICITY – NERVE IMPULSES.

Information is conveyed throughout the nervous system as nerve impulses, or action potentials. Impulses are about 100 millivolts (0.1 volts) in strength and last just 1 millisecond ( $1/1000$  s). The information carried depends on the location of the impulses in the nervous system, and on their frequency – from one impulse every few seconds to several hundreds per second.

When impulses reach a junction known as a synapse, they trigger the release of chemicals called neurotransmitters. Molecules of the neurotransmitter cross the synapse and stimulate the receiving neuron to fire an impulse of its own, as wave-like movements of ions (electrically charged particles). Neurotransmitters may also actively inhibit a receiving neuron from firing.

## Presynaptic membrane

Membrane of sending cell's axon

## Neurotransmitter

Molecule that flows across the synaptic cleft in about 1 millisecond, passing on the nerve impulse in chemical form

## Synaptic vesicle

Package of neurotransmitter molecules that fuses with the cell membrane when an impulse arrives, releasing the molecules

## Mitochondrion

Standard cellular component that provides energy

## Postsynaptic membrane

Membrane of receiving cell's dendrite

## Neurotubule

Specialized microtubule that conveys synaptic vesicles from the cell body to the axon terminal

## Synaptic knob

Enlarged end of axon terminal

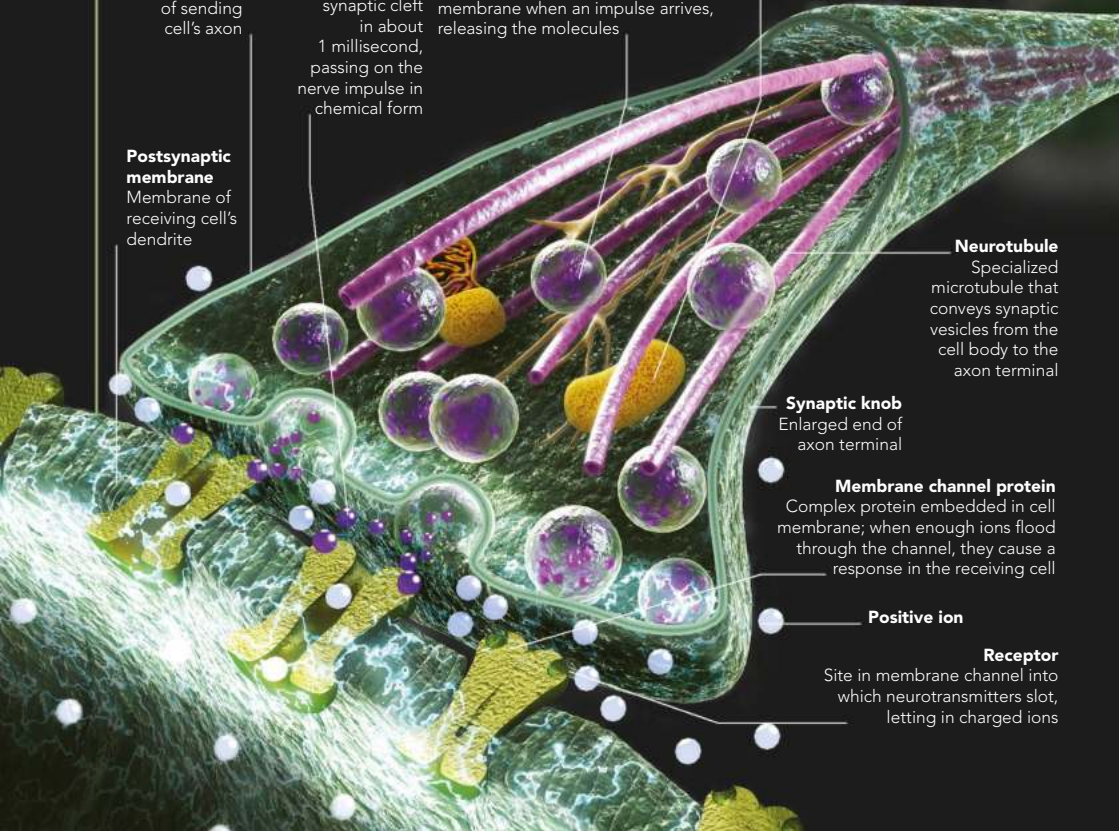
## Membrane channel protein

Complex protein embedded in cell membrane; when enough ions flood through the channel, they cause a response in the receiving cell

## Positive ion

## Receptor

Site in membrane channel into which neurotransmitters slot, letting in charged ions



**Dendrites**

Projections of neuron; collect nerve impulses from other neurons or sensory nerve endings

**Neuron cell body**

Main part of the neuron, containing the nucleus and cell components

**Axon**

Main nerve fibre of the neuron, conveying impulses away from the cell body

**Neurofibril node**

Also called node of Ranvier; portion of axon not covered by myelin

**Myelin sheath**

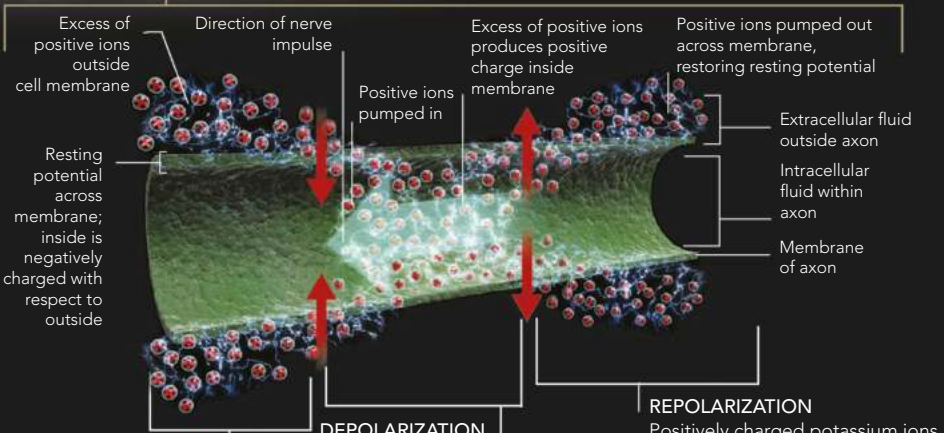
Also called neurilemma or Schwann sheath; spiralling structure of fatty myelin that helps to speed an impulse and prevent it from fading or leaking

**Schwann cell**

Sheet-like cell that grows around a portion of axon (fibre) to form the myelin sheath

## IMPULSE MOVEMENT WITHIN A NERVE CELL

A nerve impulse is based chiefly on movement of positively charged sodium and potassium ions through the neuron's cell membrane. Impulses travel at speeds of between 1 and 120m/s (3–400ft/s), depending on the type of nerve. Movement is faster in myelin-coated axons.

**RESTING POTENTIAL**

There are more positive ions outside the cell and more negative ions inside, producing a "resting potential" of  $-70$  millivolts.

**DEPOLARIZATION**

Positive ions rush in through ion channels. The membrane is first depolarized, then its polarity is reversed, resulting in an "action potential" of  $+30$  millivolts inside.

**REPOLARIZATION**

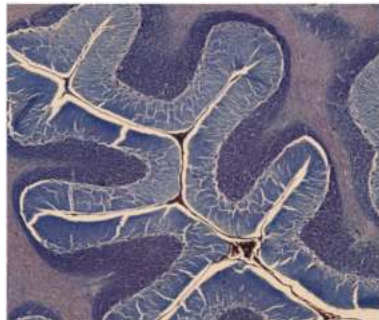
Positively charged potassium ions flow in the opposite direction, restoring the charge balance. This stimulates an adjacent area of membrane, and the next, and the impulse moves along like a wave.

# BRAIN

THE BRAIN, TOGETHER WITH THE SPINAL CORD, REGULATES NON-CONSCIOUS PROCESSES AND COORDINATES MOST VOLUNTARY MOVEMENT. IT IS THE SITE OF CONSCIOUSNESS, ALLOWING HUMANS TO THINK AND LEARN.

## BRAIN STRUCTURE

The largest part of the brain is the cerebrum, which has a heavily folded surface – the pattern of which is unique in each person. The grooves are called sulci when shallow and fissures when deep. Fissures and some of the large sulci outline four functional areas, called lobes: frontal, parietal, occipital, and temporal (see p.90). A ridge on the surface of the brain is called a gyrus. The centre of the brain contains the thalamus, which acts as the brain's information relay station. Surrounding this is a group of structures known as the limbic system (see p.94), which is involved in survival instincts, behaviour, and emotions. Closely linked with the limbic system is the hypothalamus (see p.95), which receives sensory information.



### CEREBELLUM

The cerebellum (section shown above) contains billions of neurons that link up with other regions of the brain and spinal cord to facilitate precise movement.

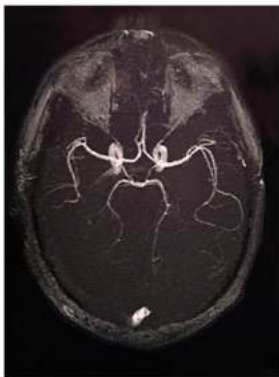
## BLOOD SUPPLY TO THE BRAIN

The brain forms 2 per cent of the body's weight but needs 20 per cent of its blood. Without oxygen and glucose, brain function quickly deteriorates, leading to dizziness and loss of consciousness. Within only four to eight minutes of oxygen deprivation, brain

damage, or death, results. The brain has an abundant supply of blood from a vast network of blood vessels that stem from the carotid arteries, which run up each side of the neck, and from two vertebral arteries that run alongside the spinal cord.

### CIRCLE OF WILLIS

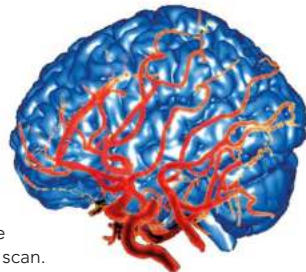
A ring of arteries, the Circle of Willis, encircles the base of the brain and provides multiple pathways to supply oxygenated blood to all parts of the brain. If a pathway becomes blocked, blood can be redirected from another pathway.



### BLOOD SUPPLY

The brain has an extensive blood supply from two front and two rear arteries, as illustrated in this colour, three-dimensional magnetic resonance angiography (MRA) scan.

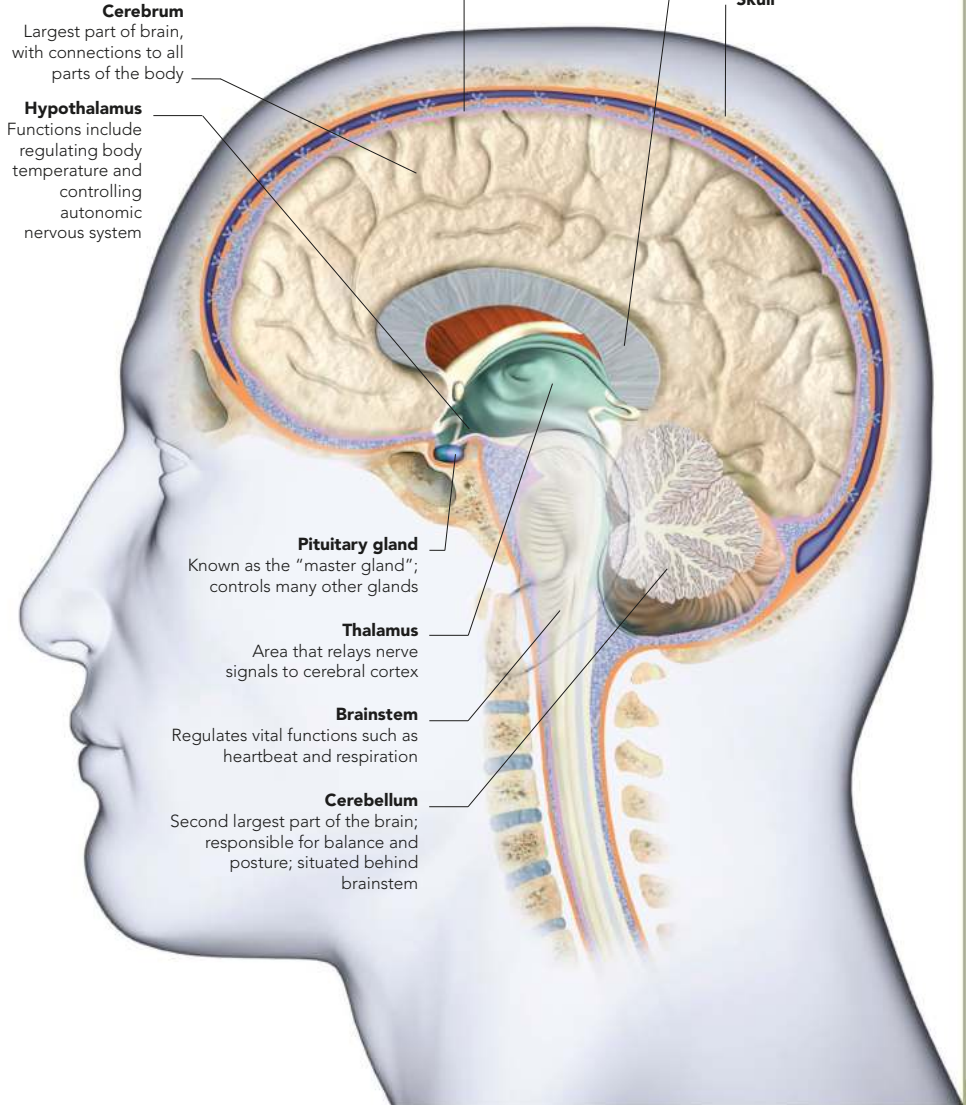
The blood vessels are coloured in red; here, they are seen supplying oxygenated blood to various parts of the brain, which is shown as the blue area.





## INNER STRUCTURES

A section down the middle of the brain reveals its inner structures. Although these structures look very different in the diagram below, they are all made up of brain tissue, which is composed of billions of neurons. There are two types of brain tissue – grey matter and white matter.



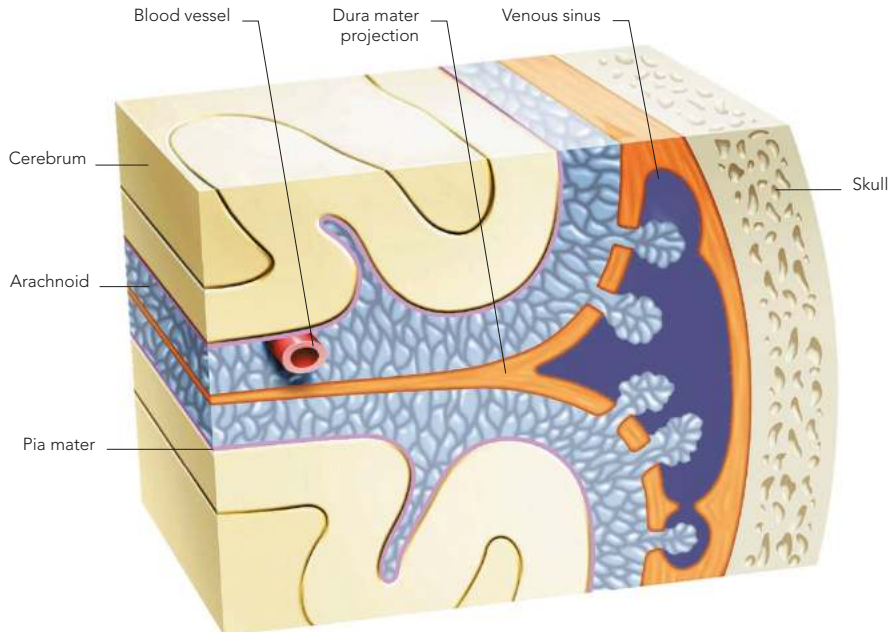
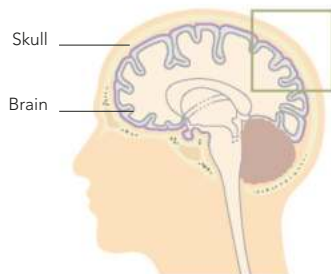
## PROTECTION

The brain has several forms of protection. First and foremost is the skull (see p.48). Between the skull and the grey matter of the cerebrum lie three protective membranes that also protect the spinal cord (see p.98). The dura mater lines the inside of the skull, where it is attached to the bones; it is a thick, inelastic layer that provides support and protection. The arachnoid membrane lies beneath the dura, and was named for its resemblance to a spider's web. The pia mater adheres to the convolutions of the cerebrum, and supplies brain tissue with blood vessels.

Protection also comes from the cerebrospinal fluid (see opposite) in the subarachnoid space, between the arachnoid membrane and the pia mater. It absorbs and disperses excessive mechanical forces that might otherwise cause serious injury. Analyses of its chemical constituents and flow pressure have offered vital clues for diagnosing diseases and disorders of the brain and spinal cord, such as meningitis.

## MENINGES OF THE BRAIN

A section through the skull and brain reveals the three meninges. The dura mater lines the skull, and sends four projections inward to give support. The arachnoid membrane cushions the brain, and the pia mater closely envelops the cerebrum.



## CEREBROSPINAL FLUID FLOW

The tissue of the brain floats in cerebrospinal fluid (CSF) within the skull. CSF is a clear liquid, which is renewed four to five times a day. CSF protects and nourishes the brain and spinal cord as it flows around them. It contains proteins and glucose that provide energy for brain cell function, as well as

lymphocytes that guard against infection. CSF is produced by the choroid plexuses in the lateral ventricles, and drains into the third ventricle. It then flows into the fourth ventricle, which is located in front of the cerebellum. Circulation of the fluid is aided by pulsations of the cerebral arteries.

### 1 Site of fluid production (choroid plexuses)

The CSF found in the ventricles in the brain is produced in clusters of thin-walled capillaries, known as choroid plexuses. These capillaries line the walls of the ventricles.

### 4 Site of reabsorption (arachnoid granulations)

After circulating around the brain, CSF is reabsorbed into the blood via structures known as arachnoid granulations, which are projections of the arachnoid layer into the large sagittal sinus, or cerebral vein.

### 2 Direction of flow

Fluid moves from the brain's lateral ventricles into the third and fourth ventricles. The fluid then flows up the back of the brain, down around the spinal cord, and up to the front of the brain, as indicated by the arrows.

**Lateral ventricle**  
**Dura mater**

Sagittal sinus

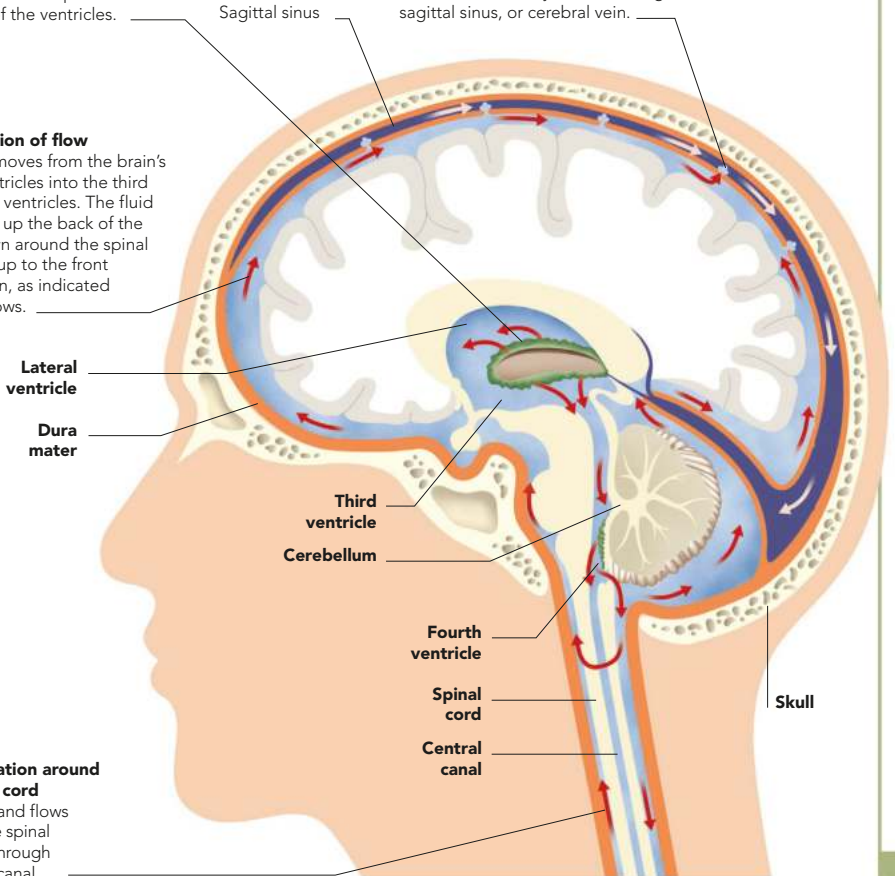
**Third ventricle**  
**Cerebellum**

**Fourth ventricle**  
**Spinal cord**  
**Central canal**

Skull

### 3 Circulation around spinal cord

CSF ebbs and flows around the spinal cord and through its central canal.



# BRAIN STRUCTURES

THE BRAIN HAS FOUR MAIN STRUCTURES: THE LARGE, DOMED CEREBRUM; THE INNER, DEEPER DIENCEPHALON (CONSISTING OF THE THALAMUS AND NEARBY STRUCTURES); THE CEREBELLUM, TO THE LOWER REAR; AND THE BRAINSTEM, AT THE BASE.

## EXTERNAL BRAIN FEATURES

The cerebrum makes up more than four-fifths of the brain's tissue. Its heavily folded surface forms the lobes of the cerebral cortex. The cerebrum partly envelops the thalamus and nearby structures, and also

the brainstem. The smaller cerebellum forms about one-tenth of the brain's volume; it is mainly concerned with organizing motor information sent to muscles so that body movements are smooth and coordinated.

**Lateral sulcus**  
Groove running along upper part of temporal lobe

**Frontal lobe**  
Controls movement, speech, and aspects of "personality"

**Parietal lobe**  
Area where pain, pressure, temperature, and touch are perceived and interpreted

**Postcentral gyrus**  
This ridge, or bulge, is a key anatomical landmark that lies just behind the mid-point from front to rear

**Parietal occipital fissure**  
Fissure (deep groove) that demarcates border between parietal and occipital lobes

**Superior temporal sulcus**  
Upper of two main sulci (shallow grooves) that divide chief gyri (bulges) of temporal lobe

**Temporal lobe**  
Governs recognition of sounds, and their tones and loudness; plays a role in memory storage

**Occipital lobe**  
This area is mainly concerned with analysing and interpreting visual information, from sensory nerve signals sent by the eyes

**Pons**  
Upper portion of brainstem

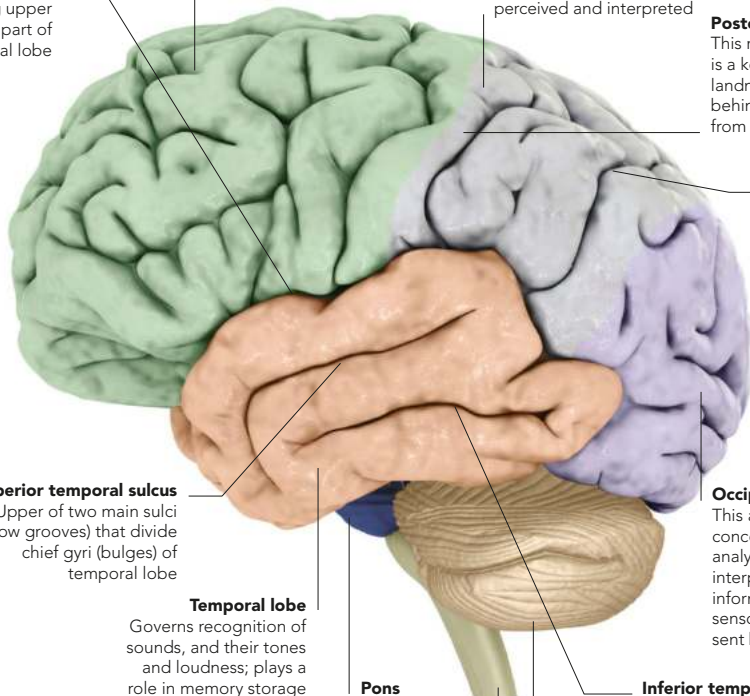
**Inferior temporal sulcus**  
Lower of two main sulci (shallow grooves) that divide gyri (bulges) of temporal lobe

## LOBES OF THE BRAIN

Traditionally, four major lobes are identified on the cerebral surface. The names of some of the lobes parallel the names of the skull bones that overlie them (see p.48).

**Brainstem**  
Lowest, mainly "automatic" region of brain (see p.93)

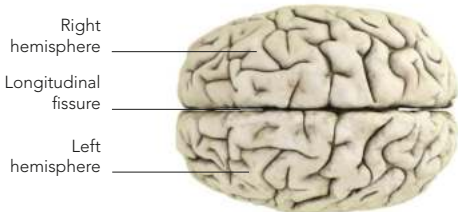**Cerebellum**  
This "little brain" is involved with timing and accuracy of skilled movements, and controls balance and posture



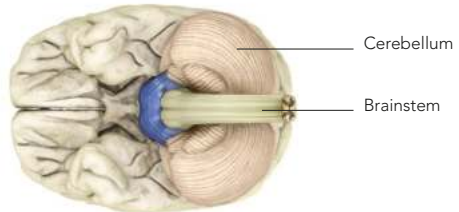
## OUTER BRAIN STRUCTURES

The cerebrum is partly separated into two halves (cerebral hemispheres) by the deep longitudinal fissure. The cerebellum is the smaller bulbous

structure beneath, responsible for muscle control. Below the cerebellum is the brainstem, which controls basic life processes.



TOP VIEW

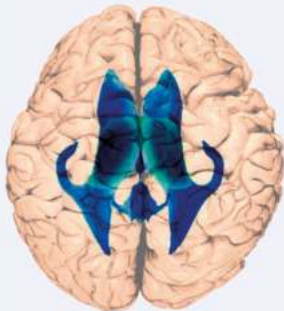

BOTTOM VIEW

## THE HOLLOW BRAIN

The brain is, in a sense, hollow: it contains four chambers known as ventricles, which are filled with cerebrospinal fluid, or CSF (see p.89). There are two lateral ventricles, one in each hemisphere, and the CSF fluid is produced here. It then drains via the interventricular foramen into the third ventricle, which is situated close to the thalamus and occupies

a more central position. From here it flows through the cerebral aqueduct and into the fourth ventricle, which extends down between the pons and cerebellum into the medulla. The total volume of CSF in the ventricles is about 25ml (2/10 fl oz). Circulation is aided by head movements and pulsations of the cerebral arteries.



VIEW FROM ABOVE

The lateral ventricles have frontward-, backward-, and side-facing horns, or cornua. The central third ventricle lies between them in this view.

### Interventricular foramen

Opening through which fluid drains from lateral to third ventricle

### Lateral ventricles

### Third ventricle

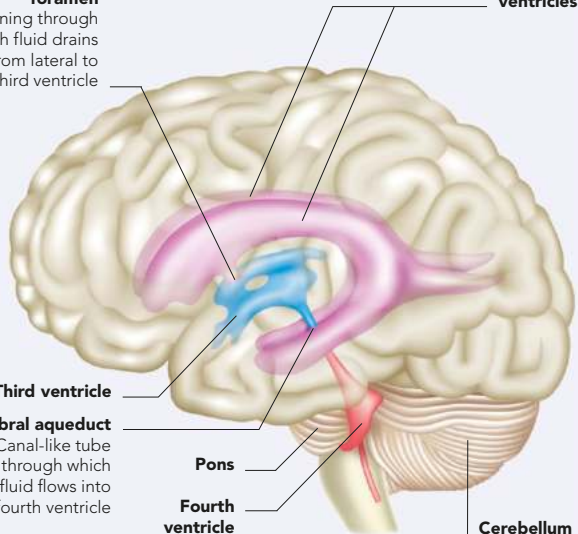
### Cerebral aqueduct

Canal-like tube through which fluid flows into fourth ventricle

### Pons

### Fourth ventricle

### Cerebellum



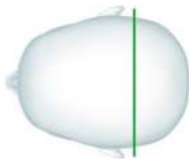
## GREY AND WHITE MATTER

Most of the cerebrum has two main layers. The outer layer, often known as “grey matter”, is the cerebral cortex. It follows the folds and bulges of the cerebrum to cover its entire surface. Its average thickness is 3–5mm ( $\frac{1}{10}$ – $\frac{2}{10}$  in), and, spread out flat, it would cover about the same area as a

pillowcase. Deeper within the cerebrum are small islands of grey matter. These, and the cerebral cortex, are composed chiefly of the cell bodies and projections (dendrites) of neurons. The paler “white matter” forms the bulk of the cerebrum’s interior. It is composed mainly of nerve fibres.

### CORONAL SECTION

A vertical “slice” through the middle of the brain reveals the paired structures, outer grey layer, and inner white matter. The corpus callosum contains more than 100 million nerve fibres, and is the main “bridge” between the two hemispheres.



#### Corpus callosum

Largest of several bundles of nerve fibres, called commissures, which connect specific areas of the two halves, or cerebral hemispheres, of the upper brain

#### Grey matter

Outermost layer of cerebral cortex; contains an estimated 50 billion neurons and perhaps 10 times as many supporting cells

#### White matter interior

Here, axons, or fibres, of neurons run up from lower areas and project down from neuron cell bodies of cortex

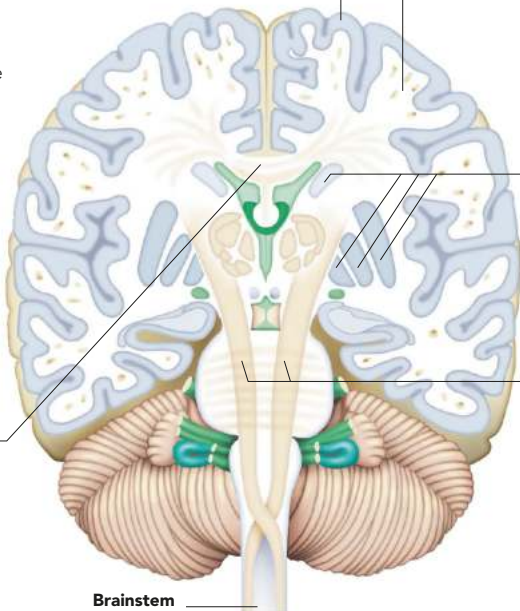
#### Basal ganglia

“Islands” of grey matter deep in cerebrum

#### Motor nerve tracts

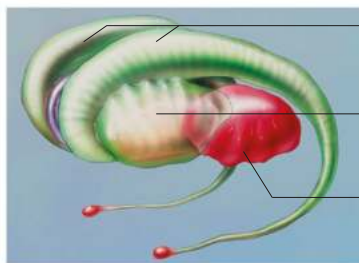
Large bundles of nerve fibres carry instructions for movements down to the spinal cord; they cross over in lower brainstem

#### Brainstem



### BASAL GANGLIA

These structures include the lentiform nucleus (putamen and globus pallidus), caudate nucleus, subthalamic nucleus, and substantia nigra (the latter two not seen in this view). They are a complex interface between sensory inputs and motor skills, especially for semi-automatic movements, such as walking.



Caudate nucleus

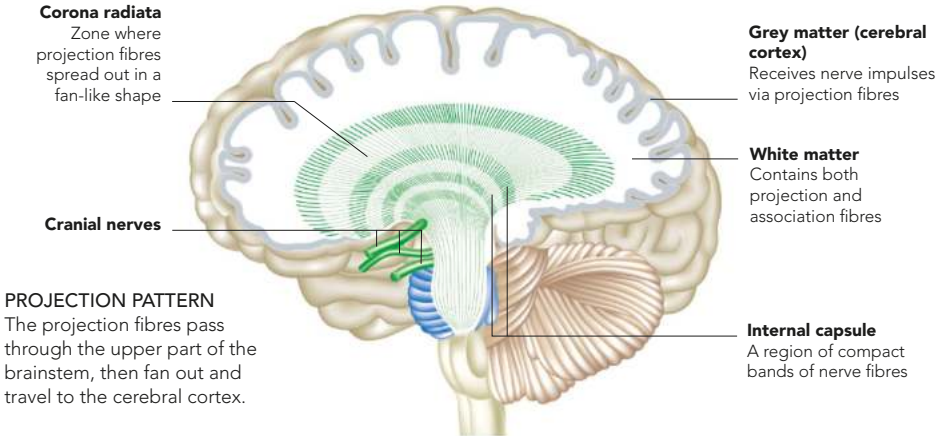
Lentiform nucleus

Thalamus

## VERTICAL LINKS

Sheathed (myelinated) nerve fibres are organized into bundles called projection tracts. These nerve fibres transmit impulses between the spinal cord and lower brain areas and the cerebral cortex above. The nerve tracts pass through a communication link called the internal capsule, and also

intersect the corpus callosum. In addition, similar bundles pass through the upper, outer zones of the white matter, from one area of the cerebral cortex to another. These bundles, called association tracts, convey nerve signals directly between different regions or centres of the cortex.

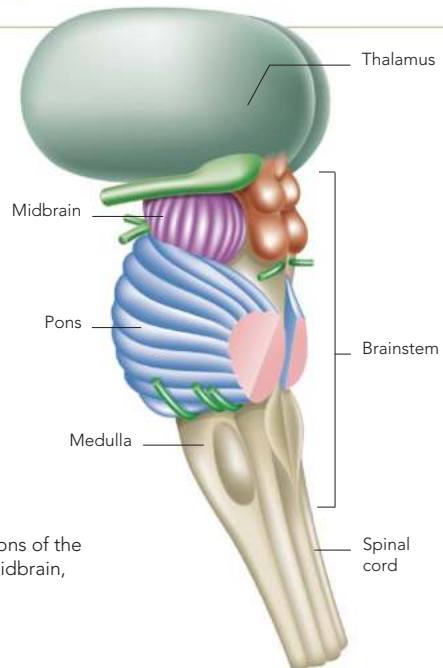


## THE THALAMUS AND BRAINSTEM

The thalamus sits on top of the brainstem, and is shaped like two eggs placed side by side. It lies almost at the “heart” of the brain, and acts like a major relay station that monitors and processes incoming information before this is sent to the upper regions of the brain. The brainstem contains centres that regulate several functions vital for survival: these functions include the heartbeat, respiration, blood pressure, and some reflex actions, such as swallowing and vomiting.

### BRAINSTEM

The three main regions of the brainstem are the midbrain, pons, and medulla.



# THE PRIMITIVE BRAIN

IN TIMES OF STRESS OR CRISIS, DEEP-SEATED INSTINCTS WELL UP FROM WITHIN US AND TAKE OVER OUR AWARENESS. SUCH EVENTS INVOLVE THE “PRIMITIVE BRAIN”, WHICH IS BASED MAINLY IN A SERIES OF PARTS KNOWN AS THE LIMBIC SYSTEM.

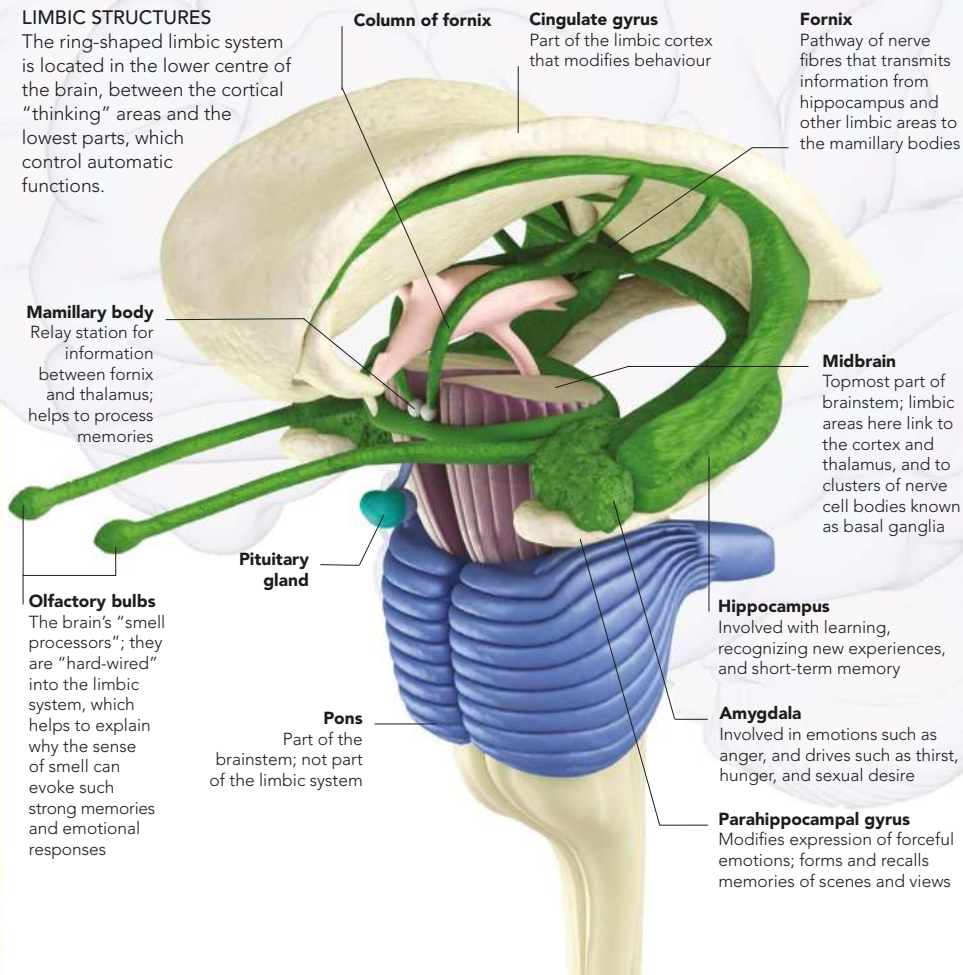
## THE LIMBIC SYSTEM

The limbic system influences subconscious, instinctive behaviour, similar to animal responses that relate to reproduction and survival. In humans, many of these innate, “primitive” behaviours are modified by conscious, thoughtful considerations based

in upper regions of the brain. However, when primal urges prevail, the limbic system and its associated structures take over. At other times they play lesser, but still complex and important, roles in the expression of instincts, drives, and emotions.

### LIMBIC STRUCTURES

The ring-shaped limbic system is located in the lower centre of the brain, between the cortical “thinking” areas and the lowest parts, which control automatic functions.



#### Mamillary body

Relay station for information between fornix and thalamus; helps to process memories

#### Olfactory bulbs

The brain’s “smell processors”; they are “hard-wired” into the limbic system, which helps to explain why the sense of smell can evoke such strong memories and emotional responses

#### Pituitary gland

**Pons**  
Part of the brainstem; not part of the limbic system

#### Column of fornix

#### Cingulate gyrus

Part of the limbic cortex that modifies behaviour

#### Fornix

Pathway of nerve fibres that transmits information from hippocampus and other limbic areas to the mamillary bodies

#### Midbrain

Topmost part of brainstem; limbic areas here link to the cortex and thalamus, and to clusters of nerve cell bodies known as basal ganglia

#### Hippocampus

Involved with learning, recognizing new experiences, and short-term memory

#### Amygdala

Involved in emotions such as anger, and drives such as thirst, hunger, and sexual desire

#### Parahippocampal gyrus

Modifies expression of forceful emotions; forms and recalls memories of scenes and views



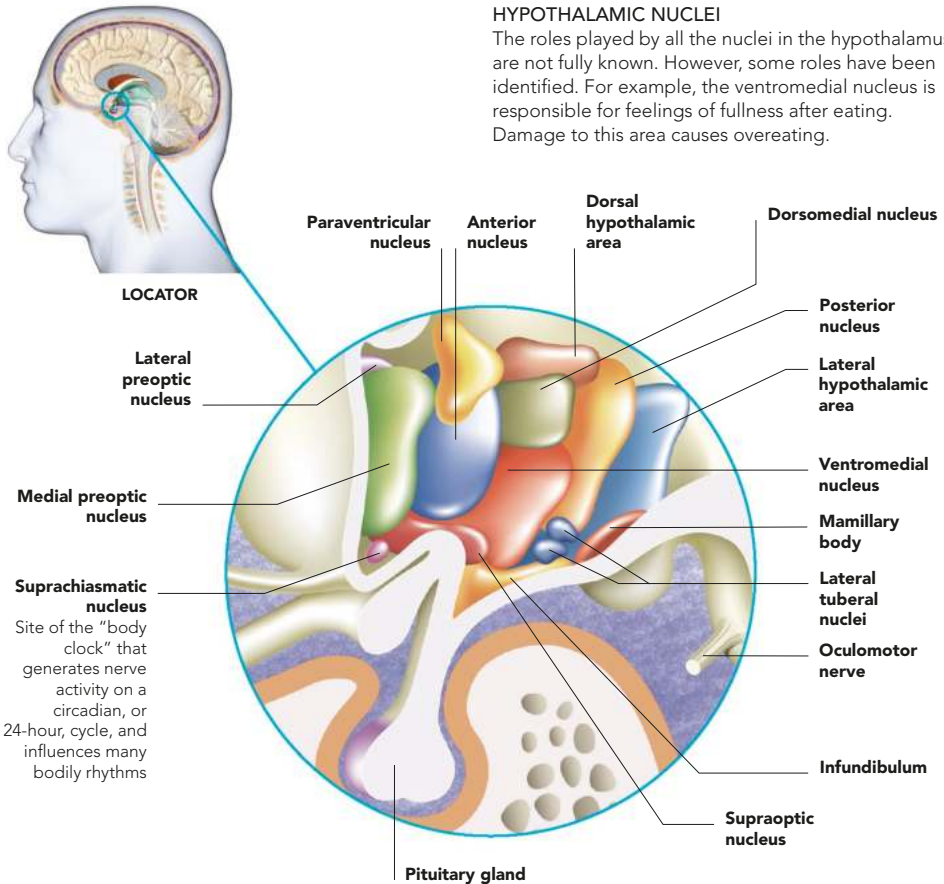
## THE HYPOTHALAMUS

The hypothalamus, which literally means “below the thalamus”, is about the size of a sugar cube and contains numerous tiny clusters of neurons called nuclei. It forms an important part of the relationship between the brain and the body, and is usually regarded as the vital integrating centre of the limbic system. A stalk below links it to the pituitary gland (see p.134), which helps to regulate the activity of the endocrine system, including the thyroid and adrenal glands. The hypothalamus

also has complex associations with the rest of the limbic system around it, and with the autonomic parts of the general nervous system. Functions of the hypothalamus include monitoring and regulating vital internal conditions such as nutrient levels, body temperature, water–salt balance, blood flow, the sleep–wake cycle, and the levels of hormones such as sex hormones. The hypothalamus also initiates feelings, actions, and emotions such as hunger, thirst, rage, and terror.

### HYPOTHALAMIC NUCLEI

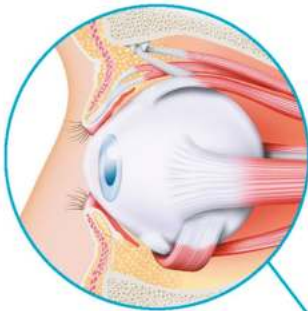
The roles played by all the nuclei in the hypothalamus are not fully known. However, some roles have been identified. For example, the ventromedial nucleus is responsible for feelings of fullness after eating. Damage to this area causes overeating.



## THE RETICULAR FORMATION

The reticular formation is a structure containing various clusters of neurons (nuclei) together with a series of long, slim nerve tracts that are located in much of the length of the brainstem (see p.93). Its fibres extend to the cerebellum behind, the diencephalon above, and the spinal cord below. The reticular formation comprises several distinct neural systems, each with its own neurotransmitter (the chemical that

passes on nerve signals at the tiny junctions, or synapses, between neurons). One of the reticular formation's many functions is to operate an arousal system, known as the reticular activating system (RAS), that keeps the brain awake and alert. The reticular formation also includes the cardiorespiratory and respiratory centres that control heart rate and breathing, and other essential centres.



### Radiating signals

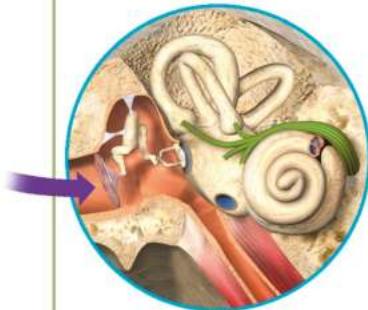
The RAS sends activating signals up through the midbrain to regions of the cerebral cortex, while other nerve fibres return feedback

### Activating signals

Nerve signals arrive at the cerebral cortex to maintain the state of wakeful readiness so that the mind remains conscious and alert

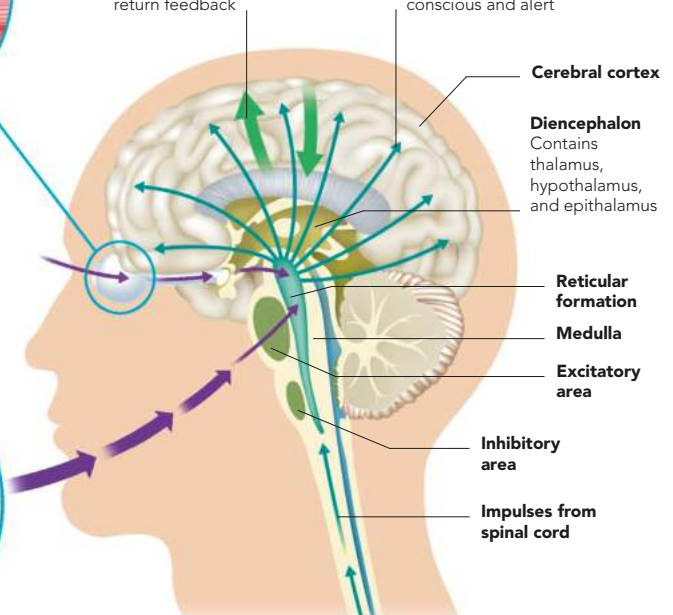
### VISUAL IMPULSES

Sensory input to the RAS travels along the optic nerves from the eyes, alerting the brain to possible danger.



### AUDITORY IMPULSES

The RAS filters out insignificant sensory information, such as background noise, and reacts if there is a change in input.



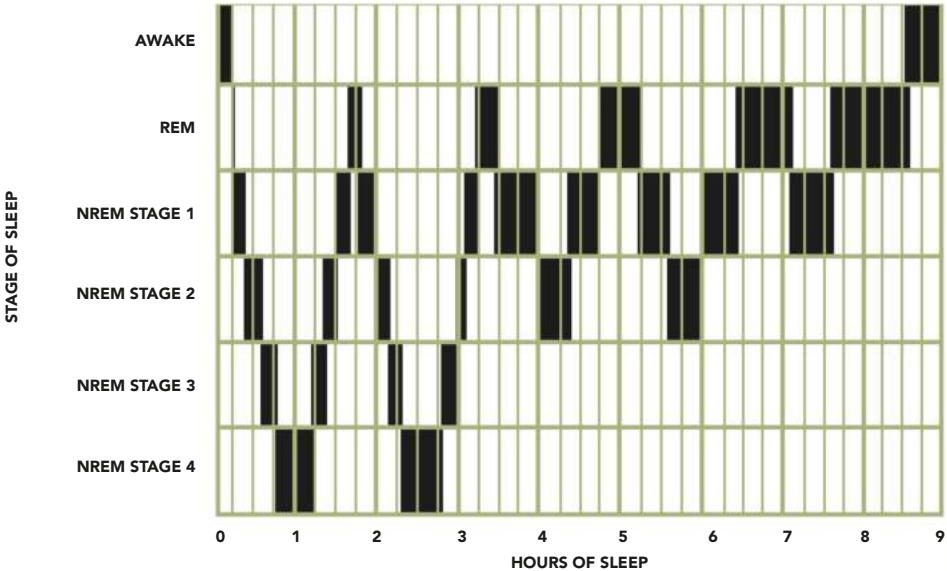
### THE RETICULAR ACTIVATING SYSTEM

Long, slender pathways of nerve fibres in the reticular formation, which is located within the brainstem, detect incoming sensory information from many sources. They send activating signals to the higher centres of the brain.


## SLEEP CYCLES

During sleep, much of the body rests, but not the brain. Its billions of neurons continue to send signals, as shown by EEG traces. Sleep occurs in cycles, which are made up of lengthening phases of REM (rapid eye movement) sleep, when most dreaming occurs, and four stages of NREM

(non-rapid eye movement sleep), which is mostly dreamless. In stage 1, sleep is light: people wake relatively easily, and brain waves are active. In stage 2, brain waves begin to slow down. In stage 3, fast and slow waves are interspersed. In stage 4, the deepest stage, there are slow waves only.




NREM SLEEP: STAGE 1



NREM SLEEP: STAGE 4



NREM SLEEP: STAGE 2



REM SLEEP



NREM SLEEP: STAGE 3

### SLEEP STAGES

EEG traces show different waveforms of brain activity for each sleep stage. As the body reaches the deeper stages, body temperature, heart rate, breathing rate, and blood pressure all reduce. During REM sleep, these functions increase slightly and most dreaming occurs.

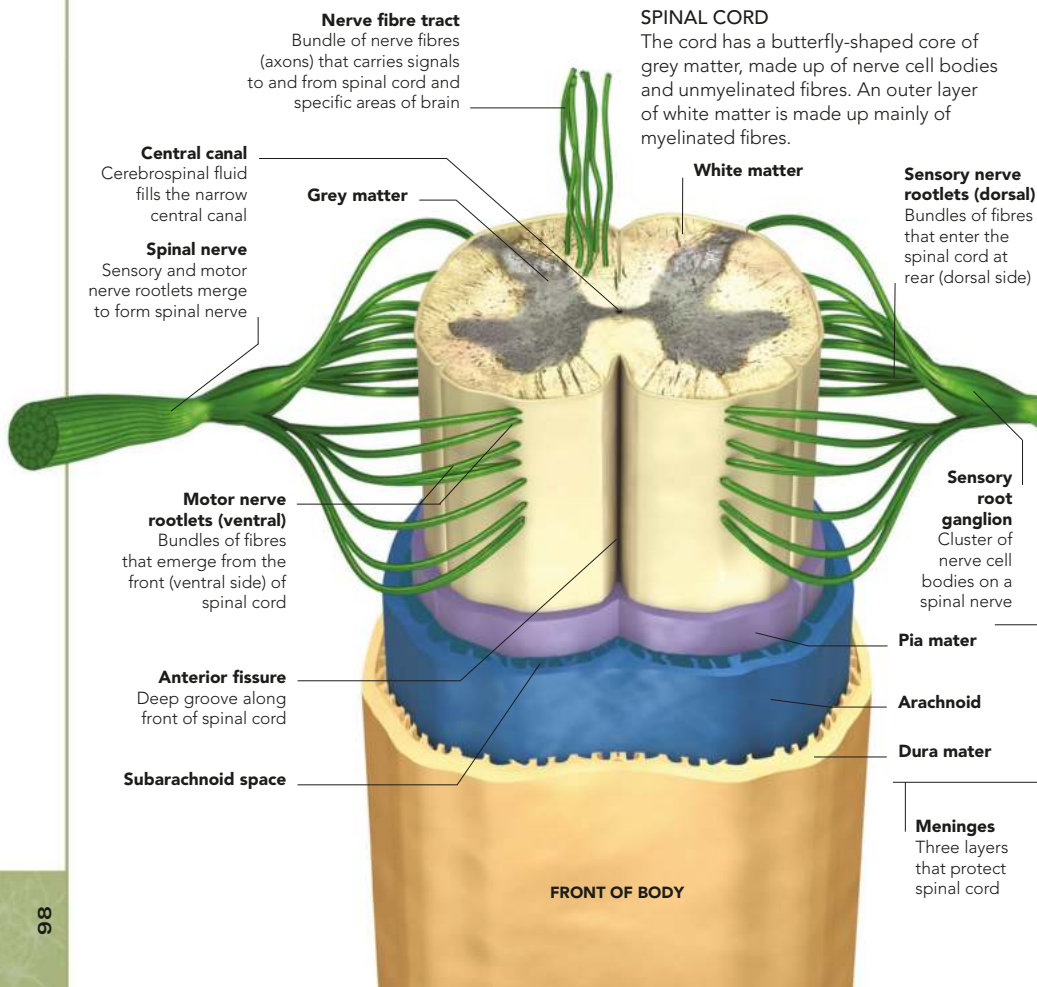
# SPINAL CORD

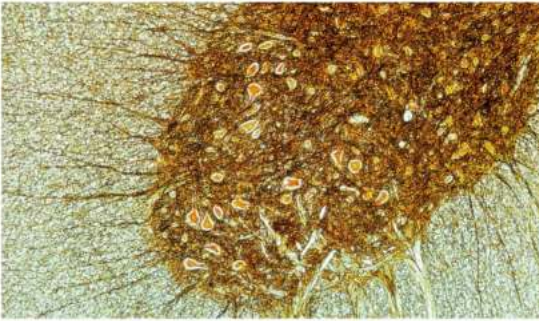
THE NERVE FIBRES OF THE SPINAL CORD LINK THE BRAIN WITH THE TORSO, ARMS, AND LEGS. THE CORD IS MORE THAN A PASSIVE CONDUIT FOR NERVE SIGNALS. WHEN NECESSARY, IT CAN BYPASS THE BRAIN: FOR EXAMPLE, IN REFLEX ACTIONS.

## SPINAL CORD ANATOMY

The spinal cord is a bundle of nerve fibres (axons) about 40–45cm (16–18in) long. It is only slightly wider than a pencil for most of its length, tapering to a thread-like tail at the lower (lumbosacral) part of the spine. Branching out from the cord are 31 pairs

of spinal nerves, which carry sensory information to the cord about conditions within the body and transmit the sense of touch from the skin. They also convey motor information to muscles throughout the body and to glands within the chest and abdomen.





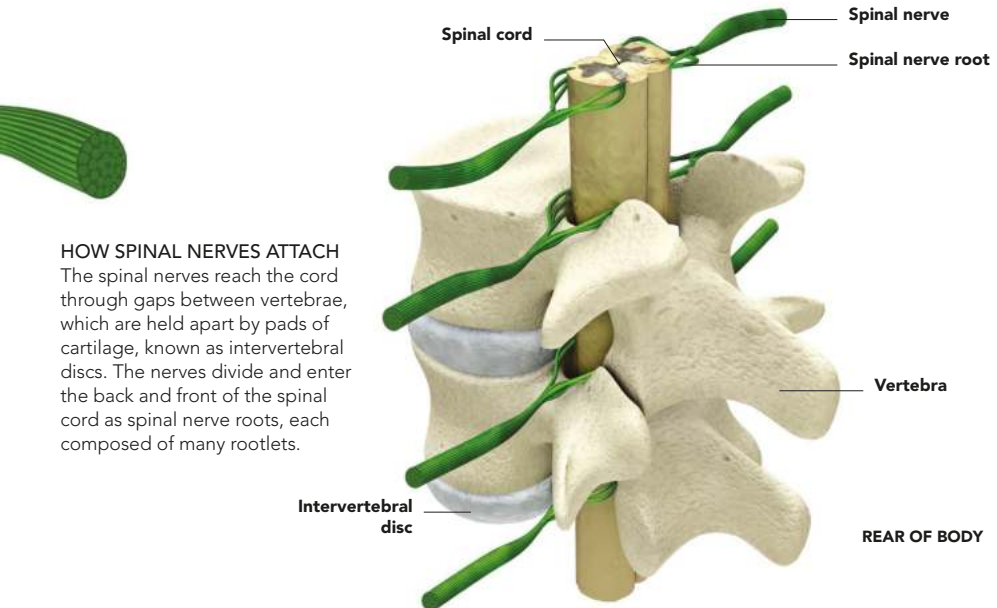
### SPINAL GREY MATTER

This microscopic view of a cross-section through the spinal cord shows a brown-stained "wing" of the butterfly-shaped grey matter, which lies at the cord's centre.

### NERVE CROSSOVER

Bundles of nerve fibres (axons) in the left and right sides of the spinal cord do not all pass straight up into the left and right sides of the brain. In the uppermost portion of the spinal cord and the lower brainstem (the part called the medulla; see p.93), many of the fibres cross over, or decussate, to the other side – left to right, and right to left. This means that nerve signals about, for example, touch sensations on the left side of the body reach the

touch centre (somatosensory cortex) on the right side of the brain. Likewise, motor signals from the right motor cortex in the brain and the right side of the cerebellum travel to the muscles on the left side of the body. Different major bundles, or tracts, of fibres decussate at slightly different levels. About one-tenth of those that cross over do so in the upper spinal cord, and the remainder cross over in the medulla.



### HOW SPINAL NERVES ATTACH

The spinal nerves reach the cord through gaps between vertebrae, which are held apart by pads of cartilage, known as intervertebral discs. The nerves divide and enter the back and front of the spinal cord as spinal nerve roots, each composed of many rootlets.

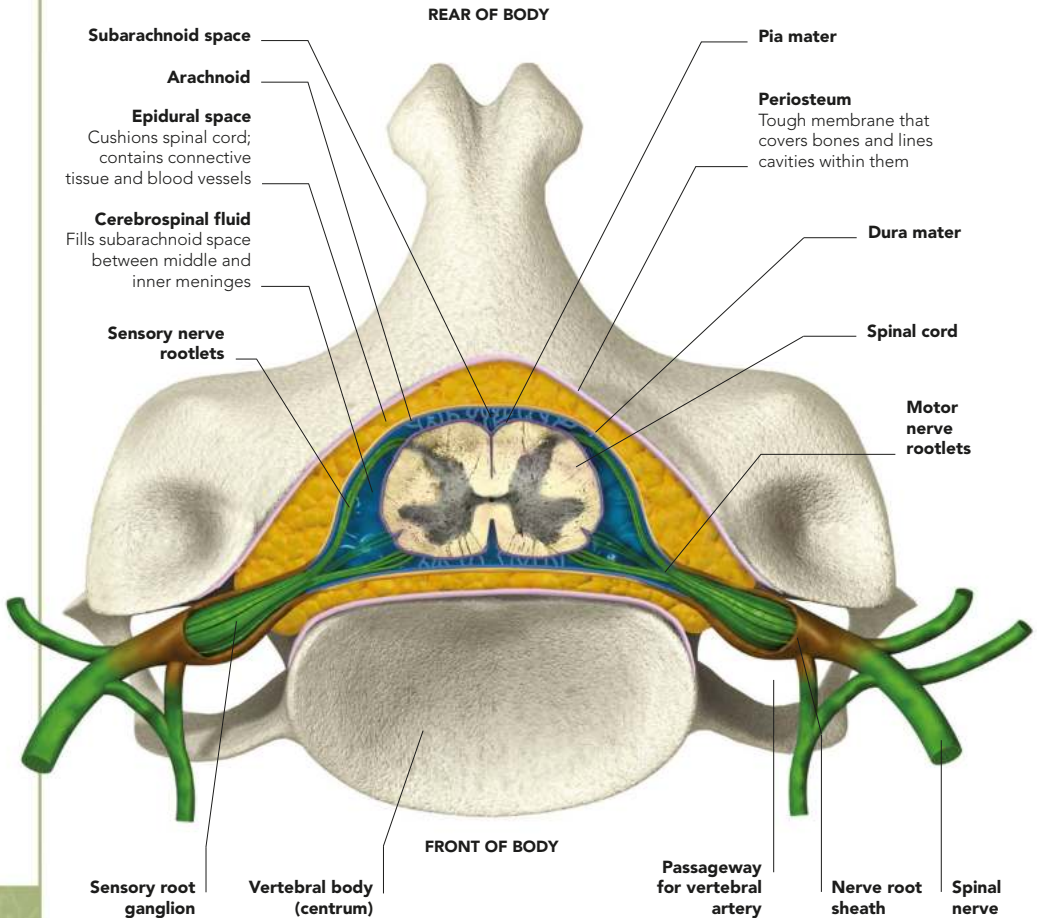
## PROTECTION OF THE SPINAL CORD

The spinal cord is located inside the spinal canal, which is a long tunnel within the aligned column of backbones (vertebrae). This vertebral column, along with its strengthening ligaments and muscles, bends and flexes the cord, but also guards it from direct knocks and blows. Within the spinal canal, the circulating cerebrospinal fluid (see p.89) acts as a shock-absorber and the epidural space provides a

cushioning layer of fat and connective tissue. The epidural tissues lie between the periosteum (the membrane that lines the bone of the spinal canal) and the dura mater, the outer layer of the meninges.

### INSIDE THE SPINAL CANAL

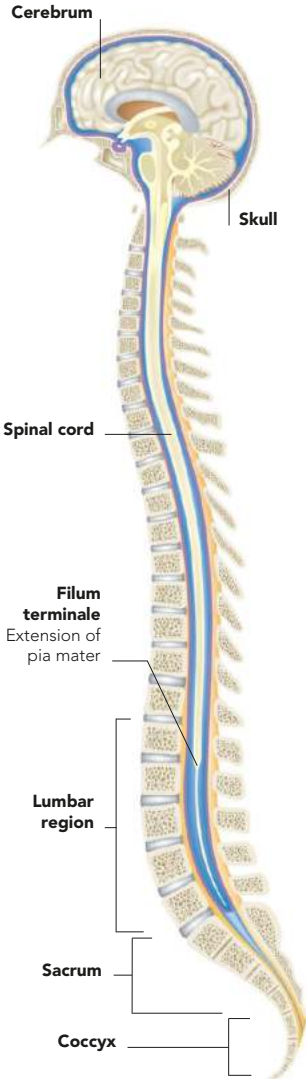
A cross-section of the vertebral column in the neck (cervical) region shows how the spinal cord nestles in the well-padded bony cavity. Although the vertebrae shift position as the trunk of the body moves, the spinal cord remains well supported and protected.



## EXTENT OF THE SPINAL CORD

While the body is growing, the spinal cord does not continue to lengthen the way that the spinal bones do. By adulthood, it extends from the brain down to the first lumbar vertebra (L1) in the lower back. Here, the

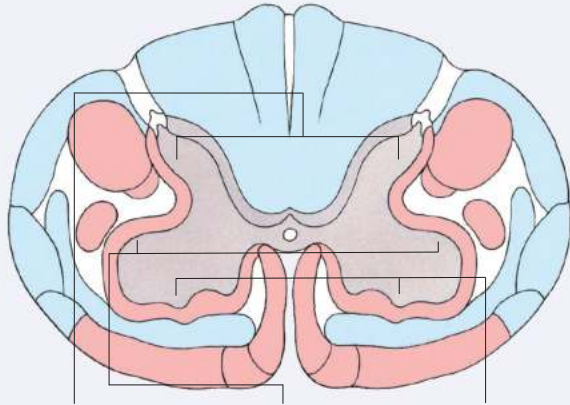
cord forms a cone-shaped ending that tapers to a slender, tail-like filament, known as the filum terminale. This extends down through the lumbar and sacral vertebrae to the coccyx.



## NERVE TRACTS OF SPINAL CORD

In the white matter of the spinal cord, nerve fibres are grouped into main bundles, or tracts, according to the direction of the nerve signals that they carry and the type of signals they transmit and respond to, such as pain

sensations or temperature. Some tracts connect and relay impulses between a few local pairs of spinal nerves, without sending fibres up to the brain. The central grey matter of the cord is organized into horns, or columns.



**Dorsal (back) horns**  
Neurons here receive sensory information about touch, balance, muscle activity, and temperature

**Lateral (side) horns**  
Neurons here monitor and regulate internal organs, such as the heart, lungs, stomach, and intestines

**Ventral (front) horns**  
Neurons here send signals along motor fibres to skeletal muscles, causing them to contract and move

- ASCENDING TRACTS**  
These ascending tracts are bundles of nerve fibres that relay impulses about bodily sensations, and inner sensors such as pain, up the spinal cord to the brain.
- DESCENDING TRACTS**  
These descending tracts convey motor signals from the brain to the skeletal muscles of the torso and limbs in order to bring about voluntary movements.

# PERIPHERAL NERVES

THE BODY'S NETWORK OF PERIPHERAL NERVES COMMUNICATES WITH THE BRAIN AND SPINAL CORD. SENSORY FIBRES CARRY MESSAGES FROM SENSE AND INTERNAL ORGANS, WHILE MOTOR FIBRES CONTROL MUSCLE AND GLAND ACTIVITY.

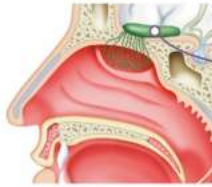
## CRANIAL NERVES

The 12 pairs of cranial nerves connect to the brain directly, not via the spinal cord. Some perform sensory functions for organs and tissues in the head and neck, while others have motor functions. The nerves with predominantly motor fibres also contain some sensory fibres that convey information to the brain about the amount

of stretch and tension in the muscles they serve, as part of the proprioceptive sense (see p.73). Most of the cranial nerves are named according to the body parts they serve, such as the optic nerves (eyes). By convention, the nerves are also identified by Roman numerals, so the trigeminal nerve, for example, is cranial V (five).

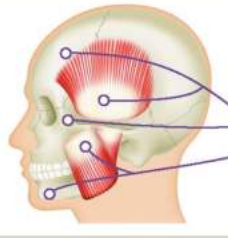
### Olfactory nerve (I, sensory)

Relays information about smells from the olfactory epithelium inside the nose, via the olfactory bulbs and tracts, to the brain's limbic centres.



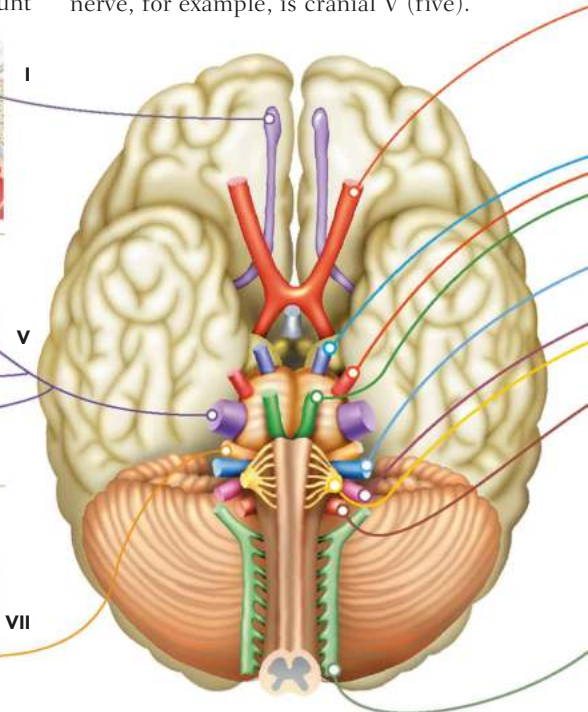
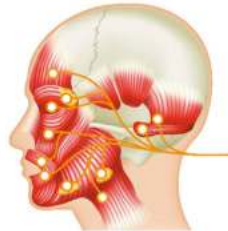### Trigeminal nerve (V, two sensory and one mixed branch)

Ophthalmic and maxillary branches send signals from the eye, face, and teeth; mandibular fibres control chewing and send sensory signals from the lower jaw.



### Facial nerve (VII, mixed)

Sensory branches come from the taste buds of the front two-thirds of the tongue; motor fibres run to the muscles of facial expression and to the salivary and lacrimal glands.



### VIEW FROM BELOW

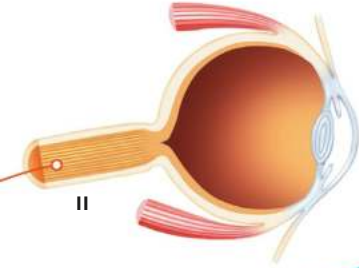
In this view of the underside of the brain, the pairs of cranial nerves are revealed as joining mainly to the lower regions of the brain. Some of these cranial nerves have a sensory function, taking impulses to

the brain. Others have a motor function, carrying nerve signals from the brain to various muscles and glands. Some cranial nerves are mixed, with both sensory and motor nerve fibres.

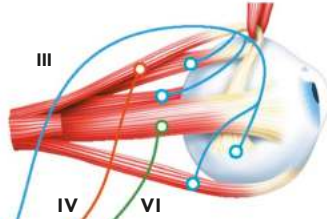


**Optic nerve (II, sensory)**

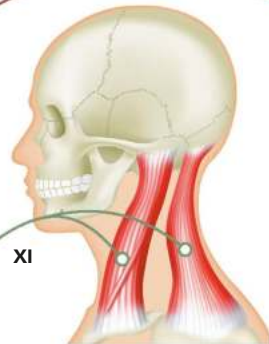
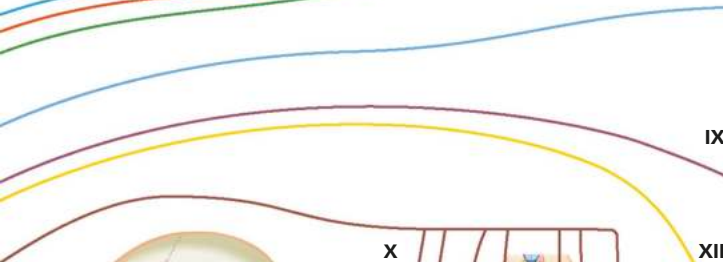
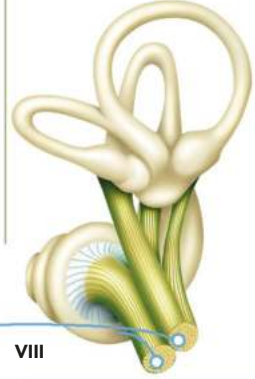
The optic nerve sends visual messages from the rod and cone cells in the retina of the eye to the visual cortex in the brain; parts of the two nerves cross at the optic chiasm (see p.122), where they form bands of nerve fibres, called optic tracts. Each nerve consists of a bundle of about one million sensory fibres – it carries the most information of any cranial nerve.

**Oculomotor, trochlear, and abducens nerves (III, IV, VI, mainly motor)**

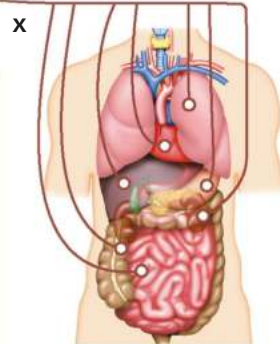
These three nerves regulate the voluntary movements of the eye muscles, to move the eyeball and eyelids; the oculomotor also controls pupil constriction by the iris muscles and focusing changes in the lens by the ciliary muscles.

**Vestibulocochlear nerve (VIII, sensory)**

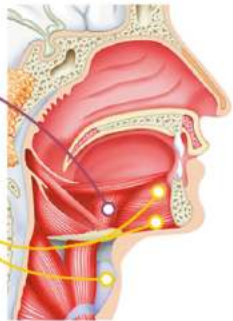
The vestibular branch sends nerve signals from the inner ear about head orientation and balance; the cochlear branch brings signals from the ear concerning sound and hearing.

**Spinal accessory nerve (XI, mainly motor)**

This nerve controls muscles and movements in the head, neck, and shoulders. It also stimulates the muscles of the pharynx and larynx, which are involved in swallowing.

**Vagus nerve (X, mixed)**

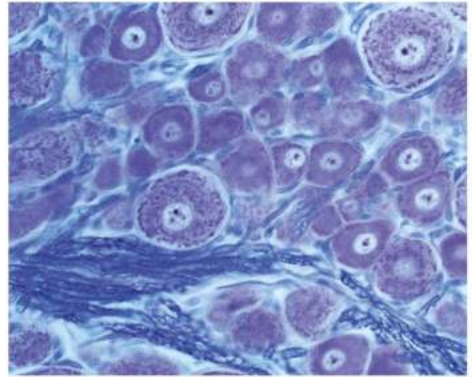
The longest and most branched cranial nerve, the vagus has sensory, motor, and autonomic fibres that pass to the lower head, throat, neck, chest, and abdomen; they are involved in many vital bodily functions, including swallowing, breathing, and heartbeat.

**Glossopharyngeal and hypoglossal nerves (IX, XII, both mixed)**

Motor fibres of these nerves are involved in tongue movement and swallowing, while sensory fibres relay information about taste, touch, and temperature from the tongue and pharynx.

## SPINAL NERVES

The 31 pairs of peripheral spinal nerves emerge from the spinal cord through spaces between the vertebrae (see p.99). Each nerve divides and subdivides into a number of branches; the dorsal branches serve the rear portion of the body, while the ventral branches serve the front and sides. The branches of one spinal nerve may join with other nerves to form meshes called plexuses, where nerves merge and intersect. Nerves leaving each plexus then go on to carry signals to and from that particular area of the body.



### SPINAL NERVE GANGLION

This microscope image shows a section through a cluster of spinal nerve cells (ganglion), where nerve impulses are coordinated. Each neuron (purple) is surrounded by support cells (light blue).

### Cervical region (C1–C8)

Eight pairs of cervical spinal nerves form two networks, the cervical (C1–C4) and brachial plexuses (C5–C8/T1). These run to the chest, head, neck, shoulders, arms, and hands, and to the diaphragm.

### Thoracic region (T1–T12)

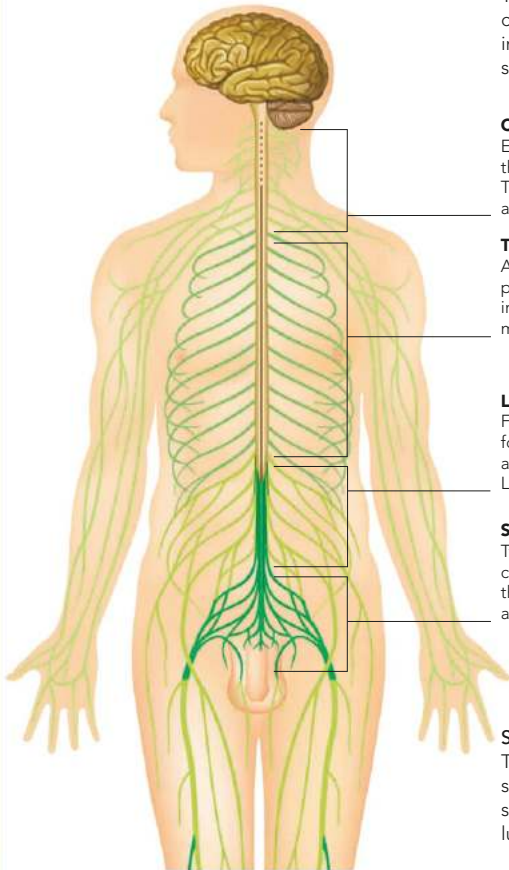
Apart from T1, which is considered part of the brachial plexus, thoracic spinal nerves are connected to the intercostal muscles between the ribs, the deep back muscles, and the abdominal muscles.

### Lumbar region (L1–L5)

Four of the five pairs of lumbar spinal nerves (L1–L4) form the lumbar plexus, which supplies the lower abdominal wall and parts of the thighs and legs. L4 and L5 interconnect with the first four sacral nerves (S1–S4).

### Sacral region (S1–S5)

Two nerve networks, the sacral plexus (L5–S3) and the coccygeal plexus (S4/S5/Co 1), send branches to the thighs, buttocks, muscles and skin of the legs and feet, and anal and genital areas.

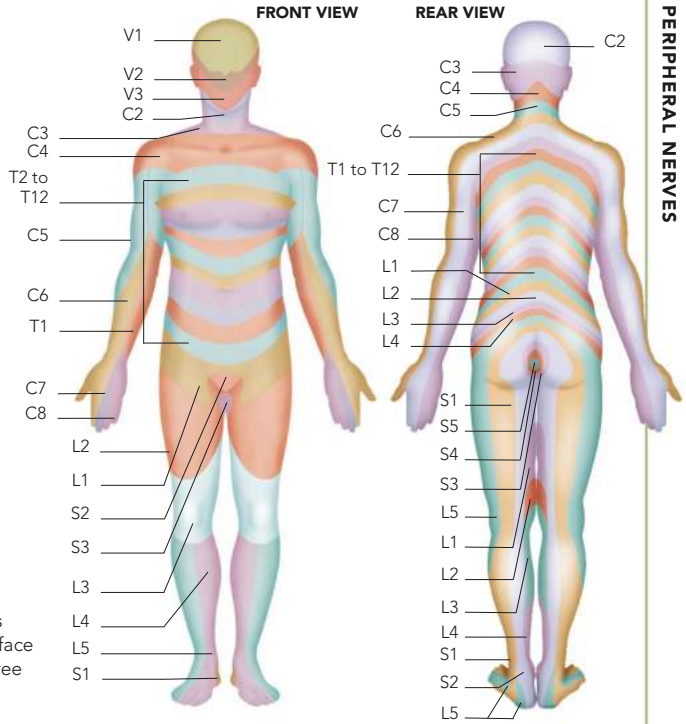


### SPINAL REGIONS

The organization and naming of the four main spinal nerve regions reflect the regions of the spine itself – cervical or neck, thoracic or chest, lumbar or lower back, and sacral or base of spine.

## DERMATOMES

A dermatome is a region or zone of skin supplied by the dorsal (rear, sensory) nerve roots of one pair of spinal nerves. The nerve branches carry sensory information about touch, pressure, heat, cold, and pain from the skin microsenors within the zone, along the sensory fibres of the spinal nerve, to the nerve root and then into the spinal cord. A "skin map" delineates these zones, or dermatomes. In real life, the distribution of nerve roots, and so of sensations, overlaps slightly.

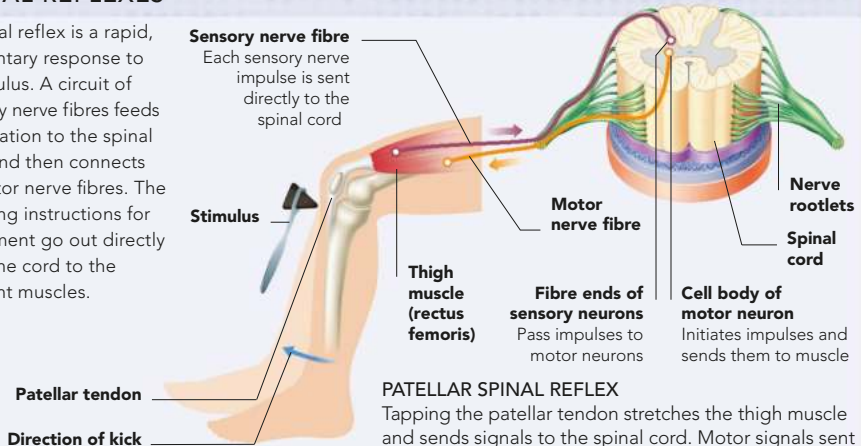


### DERMATOME MAP

Spinal nerve C1 has no sensory fibres from the skin, and so is omitted; the face and forehead send signals via the three branches of the trigeminal cranial (V) nerve, coded here as V1–V3.

## SPINAL REFLEXES

A spinal reflex is a rapid, involuntary response to a stimulus. A circuit of sensory nerve fibres feeds information to the spinal cord and then connects to motor nerve fibres. The resulting instructions for movement go out directly from the cord to the relevant muscles.



### PATELLAR SPINAL REFLEX

Tapping the patellar tendon stretches the thigh muscle and sends signals to the spinal cord. Motor signals sent back make the muscle contract, causing a slight kick.

# AUTONOMIC NERVOUS SYSTEM

THE AUTONOMIC NERVOUS SYSTEM (ANS) MAINTAINS CONSTANT CONDITIONS WITHIN THE BODY, A PROCESS KNOWN AS HOMEOSTASIS. MOST OF ITS ACTIVITY IS INDEPENDENT (AUTONOMIC) OF THE CONSCIOUS MIND.

## AUTOMATIC FUNCTIONS

The ANS shares some nerve structures with the central and peripheral nervous systems. It also has chains of ganglia (clusters of nerves where axons communicate) either side of the spinal cord. The sensory information it collects about organs and internal activities are integrated by the hypothalamus, brainstem, or spinal cord. It sends motor signals to three main destinations: the involuntary smooth muscles of many organs and blood vessels; cardiac muscle; and certain glands.

Pupil dilates as outer muscle of iris contracts; lens focuses on distant objects as ciliary muscles relax

Salivary glands secrete thick, viscous saliva

Trachea kept open

Bronchial tubes dilate

Lung blood vessels dilate (widen)

Heart rate and force of contraction increase

Adrenal gland produces stress hormones

Blood vessels in skin constrict, turning it pale; hairs stand on end; sweat gland secretion rises

Liver releases glucose

Kidney

decreases urine

output

Stomach

produces less of the digestive

enzymes

Intestine slows

its movement of food

Bladder

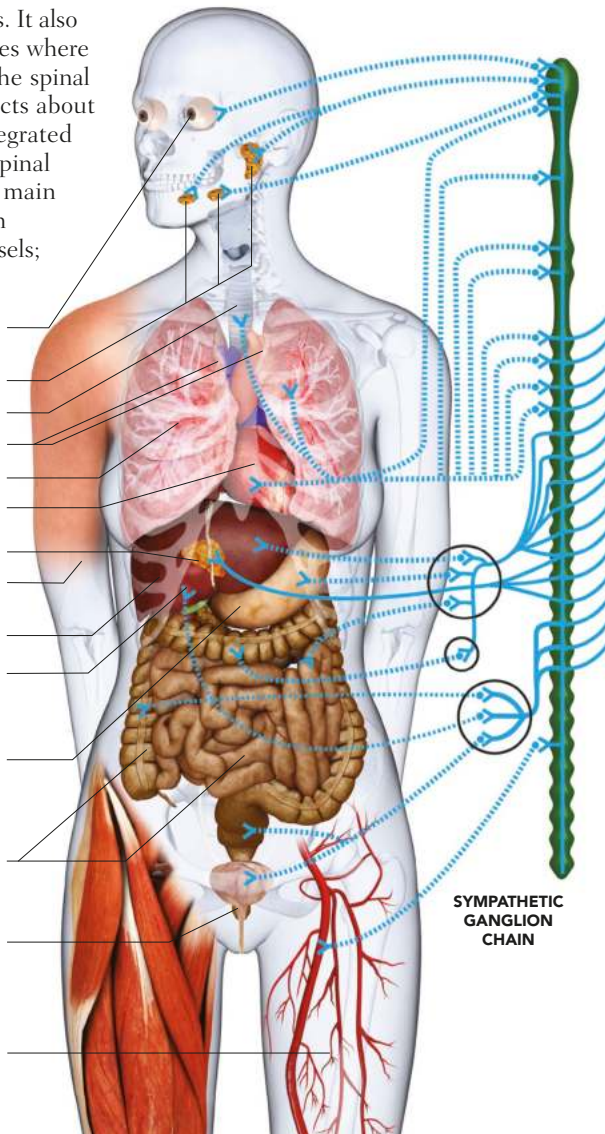
sphincter muscle constricts

Blood vessels dilate

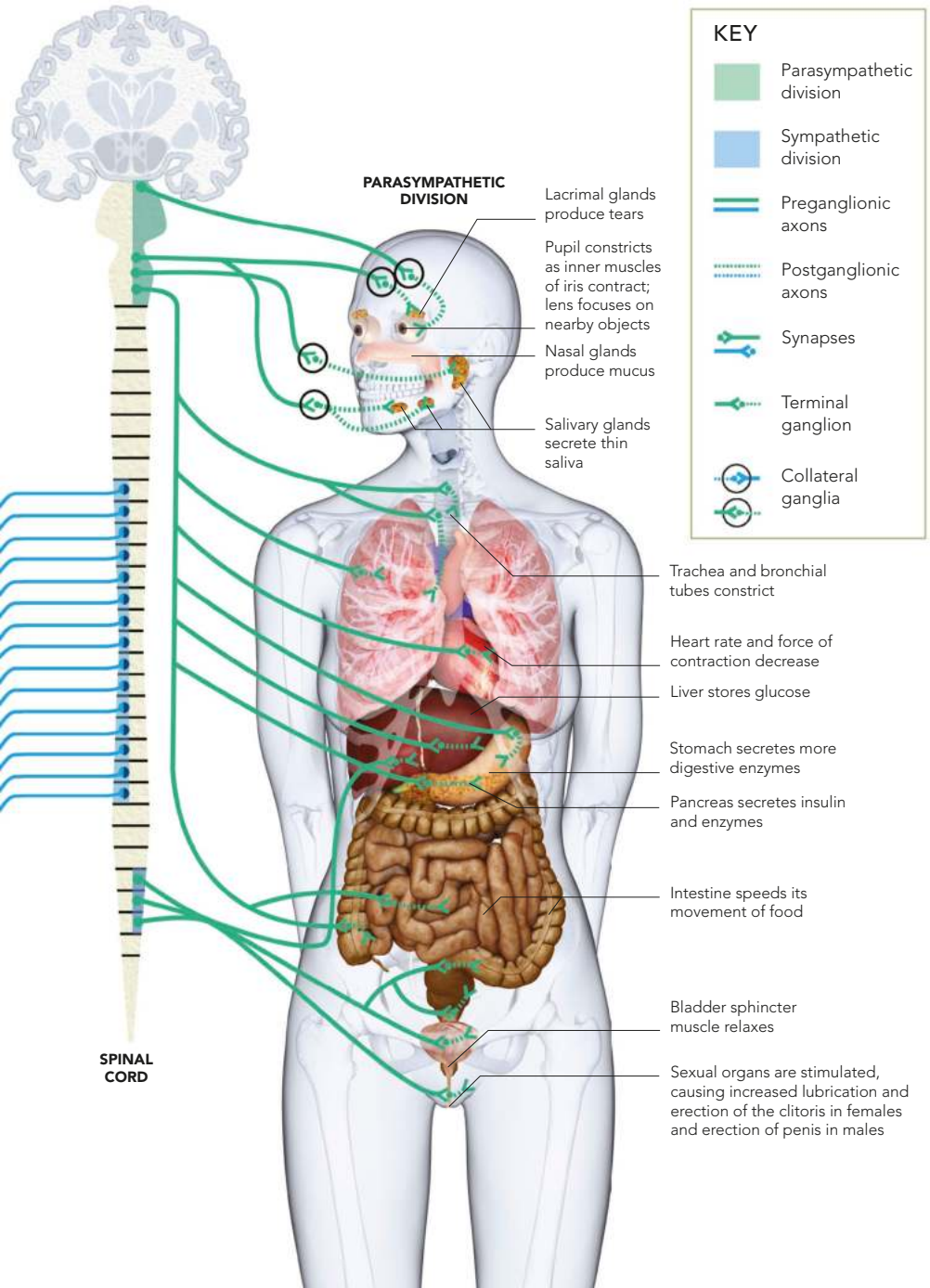
## TWO DIVISIONS

There are two divisions in the ANS: the sympathetic and parasympathetic. The ganglia of the sympathetic division are arranged into two ganglion chains, one either side of the spinal column (only one is shown here). The ganglia of the parasympathetic ANS are inside organs (see diagram). Only skin and blood vessels receive nerve messages from all positions on the cord.

**SYMPATHETIC DIVISION**



**SYMPATHETIC GANGLION CHAIN**



KEY

- Parasympathetic division
- Sympathetic division
- Preganglionic axons
- Postganglionic axons
- Synapses
- Terminal ganglion
- Collateral ganglia

PARASYMPATHETIC DIVISION

Lacrimal glands produce tears

Pupil constricts as inner muscles of iris contract; lens focuses on nearby objects

Nasal glands produce mucus

Salivary glands secrete thin saliva

Trachea and bronchial tubes constrict

Heart rate and force of contraction decrease

Liver stores glucose

Stomach secretes more digestive enzymes

Pancreas secretes insulin and enzymes

Intestine speeds its movement of food

Bladder sphincter muscle relaxes

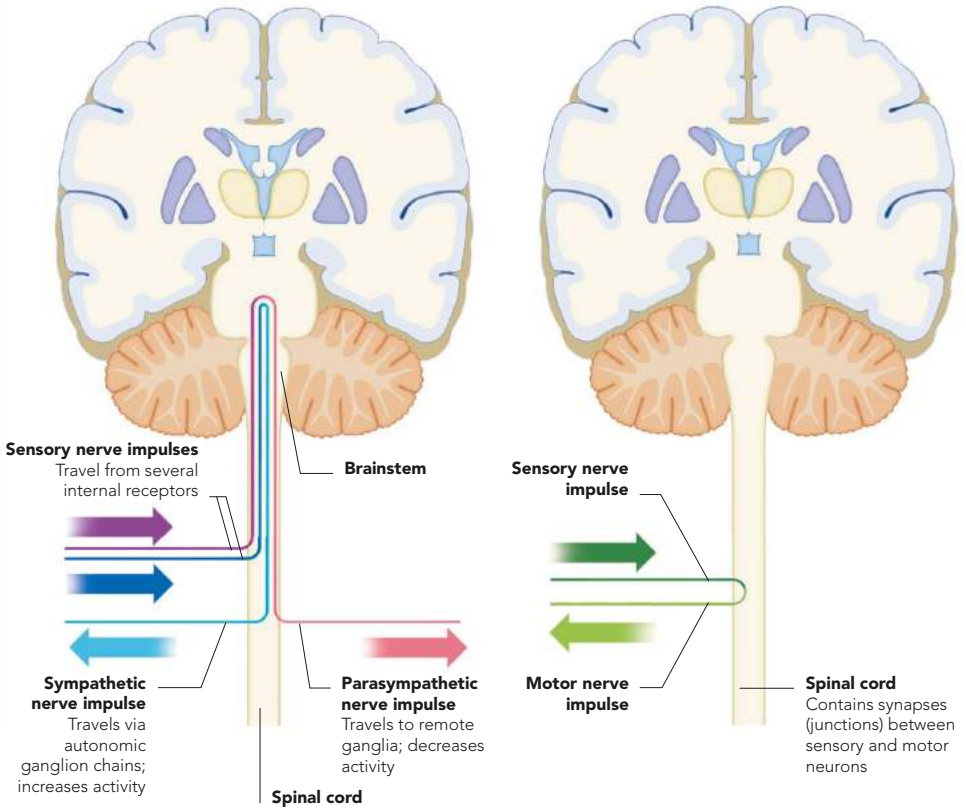
Sexual organs are stimulated, causing increased lubrication and erection of the clitoris in females and erection of penis in males

SPINAL CORD

## INVOLUNTARY RESPONSES

There are two main types of involuntary, or automatic, responses, which do not usually involve conscious awareness. One involves reflex actions (see p.105). Reflexes mainly affect muscles normally under voluntary control. The other type of response includes autonomic motor actions. The initial nerve pathways for these responses run along spinal nerves into the spinal cord, then up ascending

nerve tracts to the lower autonomic regions of the brain, particularly parts of the limbic system and the hypothalamus. These regions analyse and process the information received, and then use the autonomic pathways to send out motor impulses, as instructions for the involuntary muscles and the glands. Response signals for the parasympathetic and sympathetic systems have separate pathways.



### AUTONOMIC RESPONSES

Nerve signals pass along spinal nerves and up the spinal cord to the lower autonomic regions of the brain, which output motor impulses in response.

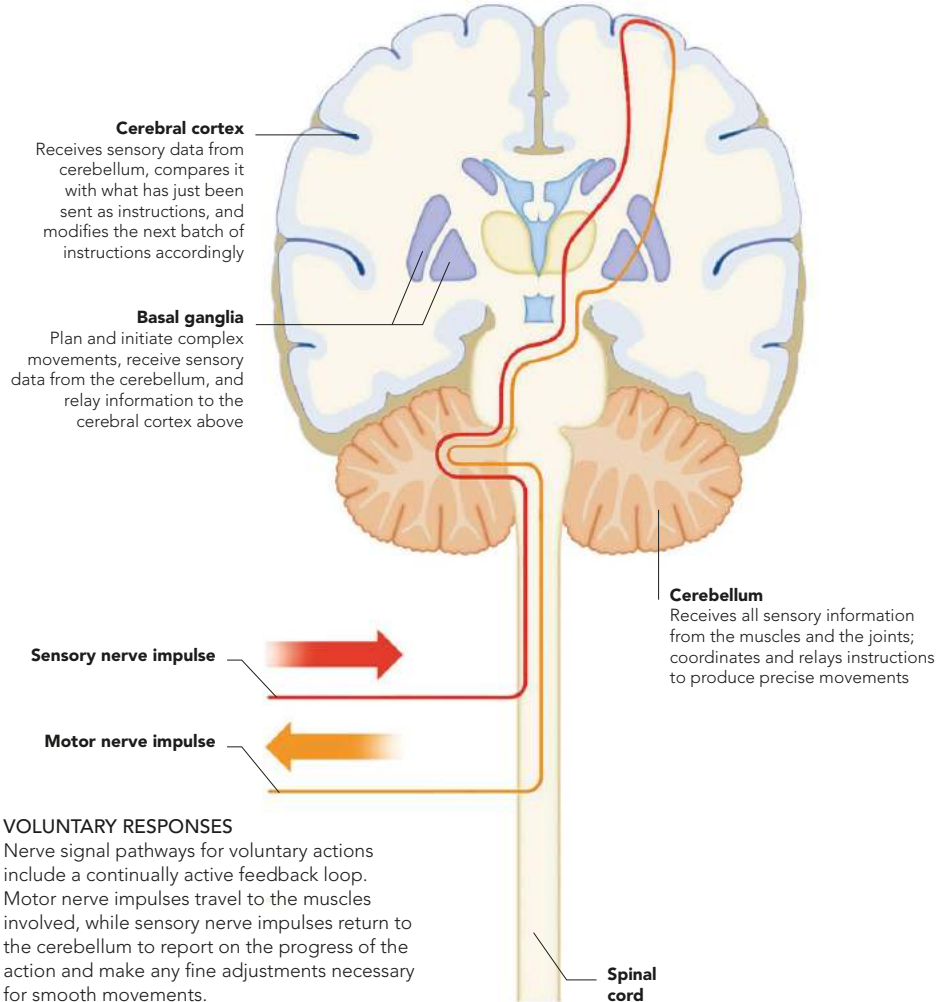
### REFLEXES

Sensory signals arrive, and motor signals depart, wholly within the spinal cord, and without the involvement of the brain – although the brain becomes aware soon afterward.

## RESPONSES UNDER VOLUNTARY CONTROL

Nervous responses under voluntary control are the opposite of reactions controlled by the ANS. Stimulated by incoming sensory nerve messages, or by conscious thought and intention, the brain's cerebral cortex formulates a central motor plan for a particular movement, and sends out instructions

as motor nerve signals to voluntary muscles. As the movement progresses, it is monitored by sensory endings in the muscles, tendons, and joints. The sensory endings update the cerebellum, so that the cerebral cortex can send corrective nerve signals back to the muscles in order to keep the movement coordinated and on course.



# MEMORIES, THOUGHTS, AND EMOTIONS

MANY MENTAL FACULTIES ARE NOT CONTROLLED BY JUST ONE AREA OF THE BRAIN. FOR EXAMPLE, THERE IS NO SINGLE "MEMORY CENTRE". THOUGHTS, FEELINGS, EMOTIONS, AWARENESS, AND MEMORY INVOLVE MANY PARTS OF THE BRAIN.

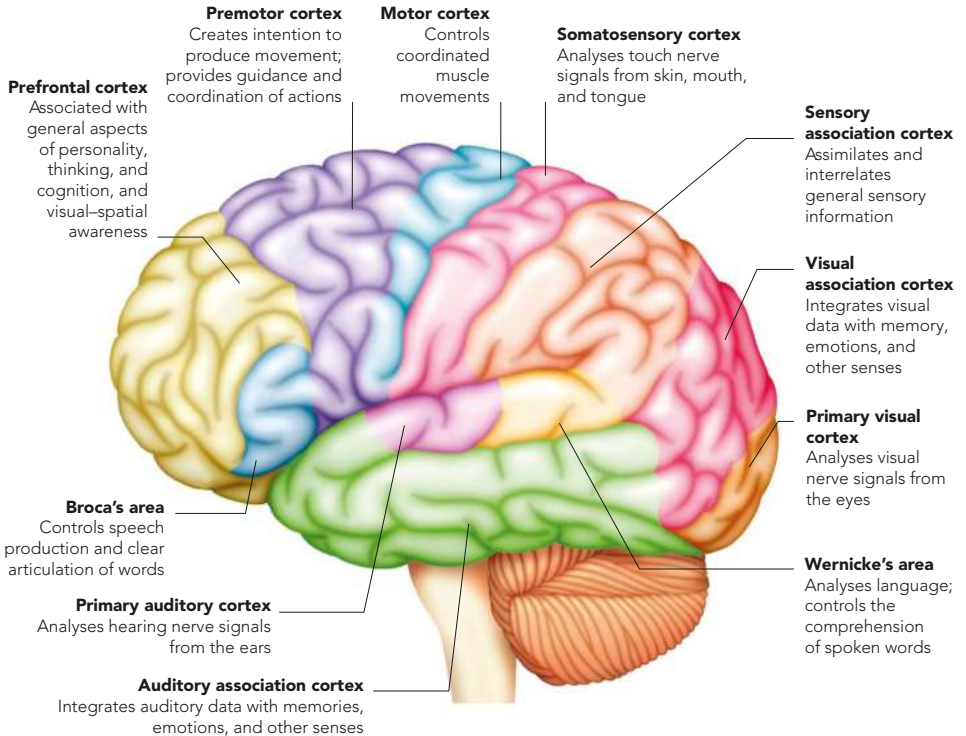
## MAP OF THE CORTEX

Certain regions of the brain's cortex are called primary sensory areas. Each of these receives sensory information from a specific sense. The primary visual cortex, for instance, analyses data from the eyes. Around each region are association areas, where data from the specific sense is integrated with data from other senses, compared with memories and knowledge, and associated with feelings and emotions. In this way, seeing a particular scene

allows us to recognize, identify, and name the objects in it, remember where we saw them previously, recall related sensory data, such as a certain smell, and experience associated emotions again.

## CENTRES OF ACTIVITY

Certain areas of the cortex carry out specific brain functions, while others are more generalized. No areas have been identified as exact sites of consciousness or learning.

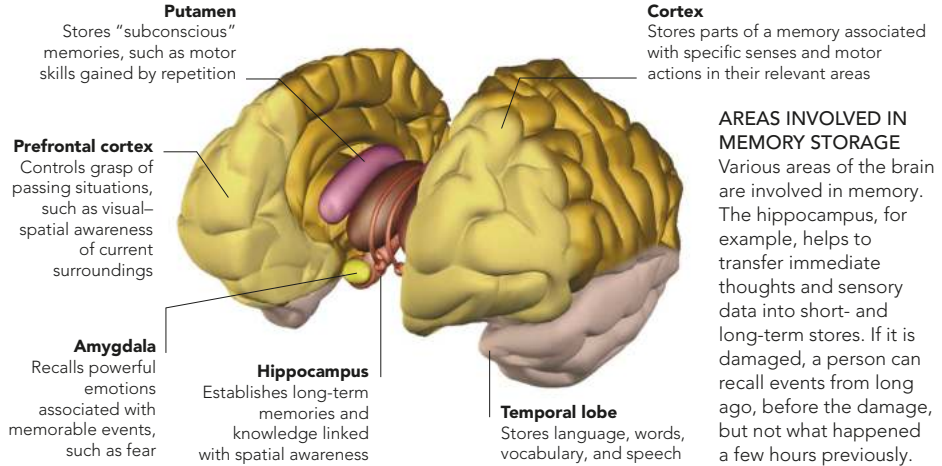




## MEMORY AND RECALL

Memories are the brain's information store. No single region of the brain processes them as they are being established, nor acts as a storage site for all memories.

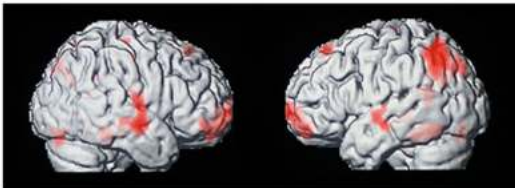
These processes depend on the significance and time span of the memory, its depth of emotional impact, and its association with specific senses such as eyesight.



## THOUGHT IN ACTION

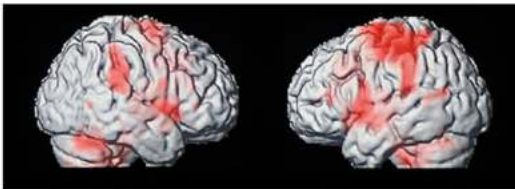
The real-time scanning method fMRI (functional magnetic resonance imaging) reveals tiny localized increases in blood flow. As a result, the scans can pinpoint

which areas of the brain are busy during well-defined mental activities, such as studying the visual details of an image, or listening to and understanding speech.



RIGHT SIDE OF BRAIN

LEFT SIDE OF BRAIN



RIGHT SIDE OF BRAIN

LEFT SIDE OF BRAIN

### PLANNING A MOVEMENT

The subject of this fMRI scan was asked to think about performing a task during the scan. The image shows activity in both the left and right prefrontal areas and also in both the left and right auditory cortex.

### MAKING THAT MOVEMENT

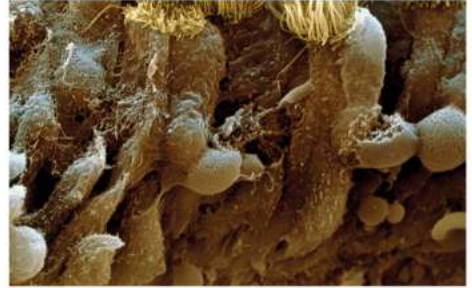
When actually performing the task, large parts of the premotor and motor cortex show up on the brain's left side. The cerebellum (at the base of the brain) helps to control precise muscle coordination.

# SMELL, TASTE, AND TOUCH

RECEPTORS THAT SENSE PRESSURE, PAIN, AND TEMPERATURE ARE WIDESPREAD IN THE BODY. TASTE AND SMELL, IN CONTRAST, ARE "SPECIAL SENSES" BECAUSE THEIR RECEPTORS ARE COMPLEX AND LOCALIZED, AND DETECT SPECIFIC STIMULI.

## SMELL

Smell is a sense that can detect chemical molecules known as odorants floating in the air. Specialized epithelial tissue provides a smelling zone, known as the olfactory epithelium, on the roof of the nasal cavity. In humans, smell is more sensitive than taste and may be able to distinguish millions of odours. Smell is important for warning of dangers, such as smoke and poisonous gas, and for appreciating food and drink. The sense of smell tends to deteriorate with age, so young people are able to distinguish a wider range of odours and experience them more vividly than older people.

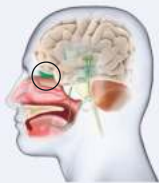

### NASAL LINING

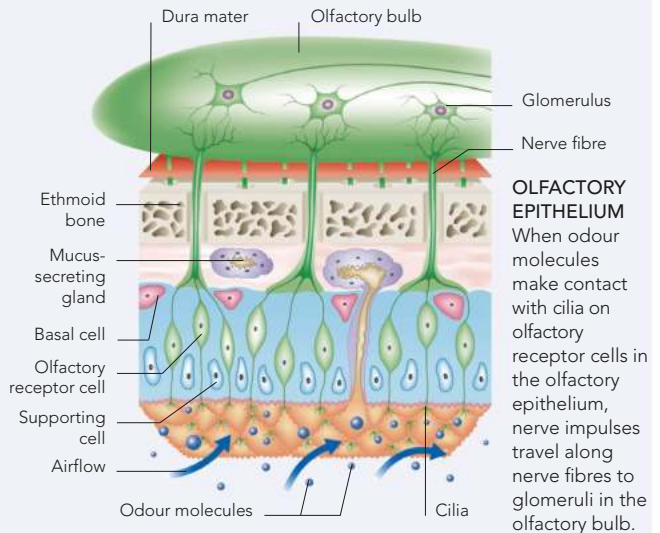
Epithelial cells in the lining of the nasal chamber have tufts of hair-like cilia, which wave germ- and odorant-trapping mucus towards the back of the chamber to be swallowed.

## HOW WE SMELL

Odour molecules dissolve in the mucus lining the nasal chamber. In the roof of the chamber, they touch the cilia (microscopic, hair-like endings of olfactory receptor cells). If the correct molecule slots into the same-shaped receptor on the ciliary membrane, like a key in a lock, a nerve impulse is generated. The impulses are partly processed by intermediate neurons called glomeruli in the olfactory bulb.

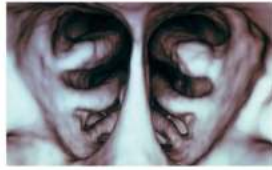

LOCATION

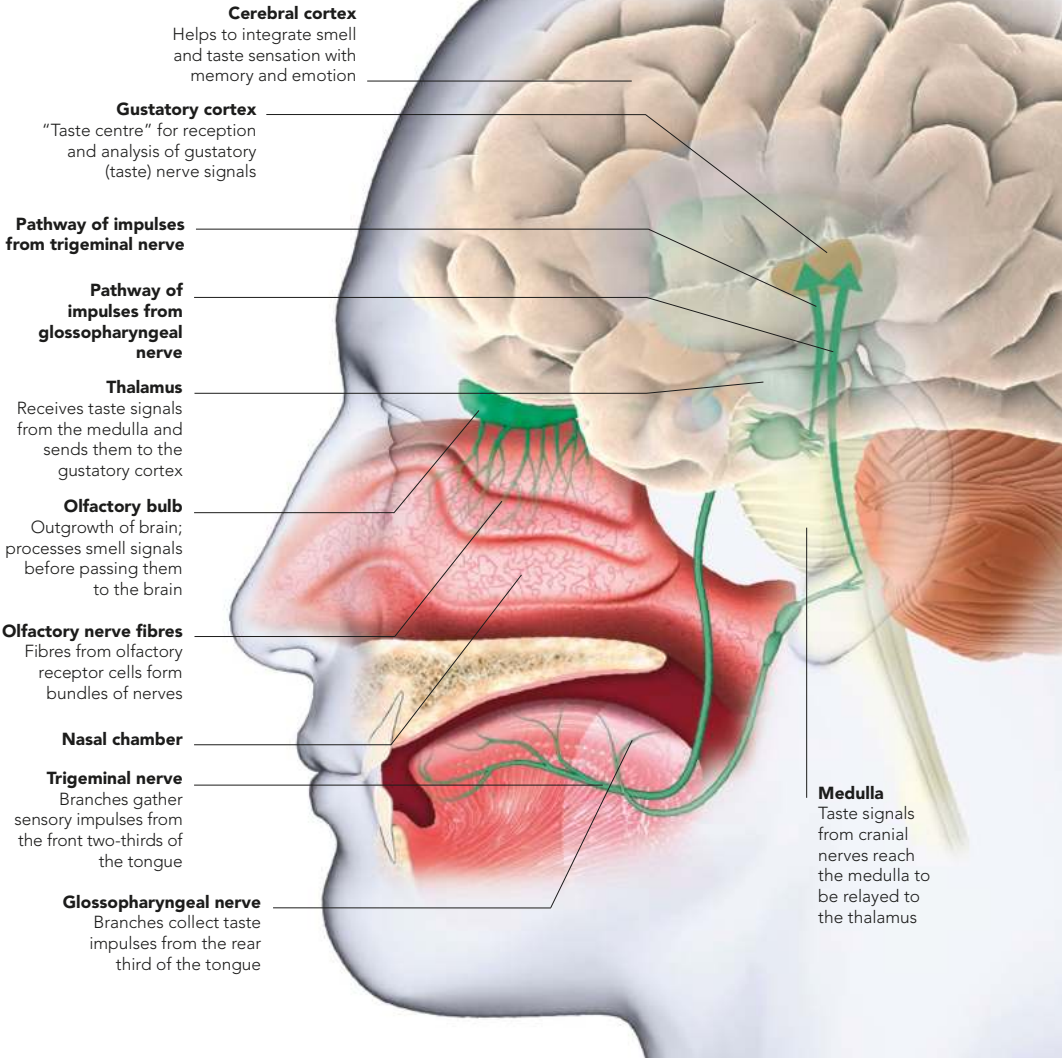


# NERVE PATHWAYS FOR SMELL AND TASTE

Both smell (olfactory) and taste (gustatory) sensations pass along cranial nerves directly to the brain. Smell signals travel from the olfactory bulbs along the olfactory nerve, which is made up of groups of nerve fibres, to a patch of the cortex located in the temporal lobe. Taste sensations travel along branches of the glossopharyngeal and facial nerves to the gustatory centre in the cortex.



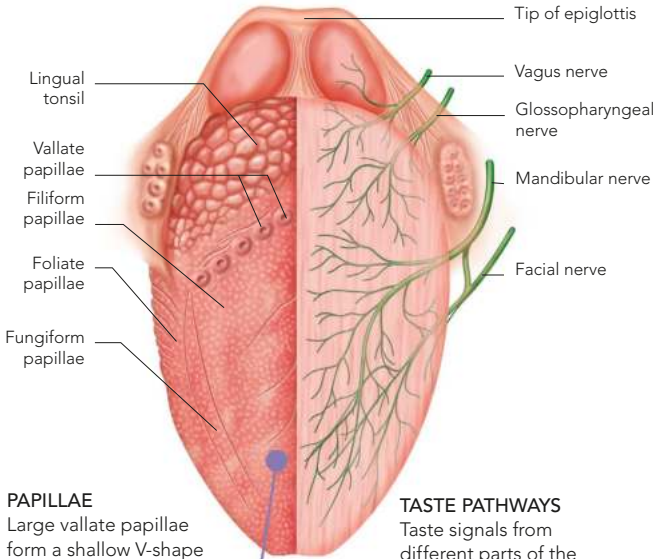
**NASAL CHAMBER**  
A 3-D CT scan shows the three shelves of bone known as the conchae on both sides of the nasal chamber.



## TASTE

Taste works in a similar way to smell. Its gustatory cell (taste) receptors detect specific chemicals dissolved in saliva by a “lock-and-key” method (see p.112). Groups of receptor cells are known as taste buds. A child has about 10,000 taste

buds, but with age, their numbers may fall to under 5,000. They are located mainly on and between the pimple-like papillae that dot regions of the tongue’s upper surface. There are also some taste buds on the palate (roof of the mouth), throat, and epiglottis.



## TASTE BUDS

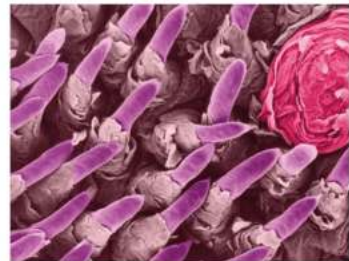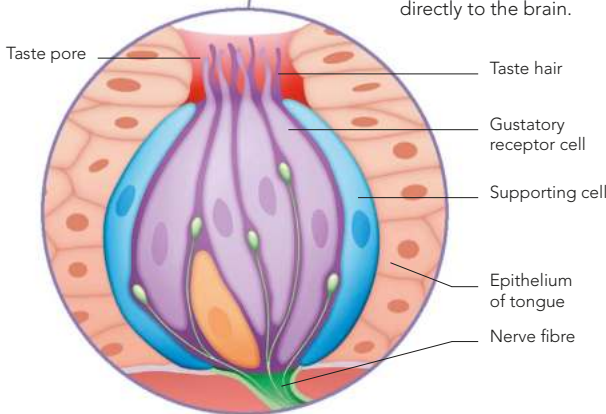
Each taste bud is structured much like an orange whose “segments” consist of roughly 25 “gustatory” receptor cells and numerous supporting cells. The receptor cells have hair-like tips that project into a hole (the taste pore) in the tongue’s surface. Their nerve fibres gather at the bud base.

### PAPILLAE

Large vallate papillae form a shallow V-shape at the rear of the tongue; the fungiform and filiform papillae are much smaller.

### TASTE PATHWAYS

Taste signals from different parts of the tongue are conveyed by branches of three of the cranial nerves directly to the brain.



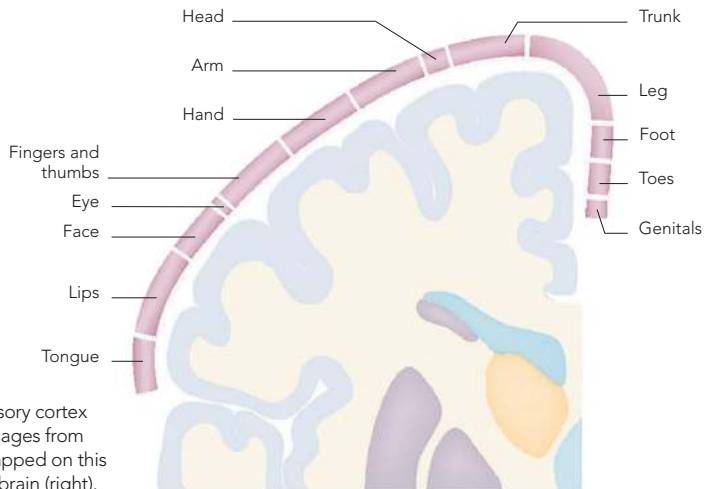
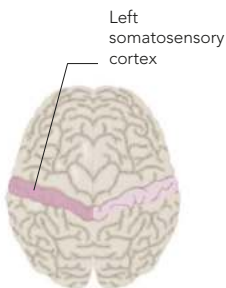
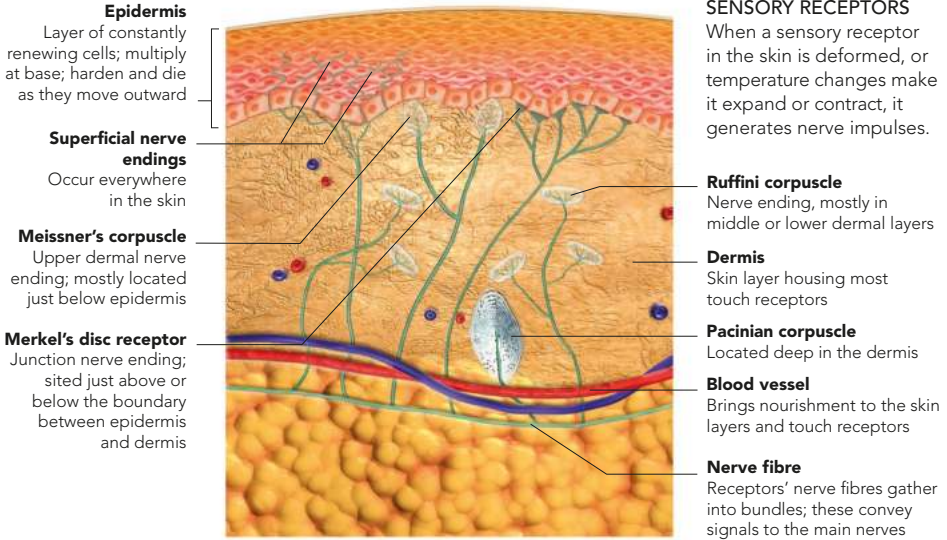
### TASTE RECEPTORS

A scanning electron microscope image shows two different types of papillae. The purple conical structures are filiform papillae. The circular pink structure is a fungiform papilla.

## TOUCH

The sense of touch comes from microscopic sensory receptors (specialized endings of nerve cells) in the skin or in deeper tissues (see p.182). Some receptors are enclosed in capsules of connective tissue, while others are uncovered. Different shapes and sizes

of receptors detect a range of stimuli, such as light touch, heat, cold, pressure, and pain. The receptors relay their signals via the spinal cord and lower brain to a strip curving around the cerebral cortex, known as the somatosensory cortex, or “touch centre”.



### TOUCH MAP

Each part of the somatosensory cortex (above) receives touch messages from skin around the body, as mapped on this vertical cross-section of the brain (right).

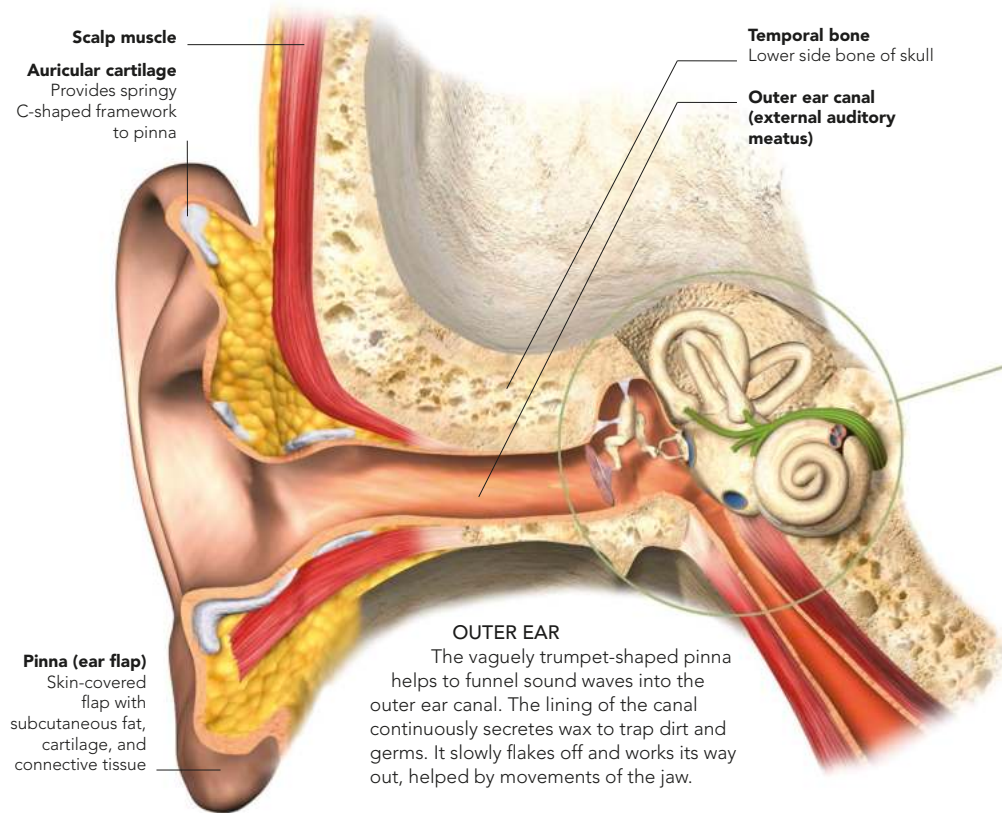
# EARS, HEARING, AND BALANCE

THE EARS PROVIDE THE SENSE OF HEARING. THEY ALSO DETECT HEAD POSITION AND MOTION, SO ARE ESSENTIAL TO BALANCE. THE FUNCTION OF BOTH HEARING AND BALANCE IS BASED ON THE ACTIVITY OF "HAIR CELL" RECEPTORS.

## INSIDE THE EAR

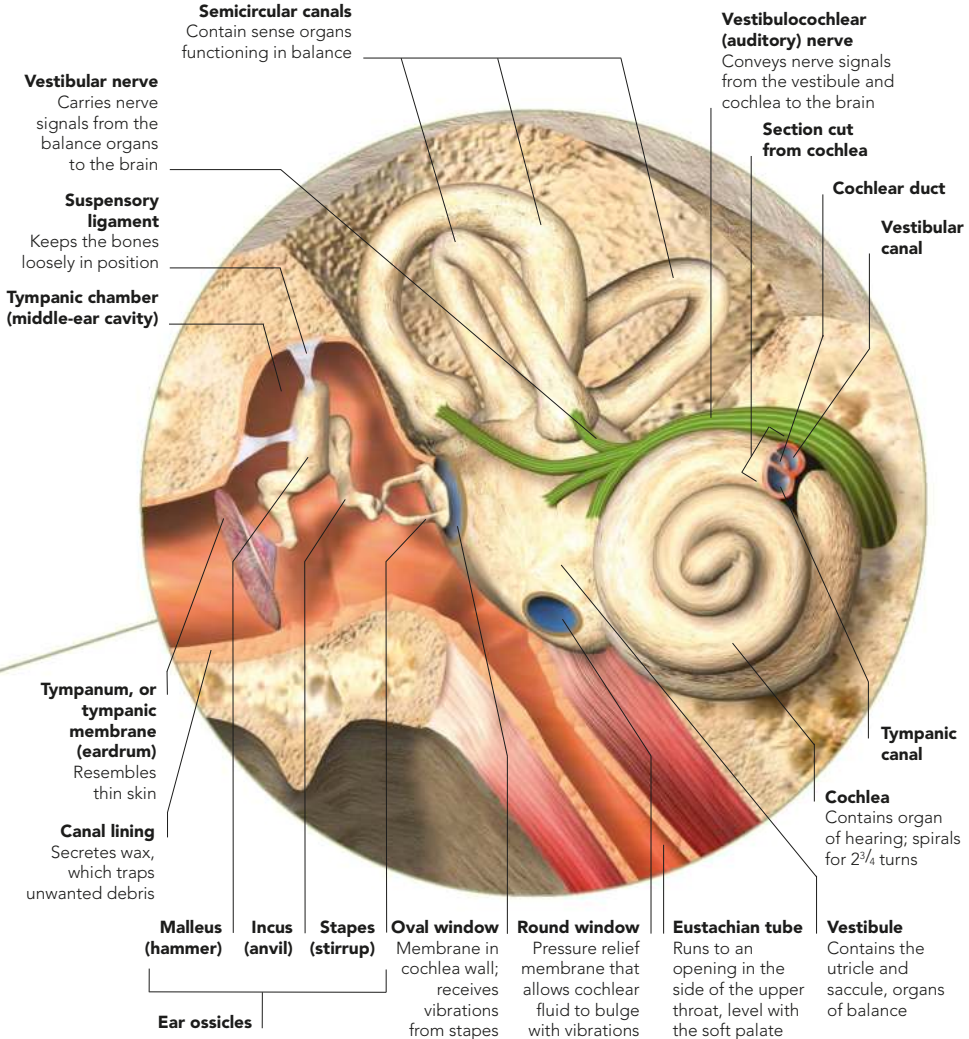
The ear is divided into three parts. The outer ear comprises the ear flap and the slightly S-shaped outer ear canal, which guides sound waves to the second region, the middle ear. The elements of the middle ear amplify the sound waves and transfer them from the air into the fluid of the inner ear. They include the eardrum and the three smallest bones in the body: the auditory ossicles, which span the

air-filled cavity of the middle ear. The fluid-filled inner ear changes sound waves to nerve signals inside the snail-shaped cochlea. The middle-ear cavity connects to the throat via the Eustachian tube, and so to the air outside. This connection allows atmospheric pressure to transfer to the cavity, equalizing the air pressure on either side of the eardrum and preventing it from bulging as the outside pressure changes.



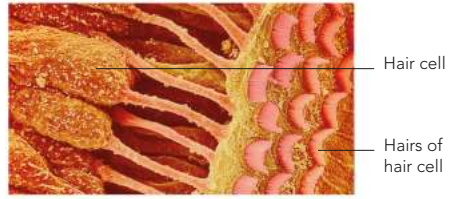
## MIDDLE AND INNER EAR

The ossicles of the middle ear are positioned and connected by miniature ligaments, tendons, and joints, just like larger bones. The cochlea, semicircular canals, and vestibule of the inner ear are linked. They are all filled with fluid, and are encased and protected within the thickness of the skull's temporal bone. They occupy a complex series of tunnels and chambers known as the osseous labyrinth.



## HOW WE HEAR

Ears act as energy converters, changing pressure differences in air, known as sound waves, into electrochemical nerve impulses. Sound waves usually occur as a complex pattern of frequencies, and they vibrate the eardrum in the same pattern. The vibrations are conducted along the ossicle chain, which rocks like a bent lever and forces the footplate of the stapes to act like a piston, pushing and pulling at the flexible oval window of the cochlea. The motions set off waves through the perilymph fluid inside the cochlea. These, in turn, transfer their vibrational energy to the organ of Corti, which coils within the cochlea.

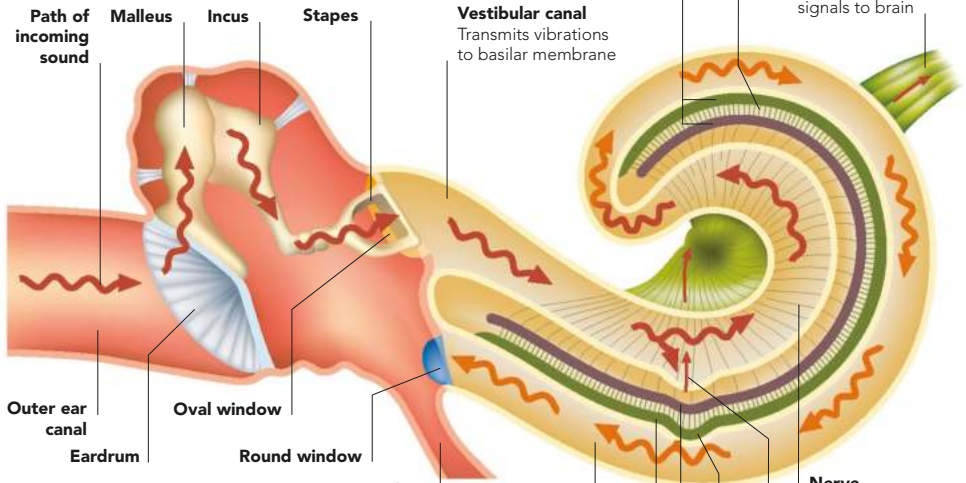


### HAIR CELLS

Within the organ of Corti, with the tectorial membrane removed on the right, each hair cell is seen to have 40–100 hairs arranged in a curve. Nerve fibres run from the cell bases.

**Organ of Corti**  
Central spiral element of the cochlea, composed of tectorial and basilar membranes linked by sensitive hair cells

**Hair cells**  
Generate nerve signals in response to motion of basilar and tectorial membranes



### VIBRATION TRANSFER

Vibrations travel from the oval window through the fluid in the vestibular canal to the organ of Corti. Here, hair cells on the basilar membrane vibrate, pulling the hairs and stimulating them to produce nerve impulses. These travel via the cochlear nerve to the auditory cortex in the brain for interpretation. Residual vibrations from the vestibular canal pass along the tympanic canal to the round window.

**Tympanic canal**  
Conveys residual vibrations returning to round window

**Tectorial membrane**  
Tips of hairs from hair cells embed in this membrane

**Basilar membrane**  
Supports the bases of hair cells and their nerve fibres

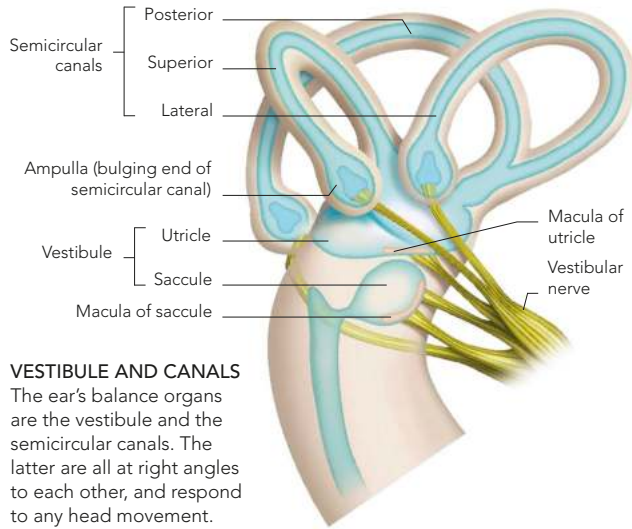
**Frequency response**  
Organ of Corti "shakes" at a particular point along its length, according to frequency of vibration

**Cochlear nerve**  
Carries nerve signals to brain



## THE PROCESS OF BALANCE

Balance involves analysing sensory inputs from the eyes, skin, and muscles, and then adjusting the body's position through motor outputs. The vestibule and semicircular canals of the inner ear play a key role, too. The vestibule responds mainly to the position of the head relative to gravity (static equilibrium), while the canals react chiefly to the speed and direction of head movements (dynamic equilibrium).

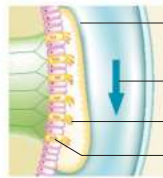
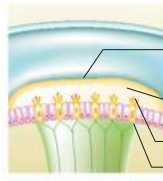


### VESTIBULE AND CANALS

The ear's balance organs are the vestibule and the semicircular canals. The latter are all at right angles to each other, and respond to any head movement.

### VESTIBULE

The vestibule's two parts, the utricle and saccule, each have a patch, the macula, containing hair cells. The tips of the cells extend into a membrane covered in heavy mineral crystals (otoliths). With the head level, the saccule's macula is vertical and the utricle's horizontal. As the head bends forward, the hair cells monitor the head's position in relation to the ground.

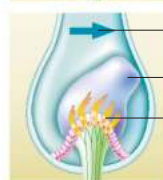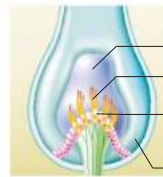

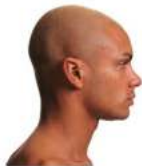
### MACULA ACTION

- Mineral crystals (otoliths) cover the membrane
- Otolithic membrane
- Hair of hair cell
- Hair cell
- Utricular macula rotated to vertical
- Gravity pulls membrane
- Hairs deflected
- Hair cell stimulated

### SEMICIRCULAR CANALS

Each semicircular canal has a bulge near one end, called the ampulla. This houses a low mound of hair cells, their hair ends set into a taller, jelly-like mound, the cupula. As the head moves, fluid in the canal lags behind, swirls past the cupula, and bends it. This pulls the hairs and triggers their cells to fire nerve signals.



### AMPULLA ACTION

- Cupula
- Hairs of hair cells
- Mound of hair cells (crista ampullaris)
- Ampulla
- Fluid swirls due to head motion
- Cupula bends
- Hair cells stimulated

# EYES AND VISION

EYESIGHT PROVIDES THE BRAIN WITH MORE INPUT THAN ALL OTHER SENSES COMBINED – MORE THAN HALF THE INFORMATION IN THE CONSCIOUS MIND IS ESTIMATED TO ENTER THROUGH THE EYES.

## THE SEQUENCE OF VISION

Light rays enter the eye through the clear, domed front of the eyeball, the cornea, where they are partly bent (refracted). They then pass through the transparent lens, which changes shape to focus them (see Accommodation, right) as an upside-down image onto the retina. The retina contains many millions of light-sensitive cells called rods and cones, which convert light energy into nerve signals. Rods are scattered through the retina and detect low levels of light. Cones are concentrated in the fovea and distinguish colours and fine details. The signals of the image are sent along the optic nerves of each eye to the visual cortex in the brain.

**Optic nerve**  
Conveys nerve signals to brain

**Lateral rectus**  
Small muscle that swivels the eye to look out to the side

## INSIDE THE EYE

An average eyeball is 25mm (1in) in diameter, and has three main outer layers: the sclera, choroid, and retina. Near the front, the sclera can be seen as the white of the eye, and at the front it becomes the clear cornea. The main bulk of the eye, between the lens and the retina, is filled with a clear, jelly-like fluid known as vitreous humour. This maintains the eyeball's spherical shape.

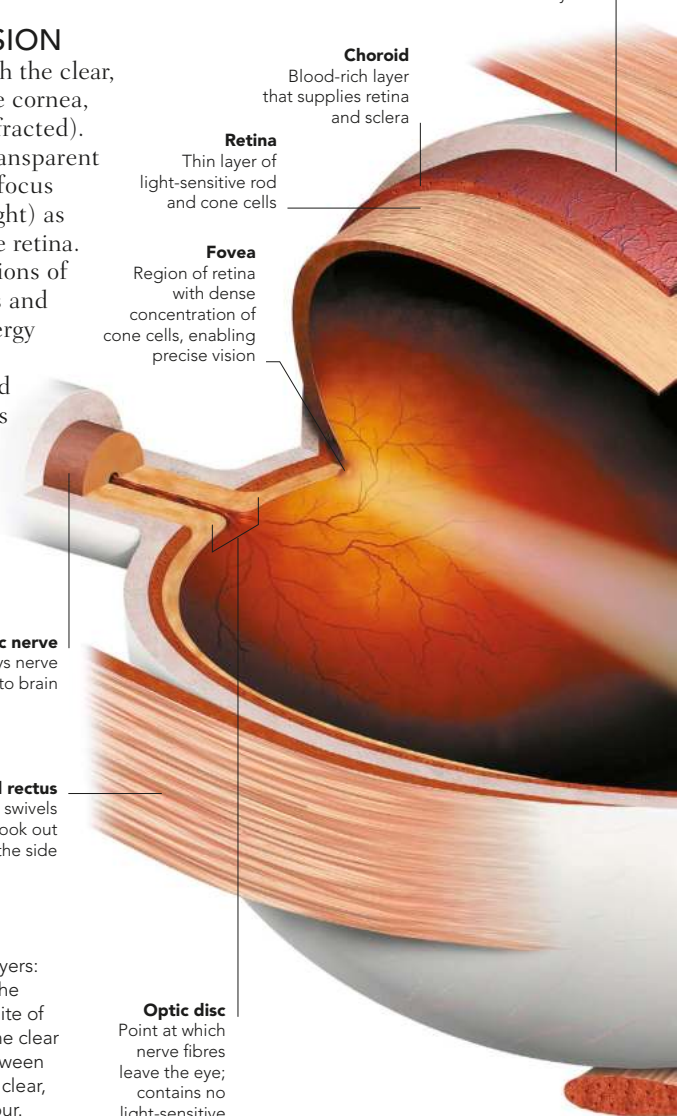
**Sclera**  
Tough, white, protective outer sheath of eyeball

**Choroid**  
Blood-rich layer that supplies retina and sclera

**Retina**  
Thin layer of light-sensitive rod and cone cells

**Fovea**  
Region of retina with dense concentration of cone cells, enabling precise vision

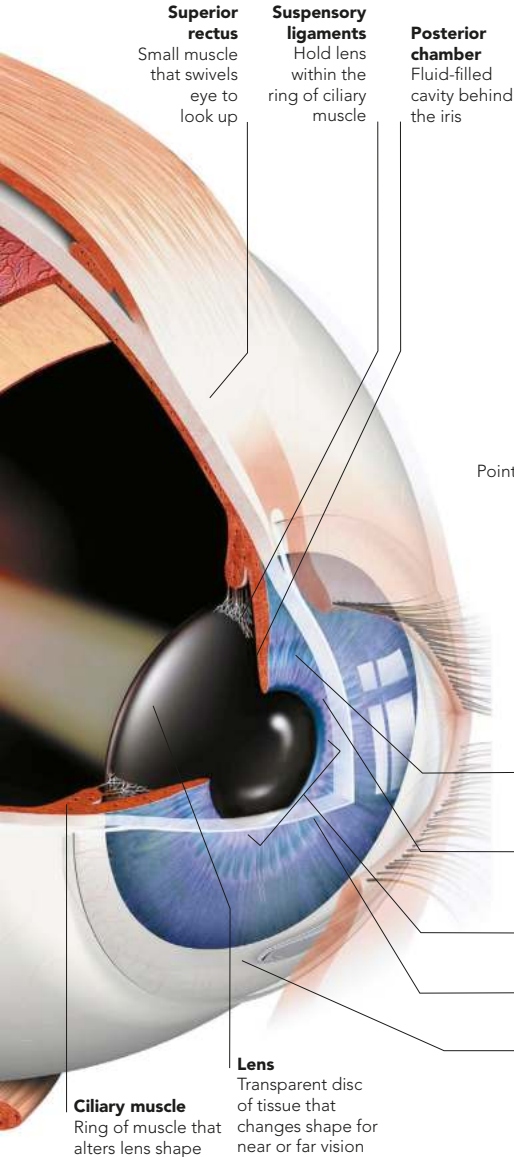
**Optic disc**  
Point at which nerve fibres leave the eye; contains no light-sensitive cells



## ACCOMMODATION

Most of the eye's focusing power comes from the cornea, but the lens alters in shape to fine-focus light rays, a process known as accommodation. To focus on nearby objects, the ring-shaped ciliary muscle around the lens contracts, making the lens thicker.

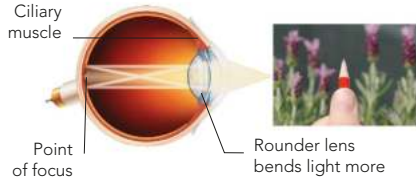
To focus on more distant objects, the muscle relaxes, making the lens flatter and thinner.



**Superior rectus**  
Small muscle that swivels eye to look up

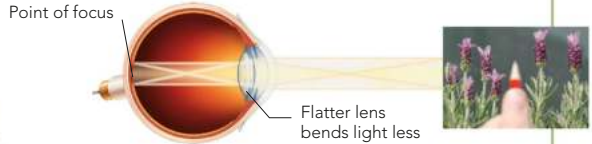
**Suspensory ligaments**  
Hold lens within the ring of ciliary muscle

**Posterior chamber**  
Fluid-filled cavity behind the iris



### NEAR VISION

Light rays from close objects diverge more, and so need the extra focusing power of a fatter lens to bend the light rays so that they converge.



### DISTANT VISION

Light rays from distant objects are almost parallel and require less refracting power to focus, so the ciliary muscle relaxes to make the lens bulge less.

**Iris**  
Ring of muscle that changes size of pupil to regulate amount of light entering the eye

**Anterior chamber**  
Between cornea and iris, filled with aqueous humour (fluid)

**Pupil**  
Hole in iris that becomes wider in dim light

**Cornea**  
Domed, transparent "window" at front of eye

**Conjunctiva**  
Delicate, sensitive covering of cornea and eyelid lining

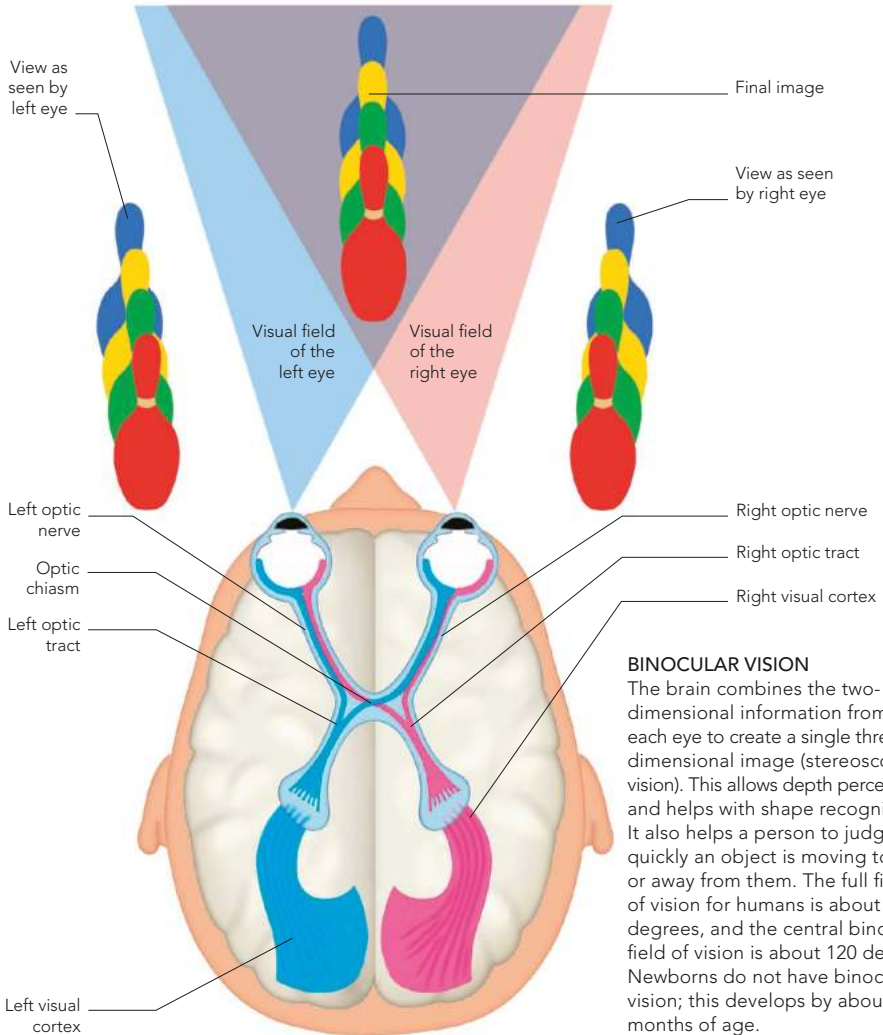
**Ciliary muscle**  
Ring of muscle that alters lens shape

**Lens**  
Transparent disc of tissue that changes shape for near or far vision

## VISUAL PATHWAYS

Nerve signals conducted along the left and right optic nerves converge at a crossover junction, called the optic chiasm, at the base of the brain. Here, fibres carrying signals from the left side of each retina join and proceed as the left optic tract to the left visual cortex at the back of the

brain. Likewise fibres from the right side of each retina form the right optic tract and go to the right visual cortex. Because the eyes are set apart, each sees a slightly different view of an object. The combination of the views of both eyes into a single image is called binocular vision.



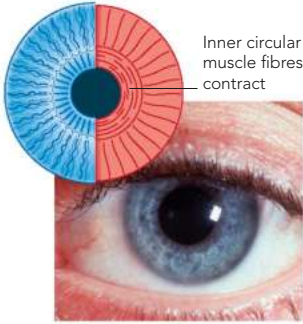
### BINOCULAR VISION

The brain combines the two-dimensional information from each eye to create a single three-dimensional image (stereoscopic vision). This allows depth perception and helps with shape recognition. It also helps a person to judge how quickly an object is moving towards or away from them. The full field of vision for humans is about 180 degrees, and the central binocular field of vision is about 120 degrees. Newborns do not have binocular vision; this develops by about four months of age.

## PUPILS

The size of the pupils constantly changes in response to changing levels of light. This is a function of the autonomic nervous system (see pp.106–07). Smooth muscle fibres in the iris are arranged as

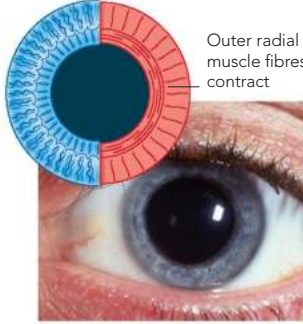
an inner, circular band and an outer, radial band. Sensory receptors in the eyes respond to light and send nerve signals to the brain, which sends messages to one or the other muscle band to adjust pupil size.



Inner circular muscle fibres contract

### CONSTRICTED PUPIL

In bright light or to view nearby objects, the pupil constricts as the parasympathetic nervous system stimulates the inner circular muscle fibres to contract.



Outer radial muscle fibres contract

### DILATED PUPIL

When light is dim and the eye needs more light to see, the pupil widens as the sympathetic nervous system causes the outer radial muscle fibres to shorten.

## AROUND THE EYE

When it closes, the eyelid physically protects the eye and smears lacrimal fluid, or tears, over the conjunctiva. Tears wash away dirt and dust and protect against microbes. Around the eyeball, there are six small,

strap-like muscles that attach it to the socket (orbit) in the skull bone. These extraocular or extrinsic muscles are very fast-acting and swivel, or roll, the eyeball so the eye can look up or down, inward or out.

### Lacrimal ducts

5–10 ducts convey fluid to the surface of the eye

### Lacrimal gland

Secretes tears to keep eye clean and moist

### Lacrimal canals

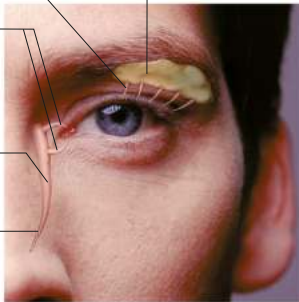Collect tears draining through small holes in the corner of the eye

### Lacrimal sac

Channels tears towards nose

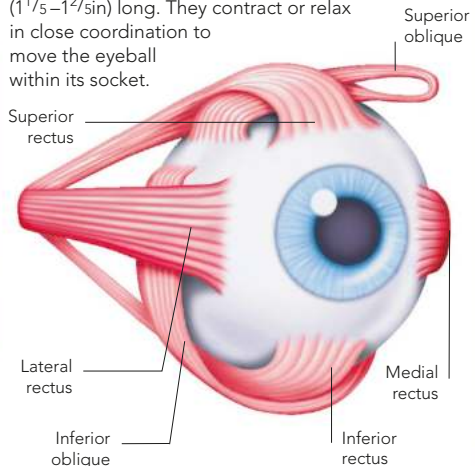
### Nasolacrimal duct

Opens into nasal cavity



## EYE MUSCLES OF RIGHT EYE

The six extrinsic muscles are 30–35mm ( $1\frac{1}{5}$ – $1\frac{2}{5}$ in) long. They contract or relax in close coordination to move the eyeball within its socket.



## TEAR APPARATUS

The tear (lacrimal) gland is under the soft tissues of the outer part of the upper eyelid. It produces 1–2ml ( $\frac{1}{3}$ – $\frac{2}{5}$ fl oz) of fluid daily.

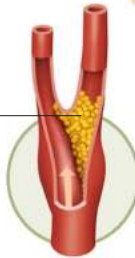
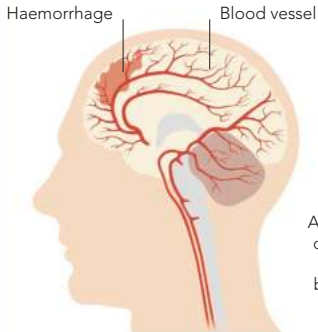
# NERVOUS SYSTEM DISORDERS

DISORDERS OF THE NERVOUS SYSTEM CAN DEVELOP FOR VARIOUS REASONS, SUCH AS PROBLEMS WITH THE BRAIN'S BLOOD SUPPLY, THE DETERIORATION OF BRAIN CELLS, ABNORMAL DEVELOPMENT IN THE WOMB, TISSUE INFECTION, CELL DAMAGE, AND THE AGEING PROCESS.

## STROKE

Disruption of blood supply to nerve cells in the brain results in a temporary or permanent loss of function of the body parts they serve. In most people, symptoms of stroke develop rapidly, and may include weakness or numbness on one side of the body, visual disturbances, slurred speech, and difficulty maintaining balance. Immediate admission to hospital is essential to try to prevent brain damage. Long-term treatment to reduce the risk of further strokes usually consists of drugs. Rehabilitation, such as physiotherapy and speech therapy, are often needed. The after-effects of a stroke range from mild, temporary symptoms to lifelong disability.

**Thrombus**  
Fat deposits in artery walls reduce flow and may encourage a blood clot, or thrombus, to form; if this blocks an artery to the brain, a stroke follows

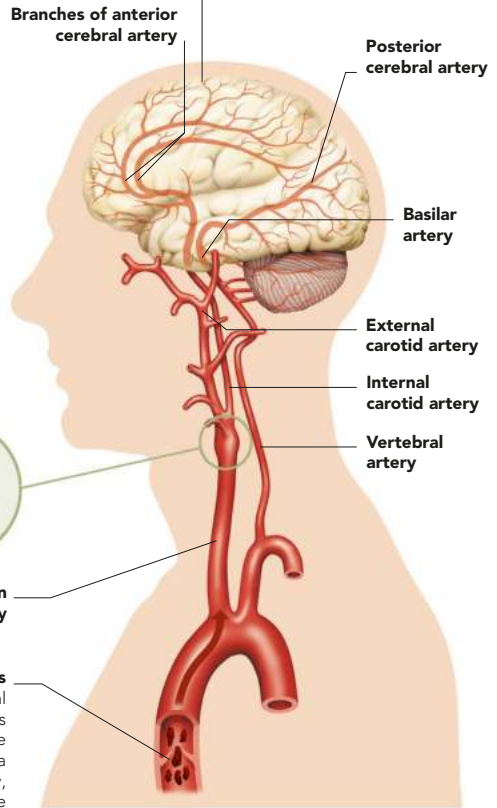


**Common carotid artery**

**Embolus**  
A piece of material called an embolus may travel in the blood and block a cerebral artery, causing a stroke

### Blockage of tiny vessels

Prolonged high blood pressure or diabetes may damage tiny blood vessels, which may lead to localized blockages known as lacunar strokes



### BLEEDING WITHIN THE BRAIN

An intracerebral haemorrhage, bleeding within brain tissue, is a main cause of stroke in older people who have hypertension. High blood pressure may put extra strain on small arteries in the brain, which causes them to rupture.

### BLOCKED BLOOD VESSELS

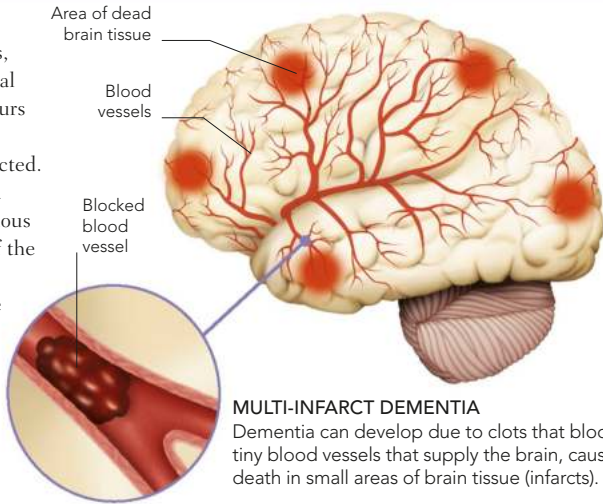
Blocked arteries that cause a stroke can occur for several reasons, ranging from localized blockages in tiny blood vessels deep within the brain to a blockage caused by a fragment of material that has travelled to the brain from elsewhere.

## DEMENTIA

Dementia combines memory loss, confusion, and general intellectual decline. The disorder mainly occurs in people over the age of 65, but young people are sometimes affected. In the early stages of dementia, a person is prone to becoming anxious or depressed due to awareness of the memory loss. As the dementia worsens, the person may become more dependent on others and may eventually need full-time care in a nursing home. Carers may also need support.

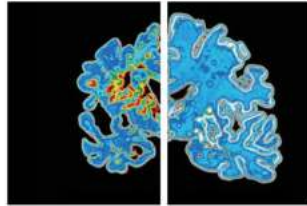
## ALZHEIMER'S DISEASE

The most common form of dementia is Alzheimer's disease. Brain damage occurs due to the abnormal production of a protein called amyloid, which builds up in the brain. No cure has been found, but drugs can slow the progress of the disease in some people.



### MULTI-INFARCT DEMENTIA

Dementia can develop due to clots that block tiny blood vessels that supply the brain, causing death in small areas of brain tissue (infarcts).



ALZHEIMER'S DISEASE

HEALTHY BRAIN

### BRAIN IN ALZHEIMER'S DISEASE

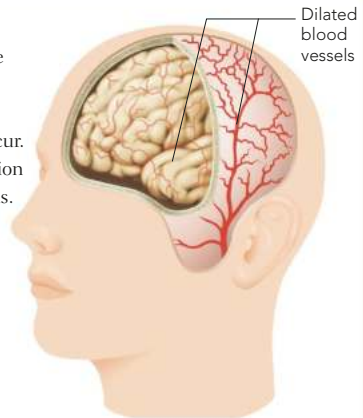
This computer graphic shows a slice through the brain of a person with Alzheimer's disease compared to a slice of healthy brain. The diseased brain is considerably shrunken due to the degeneration and death of nerve cells. The surface of a brain affected by Alzheimer's disease may be more deeply folded than normal.

## MIGRAINE

About 1 in 10 people has migraine, with episodes of severe headache often associated with visual disturbances, nausea, and vomiting. The underlying cause of a migraine is unknown, but changes in the diameter of the blood vessels in the scalp and brain are known to occur. Current research indicates that migraine is linked to abnormal function of nerve pathways and a disturbance in the activity of brain chemicals. Triggers for a migraine attack include stress, missed meals, lack of sleep, and certain foods, such as cheese or chocolate. In many women, migraines are associated with menstruation.

### HEADACHE PHASE

During migraine, severe, throbbing pain may affect half or all of the head as blood vessels in the scalp and brain widen (dilate). These vascular changes are thought to be secondary to nerve pathway abnormalities.



## BRAIN INFECTIONS

Infection of brain tissue or its protective layers can be caused by a variety of viruses, bacteria, and tropical parasites. Infection of the brain, or encephalitis, is a rare complication of a viral infection, such as mumps or measles. It can be fatal, with babies and elderly people being most at risk.

## MENINGITIS

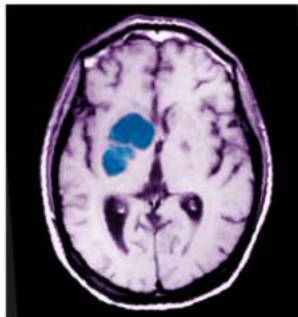
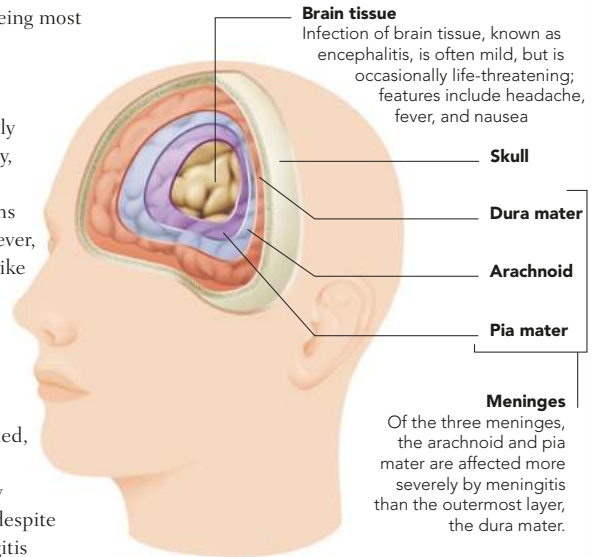
Inflammation of the meninges is usually caused by a virus or bacterium. Initially, meningitis may cause vague flu-like symptoms. More pronounced symptoms may also develop, such as headache, fever, nausea, vomiting, stiff neck, and a dislike of bright light. In meningitis due to *Meningococcus* bacteria, there is a distinctive reddish-purple rash. If meningitis is suspected, immediate admission to hospital is necessary for tests. If bacterial meningitis is confirmed, treatment in intensive care is often required, and a complete recovery may take weeks or months. It can be fatal despite treatment. Recovery from viral meningitis usually takes up to two weeks. No specific treatment is needed.

## BRAIN ABSCESS

An abscess is a collection of pus. Brain abscesses are rare, and are usually caused by bacteria that have spread to the brain from an infection in tissues in the skull. Treatment consists of high doses of antibiotics and possibly corticosteroids to control swelling of the brain. Surgery may be needed to drain pus through a hole drilled in the skull. If given early treatment, many people recover from it. However, some have persistent problems, such as seizures or slurred speech.

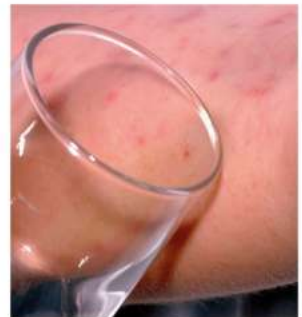## SITES OF INFECTION

Infectious organisms can affect the brain itself, the three membranes (meninges) that surround the brain, or both. Infections can reach the brain through the blood, but can also spread from a nearby infection (such as an ear infection) or through a skull wound.



### BRAIN ABSCESS

This MRI scan of the brain shows an abscess (blue area) due to a fungal infection in a person who has AIDS. People with AIDS are at increased risk of developing a brain abscess.



### TESTING A MENINGITIS RASH

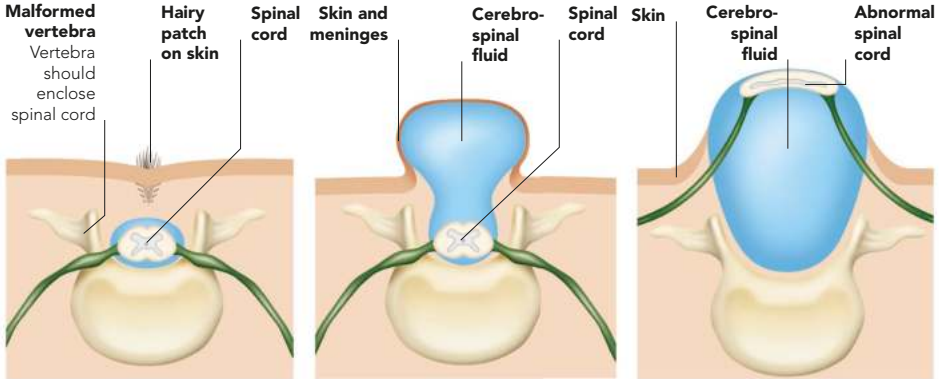
In meningococcal meningitis, bacteria in the blood may cause dark-red or purple spots that turn into blotches. The rash does not fade when pressed with a glass.



## SPINA BIFIDA

There are three main forms of spina bifida: spina bifida occulta, meningocele, and myelomeningocele. Spina bifida occulta may require surgery to avoid serious neurological complications later in life. Meningoceles usually have a good prognosis after surgery. Myelomeningocele has effects that may include

paralysis or weakness in the legs, and lack of bladder and bowel control. Children with this form will have a permanent disability and may need extra support during their lives. Folic acid helps to prevent spina bifida, and women are advised to take supplements when planning to conceive and during the first 12 weeks of pregnancy.



### SPINA BIFIDA OCCULTA

One or more vertebrae in the spine are malformed, but the cord is not damaged. On the skin, there may be dimpling, a tuft of hair, a fatty lump (lipoma), or a birthmark.

### MENINGOCELE

The meninges protrude through a malformed vertebra as a visible fluid-filled sac called a meningocele. The spinal cord remains intact, and the defect can be repaired.

### MYELOMENINGOCELE

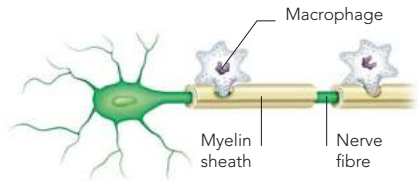
A part of the spinal cord, contained within a sac of fluid, protrudes through the skin. This is the most severe form of spina bifida, and will leave the child with some degree of disability.

## MULTIPLE SCLEROSIS

Multiple sclerosis (MS) is due to immune system damage to the sheaths that insulate nerve fibres. It affects sensation, movement, body functions, and balance. In some people, symptoms may last for days or weeks, then clear up for months or years. In others, they gradually get worse. Drugs may help to lengthen remission periods and shorten attacks.

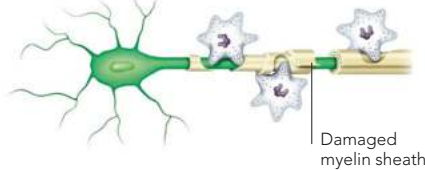
### EARLY STAGE

At first, there are only small patches of damage. Macrophages, a type of scavenging cell, remove damaged areas of the myelin sheaths, exposing the fibres and impairing nerve conduction.



### LATE STAGE

As MS progresses, the amount of damage to the sheaths increases, and affects conduction in more fibres. As the damage spreads, the symptoms become progressively worse.

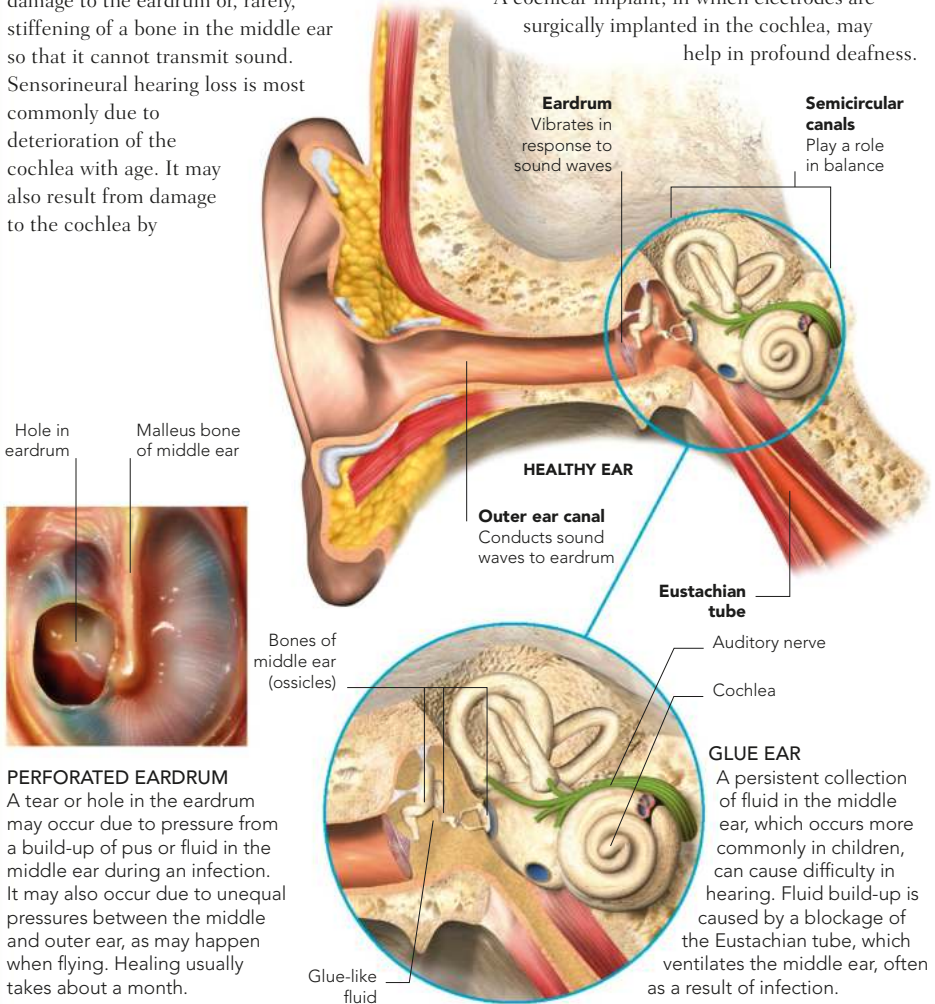


## DEAFNESS

There are two types of hearing loss: conductive and sensorineural. Conductive hearing loss results from impaired transmission of sound waves to the inner ear, and is often temporary. In children, the most common cause is glue ear (see below). In adults, it is most commonly due to blockage by earwax. Other causes include damage to the eardrum or, rarely, stiffening of a bone in the middle ear so that it cannot transmit sound. Sensorineural hearing loss is most commonly due to deterioration of the cochlea with age. It may also result from damage to the cochlea by

excessive noise or by Ménière's disease. Rarely, hearing loss is caused by an acoustic neuroma or by certain drugs. Simple measures can be effective for treating conductive deafness, such as syringing the ear to remove earwax. Surgery may be required for glue ear or otosclerosis. Sensorineural deafness usually cannot be cured, but hearing aids can help.

A cochlear implant, in which electrodes are surgically implanted in the cochlea, may help in profound deafness.

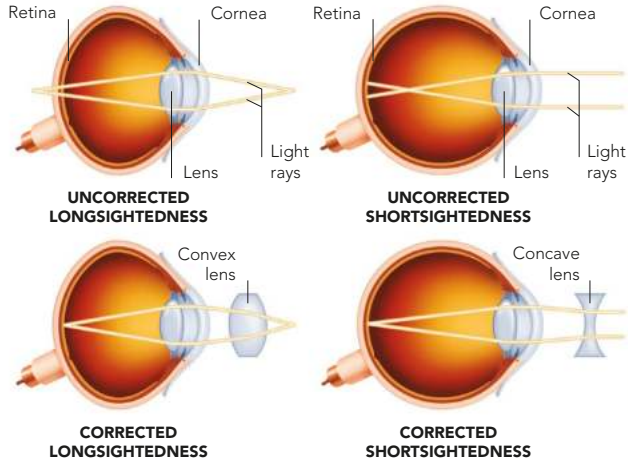


### PERFORATED EARDRUM

A tear or hole in the eardrum may occur due to pressure from a build-up of pus or fluid in the middle ear during an infection. It may also occur due to unequal pressures between the middle and outer ear, as may happen when flying. Healing usually takes about a month.

## FOCUSING PROBLEMS

Longsightedness (hypermetropia) and shortsightedness (myopia) result from the eyeball being either too short or too long (see right). In astigmatism, vision is blurred because the cornea is irregularly curved, and the lens cannot focus all light rays on the retina. Ageing often affects near vision, as the lens loses its elasticity and cannot easily adjust its shape. Refractive errors can usually be corrected by glasses or contact lenses, or by surgical techniques such as laser-assisted in-situ keratomileusis (LASIK) and photorefractive keratectomy (PRK). In LASIK, the middle layers of the cornea are reshaped by a laser, while in PRK, areas of the cornea's surface are shaved away by a laser to alter its shape.



### LONGSIGHTEDNESS

In longsightedness, the eyeball is too short, so the cornea and lens focus light rays behind the retina, and the image is blurred. Convex lenses make the light rays converge so that they are focused on the retina, correcting vision.

### SHORTSIGHTEDNESS

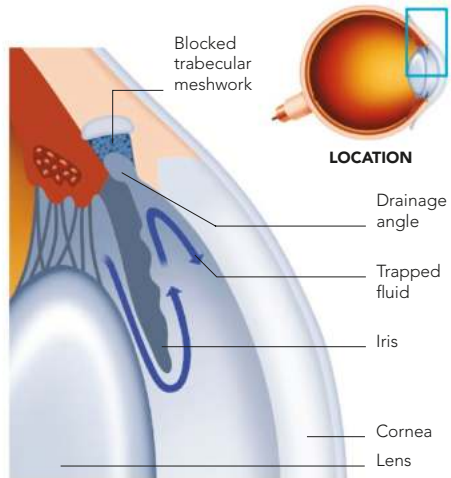
In shortsightedness, the eyeball is too long, so the cornea and lens focus light rays in front of the retina, and the image is blurred. Concave lenses are required, which make the light rays diverge so that they are focused on the retina.

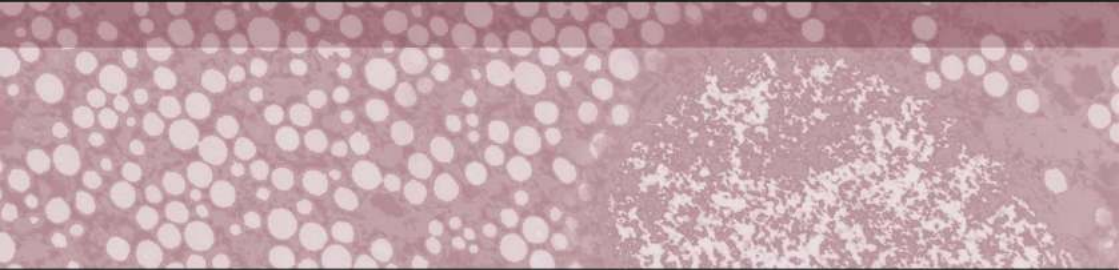
## GLAUCOMA

Glaucoma occurs when there is an abnormally high pressure inside the eyeball that is caused by a build-up of fluid. The pressure may permanently damage nerve fibres in the retina or the optic nerve, and so affect vision. In acute glaucoma, the condition develops suddenly and is accompanied by severe pain. Chronic glaucoma (see right) comes on slowly and painlessly over many years.

### CHRONIC GLAUCOMA


Fluid continually moves into and out of the eye to nourish its tissues and maintain the shape of the eye. Normally, the fluid flows out through the pupil and drains out of the trabecular meshwork within the drainage angle. In chronic glaucoma, the meshwork is blocked, and pressure builds up.





LIKE THE BRAIN AND NERVES, THE ENDOCRINE SYSTEM IS INVOLVED IN THE INFORMATION BUSINESS. HORMONES CARRY ESSENTIAL MESSAGES THAT HAVE FAR-REACHING EFFECTS. THEY CONTROL PROCESSES AT EVERY LEVEL, FROM ENERGY UPTAKE OF A SINGLE CELL TO THE WHOLE BODY'S RATE OF GROWTH AND DEVELOPMENT. TODAY, ARTIFICIAL REPLACEMENTS FOR UNDERACTIVE GLANDS AND HORMONE-BLOCKERS FOR OVERACTIVE GLANDS ARE AVAILABLE. MEANWHILE, THE LIST OF NEWLY DISCOVERED HORMONES CONTINUES TO GROW.

# ENDOCRINE SYSTEM



# ENDOCRINE ANATOMY

THE BODY'S CHEMICAL MESSENGERS, HORMONES, ARE PRODUCED BY ENDOCRINE GLANDS. HORMONES TARGET CERTAIN TISSUES TO REGULATE THEIR ACTIVITIES.

The endocrine system is composed of bodies of glandular tissue, such as the thyroid, and also includes glands within certain organs, including the testes, ovaries, and heart. These glands and tissues secrete hormones that control and coordinate body functions such as the breakdown of chemical substances in metabolism, fluid balance and urine production, growth and development, and sexual reproduction. As hormones travel in the blood, each hormone reaches every body part. However, the specific molecular shape of each hormone slots only into receptors on its target tissues or organs.

**Hypothalamus**  
Cluster of nerve cells that serves as the main link between nerves and hormones; produces hormones that control the pituitary gland

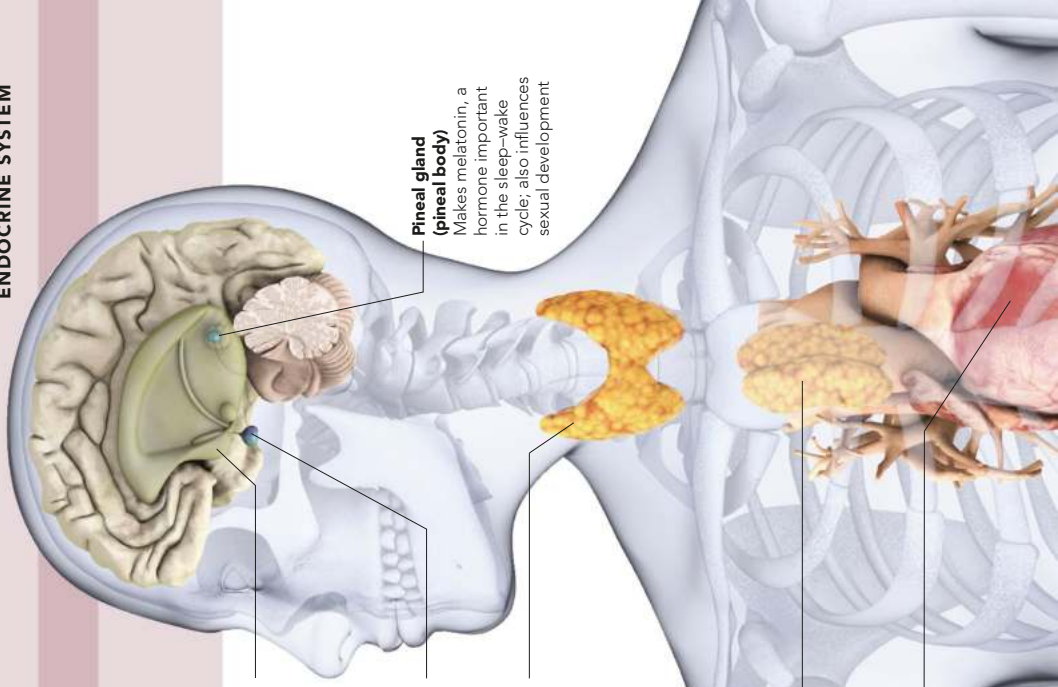
**Pituitary gland**  
Called the "master gland"; controls many other endocrine glands

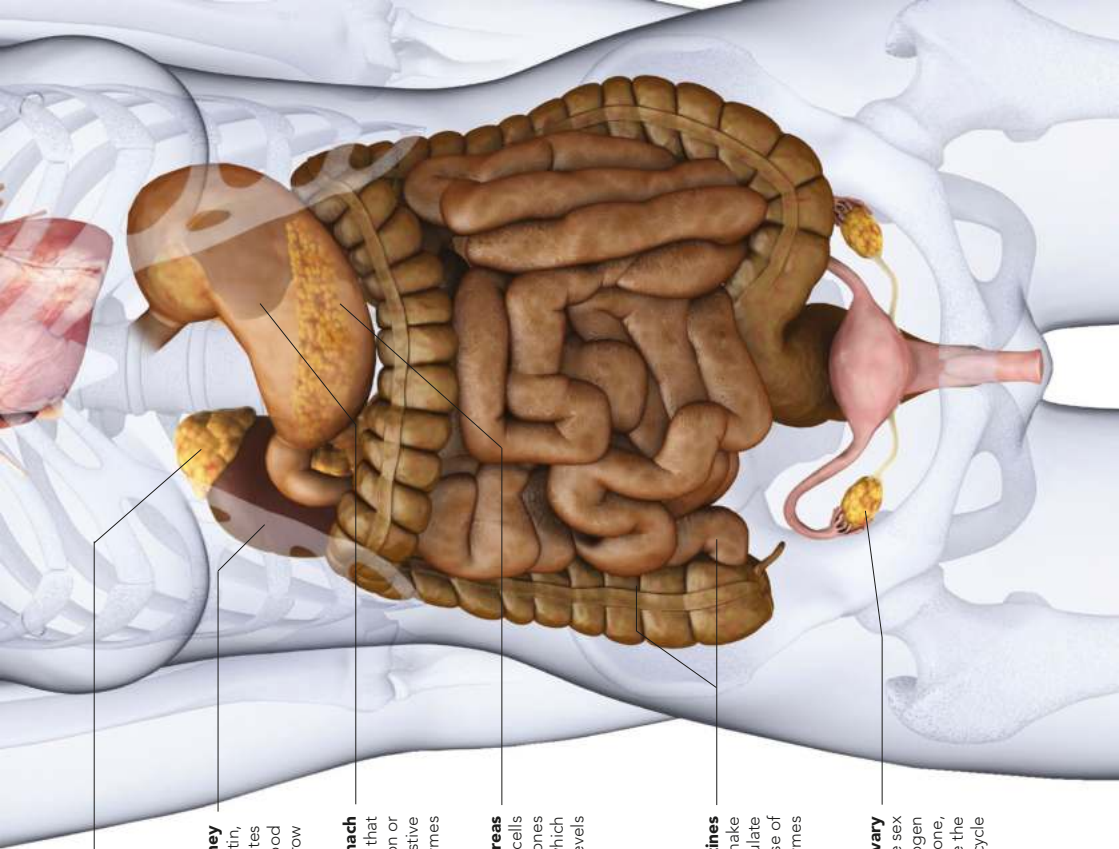
**Thyroid gland**  
Controls aspects of metabolism, including maintenance of body weight, rate of energy use, and heart rate

**Thymus gland**  
Produces hormones involved in development of white blood cells, called T cells, that are part of the immune system

**Heart**  
Produces a hormone called atriopeptin that reduces blood volume and pressure and helps to regulate fluid balance

**Pineal gland (pineal body)**  
Makes melatonin, a hormone important in the sleep-wake cycle; also influences sexual development





**Adrenal gland**  
Outer layer manufactures steroid hormones that regulate metabolism and maintain fluid balance; inner layer produces adrenaline

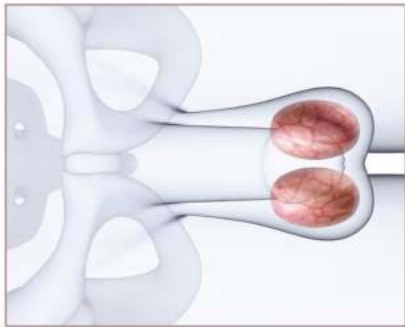
**Kidney**  
Secretes erythropoietin, which stimulates production of red blood cells in bone marrow

**Stomach**  
Makes hormones that stimulate production or release of digestive enzymes

**Pancreas**  
Contains clusters of cells that produce the hormones insulin and glucagon, which control blood glucose levels

**Intestines**  
Like the stomach, make hormones that stimulate production or release of digestive enzymes

**Ovary**  
Makes the female sex hormones oestrogen and progesterone, which regulate the menstrual cycle



**TESTES**  
In males, the two testes produce androgens: male sex hormones, including testosterone. Androgens stimulate the growth and development of the male sexual organs and the production of sperm, and influence secondary sexual characteristics, such as facial hair and deepening of the voice.

# HORMONE PRODUCERS

HORMONES CARRY THE CHEMICAL DATA THAT CONTROL THE RATE AT WHICH GLANDS AND OTHER ORGANS WORK. HORMONE-PRODUCING CELLS ARE FOUND ALL AROUND THE BODY, MANY IN GLANDS THAT HAVE SPECIALIZED FUNCTIONS.

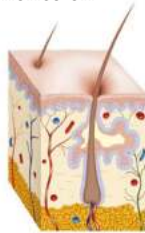## MASTER GLAND: THE PITUITARY

The pituitary, or hypophysis, is the most influential gland in the endocrine system. It comprises two distinct glands in one. The front (anterior) lobe, also known as the adenohypophysis, forms the larger part. Behind is the posterior lobe, or neurohypophysis. The anterior pituitary manufactures eight major hormones on

site and releases them into the bloodstream. The posterior pituitary receives its two main hormones from the hypothalamus, which lies above it; there, they are made by neurosecretory cells. Other neurosecretory cells make regulatory hormones, which travel via capillaries to the anterior lobe and control the release of hormones there.

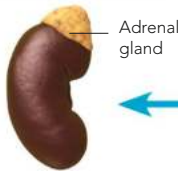
### SKIN

The action of melanocyte-stimulating hormone (MSH) – produced in a thin layer between the two pituitary lobes – causes cells called melanocytes in skin tissue to produce more melanin pigment, making the skin darken.



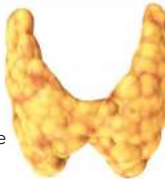### ADRENAL GLAND

Adrenocorticotropic hormone (ACTH) triggers the adrenals to produce steroid hormones that control stress response and the body's use of fats, carbohydrates, proteins, and minerals.



### THYROID

Thyrotropin-releasing hormone from the hypothalamus controls the release of thyroid-stimulating hormone (TSH). This encourages the thyroid to become more active and affects metabolism.



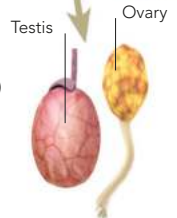
### BONE AND GENERAL GROWTH

Growth hormone (GH) acts on the whole body to promote protein manufacture, bone growth, and building of new tissues throughout life, but is especially important for development in children.



### SEX GLANDS

Luteinizing hormone (LH) and follicle-stimulating hormone (FSH) trigger the sex glands to make their own hormones, and also to produce ripe egg cells in females and mature sperm cells in males.

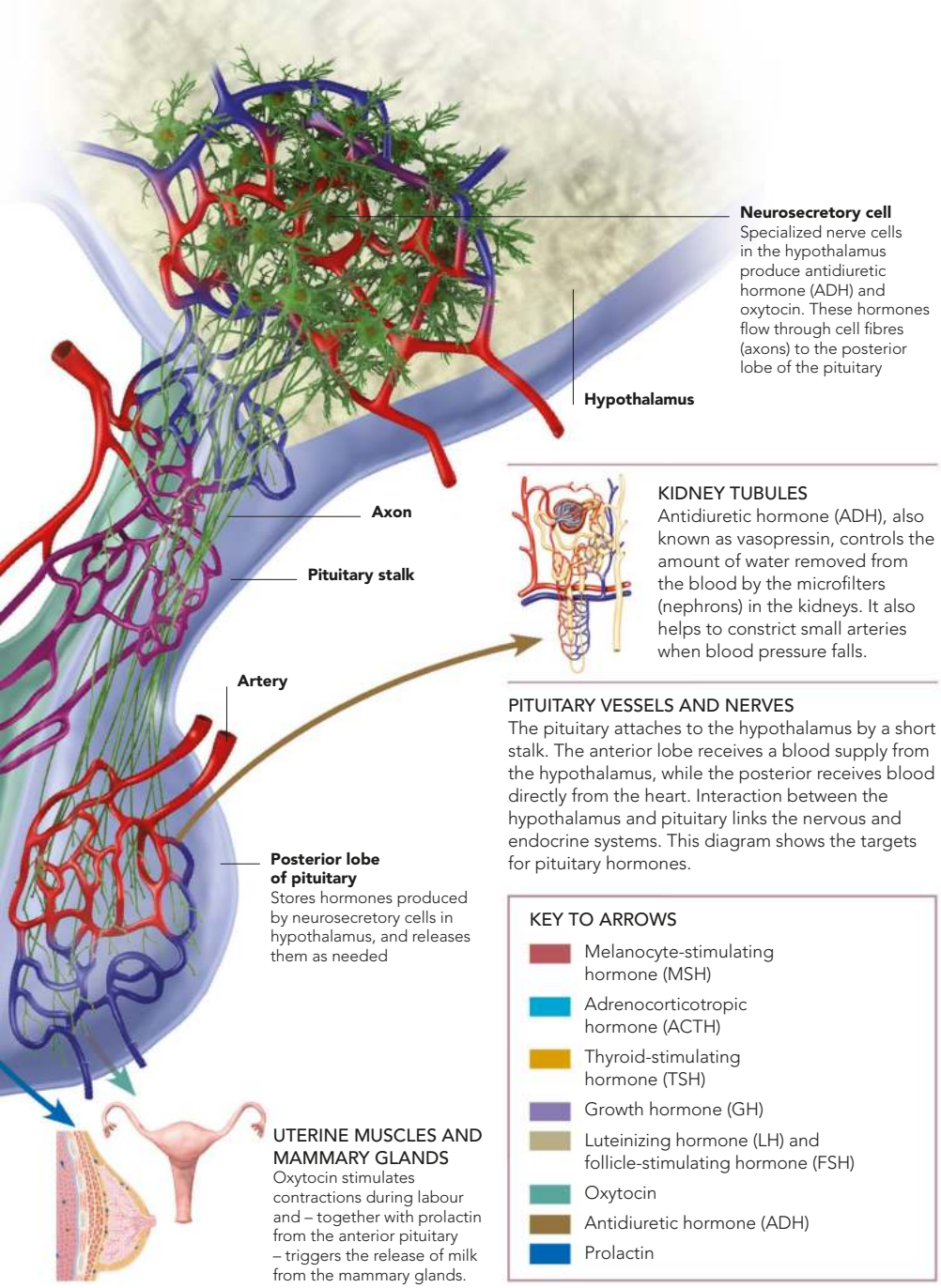


**Hypophyseal portal system**  
System of blood vessels that carry regulatory hormones (releasing factors) from hypothalamus to anterior pituitary lobe

**Anterior lobe of pituitary**  
Contains cells that manufacture about eight main hormones; secretion of these hormones is regulated by the hypothalamus

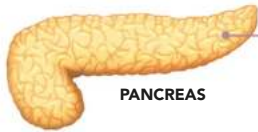
Vein





## PANCREAS

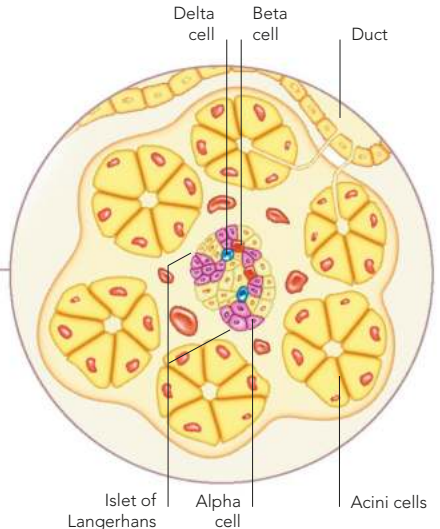
The pancreas is a dual-purpose gland. It produces digestive enzymes in cells called acini, but also has an endocrine function. Within the acinar tissues are cell clusters known as islets of Langerhans, which produce hormones involved in controlling glucose (blood sugar), the body's main energy source. Beta cells make the hormone insulin, which promotes glucose uptake by body cells and speeds conversion of glucose into glycogen for storage in the liver. In this way, insulin lowers blood glucose levels.



### PANCREATIC ISLETS

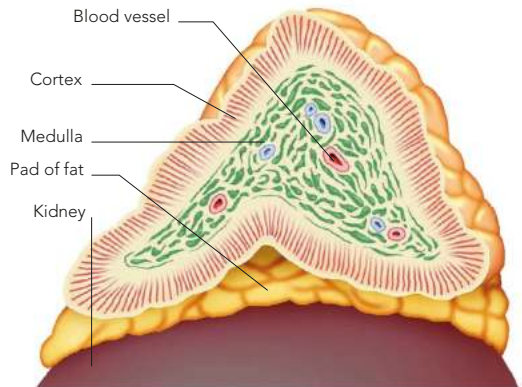
Surrounded by enzyme-producing acini cells, the tiny pancreatic islets contain three types of cells: alpha, beta, and delta. The secretions of the latter help regulate insulin and glucagon production.

Another hormone, glucagon, is produced by alpha cells and has opposing actions, raising blood glucose levels. Delta cells make somatostatin, which regulates the alpha and beta cells.



## ADRENAL GLANDS

The inner layer (medulla) and outer layer (cortex) of the adrenal gland each secrete different hormones. The cortical hormones are steroids (see p.139) and include glucocorticoids, such as cortisol, which affect metabolism; mineralocorticoids, such as aldosterone, which influence salt and mineral balance; and gonadocorticoids, which act on the ovaries and testes. The medulla functions as a separate gland. Its nerve fibres link to the sympathetic nervous system, and it makes the fight-or-flight hormones, such as adrenaline.

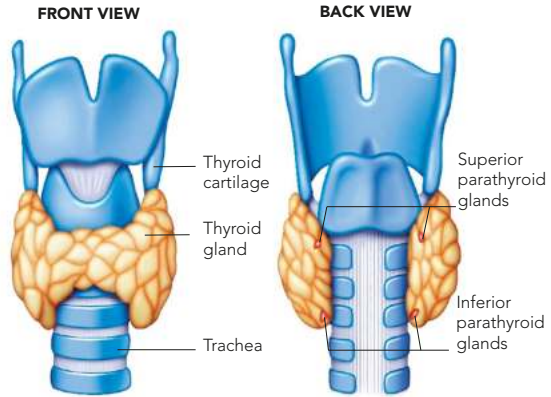


### ADRENAL ANATOMY

Each adrenal gland is shaped like a cone or pyramid and sits on top of the kidney, cushioned by a pad of fat. The glands consist of two parts: the cortex, which has three layers, and the medulla, containing nerve fibres and blood vessels.

## THYROID AND PARATHYROID GLANDS

The thyroid is located in the front of the neck, and has four tiny parathyroid glands embedded at the back. The hormones it produces have wide-ranging effects on body chemistry, including the maintenance of body weight, the rate of energy use from blood glucose, and heart rate. Unlike other glands, the thyroid can store its hormones. The parathyroids make parathormone (PTH), which increases the levels of calcium in the blood. PTH acts on bones to release their stored calcium, on the intestines to increase calcium absorption, and on the kidneys to prevent calcium loss.



### THYROID

The thyroid wraps round the upper windpipe (trachea). It produces two hormones that regulate the body's metabolism: thyroxine ( $T_4$ ) and triiodothyronine ( $T_3$ ).

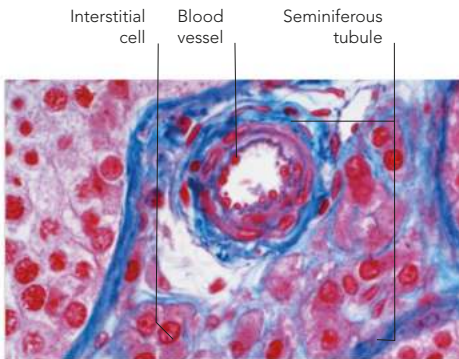
### PARATHYROIDS

The small parathyroid glands are set into the rear corners of the thyroid's lobes, at the back of the trachea. There are usually four, but their number and exact locations vary.

## SEX GLANDS AND HORMONES

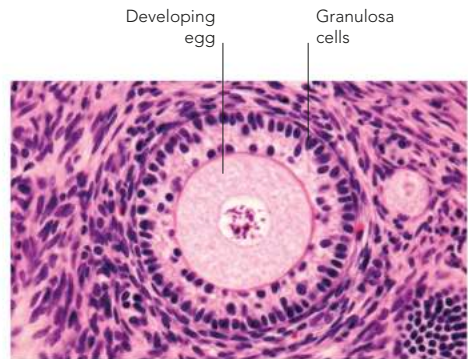
The main sex glands are the ovaries and testes. The hormones they produce stimulate the production of eggs and sperm respectively, and influence a developing embryo's sex. Until puberty, levels of sex

hormones remain low. Then, in males, the testes increase their output of androgens (male sex hormones), such as testosterone. In females, the ovaries produce more oestrogens and progesterone.



### TESTOSTERONE PRODUCERS

The cells shown in pink in this microscopic image of the testis secrete testosterone. They are found in the connective tissue between seminiferous tubules.



### OESTROGEN PRODUCERS

This microscope picture shows a developing egg surrounded by a ring of granulosa cells. These cells secrete oestrogens.

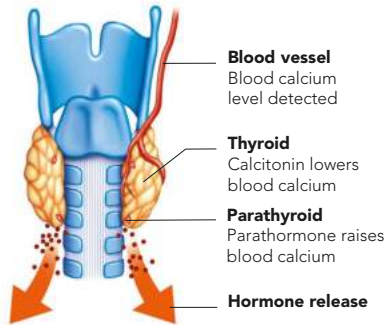
# HORMONAL ACTION

HORMONES REGULATE THE FUNCTION OF THEIR TARGET CELLS BY ADJUSTING THE RATE AT WHICH A CELL'S BIOCHEMICAL REACTIONS OCCUR. DIFFERENT HORMONES ARE RELEASED ACCORDING TO DIFFERENT TRIGGER MECHANISMS.

## HORMONAL TRIGGERS

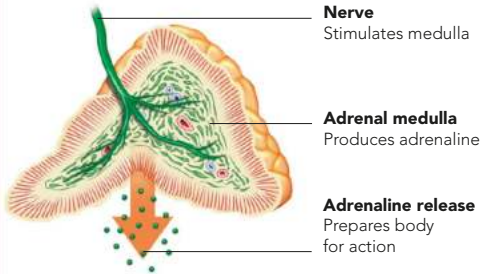
Various stimuli cause an endocrine gland to release more of its hormone. In some cases, the gland responds to the level of a certain substance in the blood, using a feedback loop (see opposite). In other cases, there is an intermediate mechanism, such as the hypothalamus–pituitary complex. The adrenal gland is controlled both by adrenocorticotropic

hormone (ACTH), released by the pituitary on cue from the hypothalamus, and by nerve impulses direct from the hypothalamus. The pea-sized pineal gland, near the centre of the brain, is triggered by darkness to release the sleep hormone melatonin. Pineal activity is inhibited by light, which is detected by the eye and sent to the gland as a series of nerve impulses.



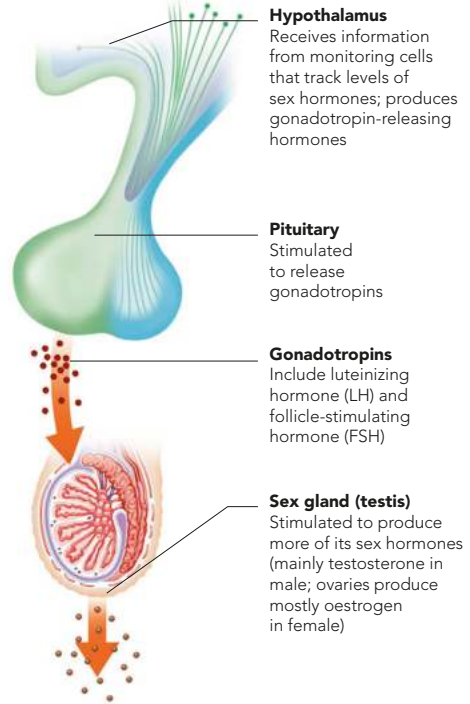
### BLOOD LEVEL STIMULATION

Low blood calcium levels inhibit release of calcitonin from the thyroid and stimulate the parathyroids to release parathormone; calcium levels are raised.



### DIRECT INNERVATION

The adrenal medulla receives nerve fibres (is innervated) from the hypothalamus via the sympathetic nervous system.



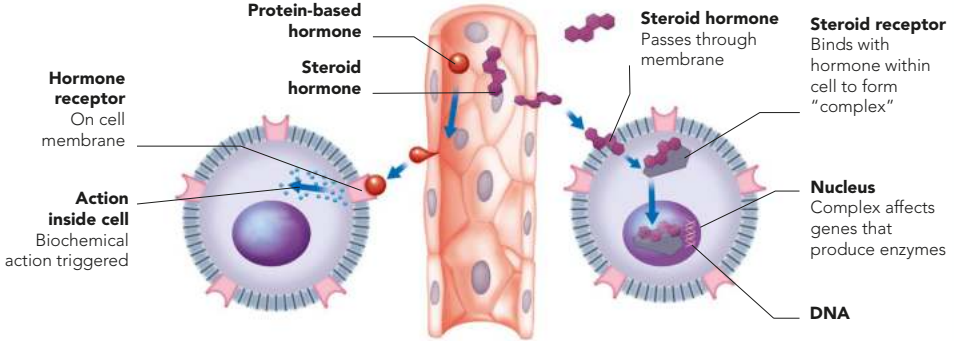
### HYPOTHALAMIC–PITUITARY CONTROL

As sex hormone levels fall, gonadotropin-releasing hormones (GnRH) are sent from the hypothalamus to the pituitary, which releases more gonadotropins.

## HORMONE CONTROL MECHANISMS

Chemically, there are two main types of hormones: those made of protein and amine molecules, and those made of steroids. The two groups work in a similar way, biochemically altering production

rates of certain substances, but at a cellular level they have different mechanisms. Protein and amine hormones act on receptor sites at a cell's surface; steroid hormones act on receptors inside the cell.



### PROTEIN-BASED HORMONES

These hormones cannot pass through the cell membrane. They bind to receptors on the membrane, triggering biochemical action inside the cell.

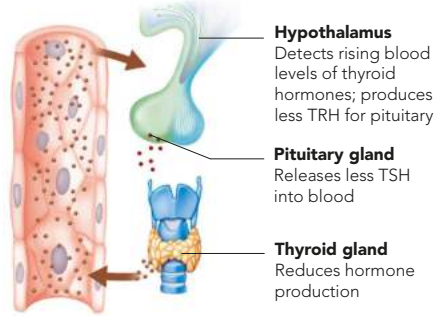
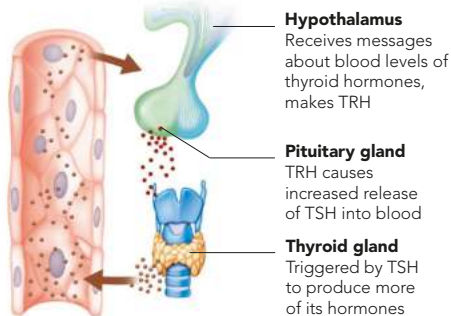
### STEROID-BASED HORMONES

Steroids pass into the cell, then bind to receptors and enter the cell nucleus. This triggers genes to produce enzymes that prompt biochemical action.

## FEEDBACK MECHANISMS

Hormone levels are controlled by feedback mechanisms, or loops. The amount of a hormone in the blood is detected and passed on to a control unit, which in many cases is the hypothalamus–pituitary

complex (as with the thyroid hormones, see below). If a hormone level is too high, the control unit reduces hormone production. If the level is too low, the control unit stimulates production.



### INCREASING LEVELS

Thyrotropin-releasing hormone (TRH) from the hypothalamus causes the pituitary to make thyroid-stimulating hormone (TSH); hormone levels rise.

### DECREASING LEVELS

High hormone levels prompt negative feedback, so the hypothalamus produces less TRH. This reduces TSH levels and the thyroid produces fewer hormones.

# ENDOCRINE DISORDERS

SOME HORMONES HAVE WIDESPREAD EFFECTS, SO HORMONAL DISORDERS CAN CAUSE PROBLEMS AROUND THE BODY. THE PREFIX "HYPER-" IMPLIES AN EXCESS OF HORMONE, MAKING ITS TARGETS TOO ACTIVE; "HYPO-" IMPLIES TOO LITTLE HORMONE AND UNDERACTIVITY OF ITS TARGETS.

## PITUITARY TUMOURS

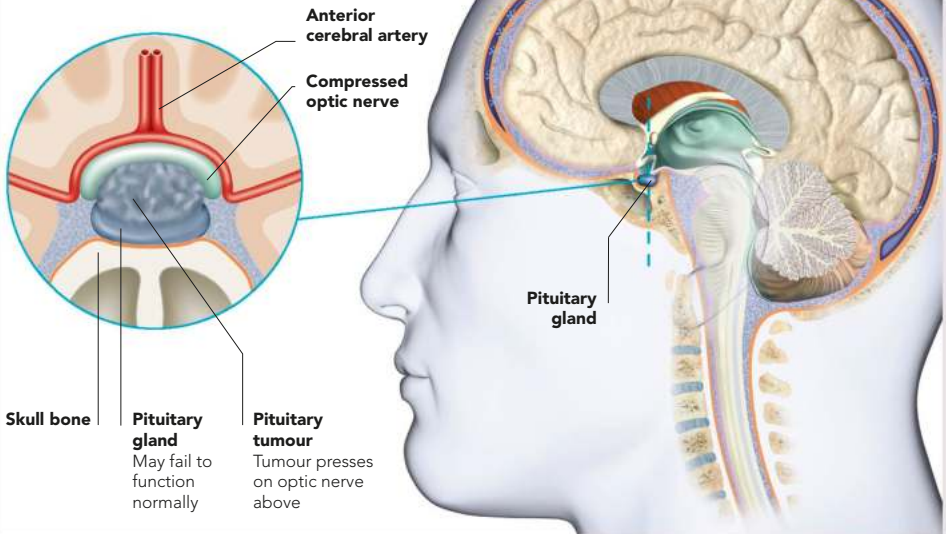
The central role of the pituitary in the endocrine system is reflected in the problems caused by a pituitary tumour, which may grow in any part of the gland; those in the anterior lobe are more likely to be benign (noncancerous). One result may be excess growth hormone, which causes enlargement of certain bones, such as those in the face, hands, and feet, and of some tissues, such as the tongue, as well as the appearance of coarse body hair and deepening of the voice. This condition is known as acromegaly. Some tumours cause excessive prolactin secretion or overstimulate the adrenal cortex.

### PITUITARY TUMOUR

An enlarging tumour may press on the optic nerves that pass just above it, causing headache and visual disturbances, such as losing part of the visual field.

### PROLACTINOMAS

About 40 per cent of pituitary tumours are prolactinomas – slow-growing, noncancerous tumours that cause the anterior lobe to secrete excessive prolactin. Normally this hormone promotes breast development and milk production in pregnancy. Symptoms of excess prolactin include irregular periods and lowered fertility in women; breast enlargement and impotence in men; and fluid leakage from the nipples, along with reduced sexual desire. In most cases, medication helps to shrink the tumour and reduce prolactin output; otherwise, surgery or radiotherapy may be necessary.



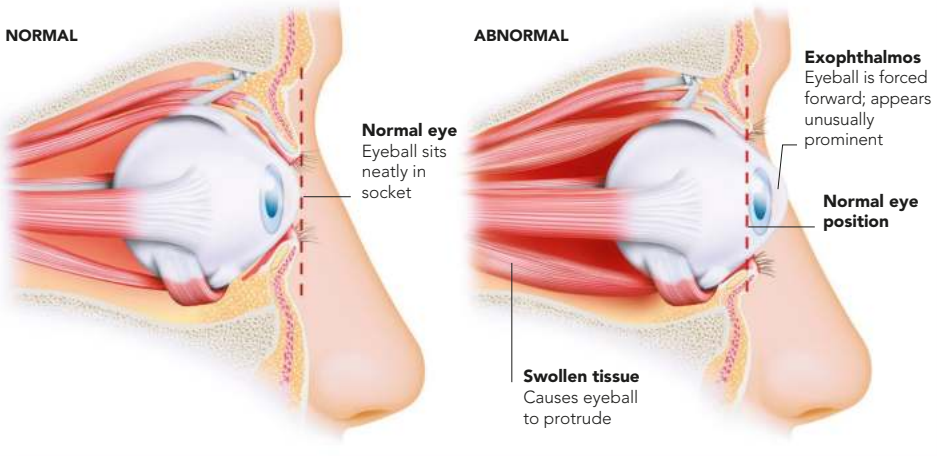
## HYPERTHYROIDISM

Three-quarters of overstimulated thyroid cases are due to Graves' disease, an autoimmune disorder in which antibodies stimulate the thyroid, causing excessive hormone production. It is one of the commonest hormonal disorders, especially in women aged 20-50. A less common cause is small lumps (nodules) in the gland. Raised hormone levels push up the metabolic rate, causing weight loss due to increased energy

usage, rapid irregular heartbeat, trembling, sweating, anxiety, insomnia, weakness, and more frequent bowel movements. The enlarged thyroid may show as a swelling in the neck (goitre). Drug treatment can usually control the condition.

### GRAVES' DISEASE

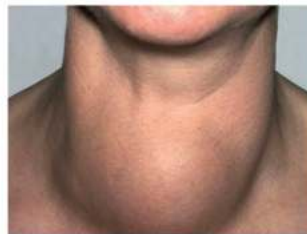Hyperthyroidism due to Graves' disease can cause bulging eyes, giving a staring appearance and possibly blurred vision.



## HYPOTHYROIDISM

In hypothyroidism, the thyroid hormones, tri-iodothyronine and thyroxine, are underproduced. As these hormones govern the speed of many metabolic processes, a lack of them leads to a slowing down of bodily functions. Symptoms of hypothyroidism include fatigue, weight gain, slow bowel activity and constipation, swollen face, puffy eyes, thickened skin, thinned hair, hoarse voice, and inability to cope with cold. The most common cause of hypothyroidism is inflammation of the thyroid gland due to an autoimmune condition called Hashimoto's thyroiditis, in which antibodies mistakenly damage the gland. The thyroid gland may swell considerably as a lump, or goitre, in the

neck. A less common cause of hypothyroidism is a lack of the mineral iodine – needed to make the thyroid hormones – in the diet. A rarer possibility is damage to the pituitary gland by a tumour.



### GOITRE

A swollen thyroid (goitre) may be due to thyroiditis, hyperthyroidism, hypothyroidism, thyroid nodules, or cancer of the thyroid.

# DIABETES MELLITUS

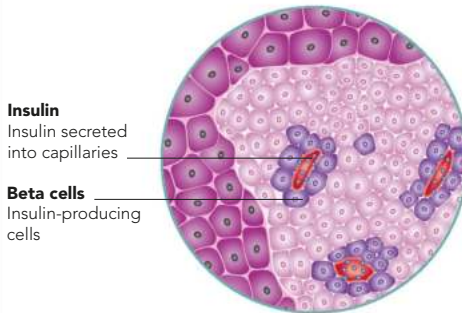
THE MAIN ENERGY SOURCE FOR CELLS IS GLUCOSE, WHICH THE CELLS ABSORB FROM THE BLOOD WITH THE HELP OF THE HORMONE INSULIN. IN DIABETES MELLITUS, THIS PROCESS DOES NOT WORK PROPERLY. THERE ARE TWO MAIN TYPES OF DIABETES MELLITUS: TYPE 1 AND TYPE 2.

## TYPE 1 DIABETES

Type 1 diabetes mellitus is an autoimmune disorder. It occurs when the immune system misidentifies beta cells in the islets of Langerhans in the pancreas as foreign and destroys them.

The cause is unknown, but the disease may be triggered by a viral infection or inflammation in the pancreas. It usually develops in childhood or adolescence. Symptoms include thirst, dry mouth,

hunger, frequent urination, fatigue, blurred vision, and weight loss. If untreated, the disorder can cause ketoacidosis, in which toxic chemicals called ketones build up in the blood. Affected people need urgent medical attention; otherwise they can fall into a coma. There can also be long-term complications (see Type 2 diabetes, opposite). Treatment involves insulin injections.

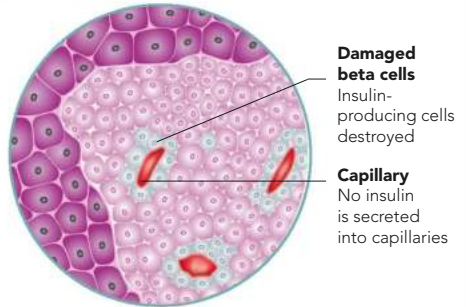


### NORMAL BETA-CELL FUNCTION

As food and drink are digested, the presence of glucose, amino acids, and fatty acids in the intestine stimulates beta cells to release insulin into the bloodstream via tiny blood vessels called capillaries, which run through the islets of Langerhans.

### DAMAGED BETA CELLS

If the beta cells are damaged, they cannot produce insulin. As a result, body cells cannot take up glucose, and blood glucose levels rise too high. The lack of insulin allows the alpha cells to produce more glucagon, which raises blood glucose levels still further.



## BLOOD SUGAR REGULATION

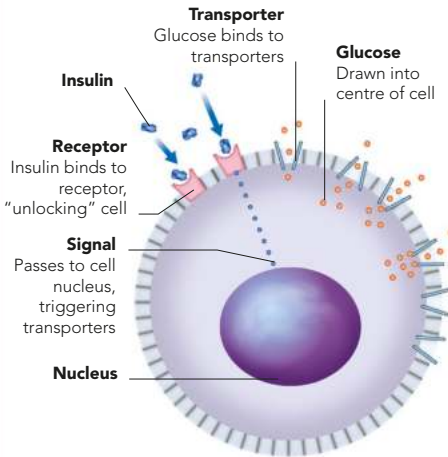
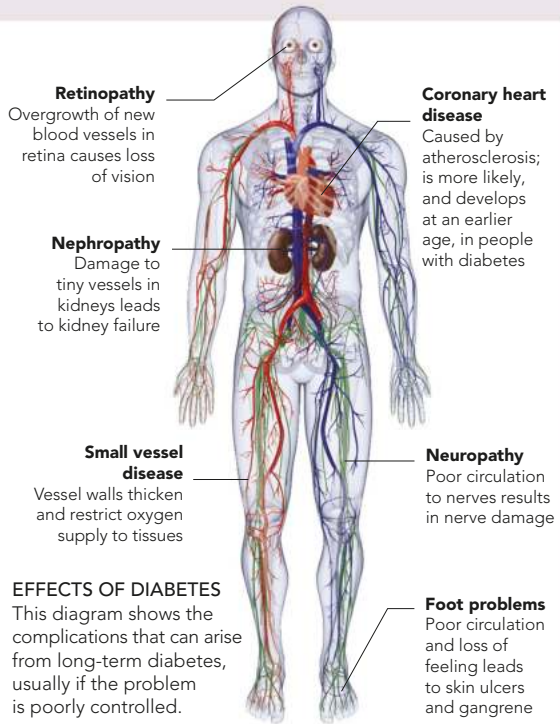
During digestion food is broken down to provide substances that cells can use to fuel and repair themselves. The main source of fuel is glucose, which is carried in the bloodstream to cells. Any excess is stored in the liver, muscle cells, and fat cells. The body needs to keep the blood glucose level steady. If it is too low, cells will not have

enough glucose for their energy needs. If it is too high, there is a risk of autoimmune disease and pancreatitis. If the blood glucose level is too low, alpha cells in the islets of Langerhans secrete glucagon, which stimulates the release of stored glucose. If the level is too high, beta cells in the islets secrete insulin, which reduces the level.



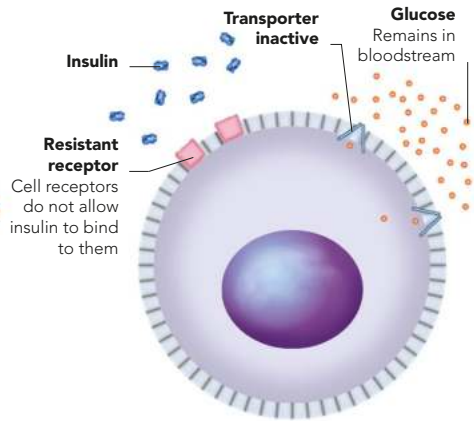
## TYPE 2 DIABETES

In type 2 diabetes, the pancreas secretes insulin, but the body cells are unable to respond to it. The causes are complex, including genetic predisposition and lifestyle factors. This form of diabetes is often associated with obesity and is a growing problem in affluent societies. The disorder develops slowly. There may be initial symptoms such as thirst, fatigue, and frequent urination, but in some cases the diabetes goes unnoticed for several years. As a result, complications may arise. Persistent high glucose levels can cause damage to small blood vessels around the body. People with type 2 diabetes are also more prone to high cholesterol levels, atherosclerosis (see p.157), and high blood pressure. The condition can be controlled with a healthy diet, regular exercise, and daily monitoring of blood glucose. However, in some cases, drugs are needed to boost insulin production or help the cells to absorb glucose.



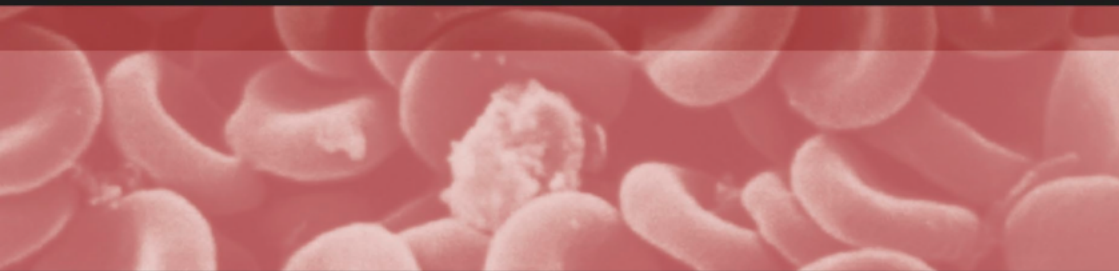
### NORMAL RECEPTORS

Insulin binds with receptors on a cell to allow glucose to enter the cell. This, in turn, triggers transporters in the cell to draw glucose inside.



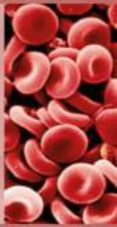### MALFUNCTIONING RECEPTORS

People with type 2 diabetes produce enough insulin, but the receptors are resistant to it and glucose cannot be taken into cells.



THROBBING HEART, PULSING VESSELS, BLOOD LEAKING FROM A WOUND – THE CARDIOVASCULAR SYSTEM IMPACTS DEEPLY ON OUR CONSCIOUSNESS. EVERY PART OF THE BODY RELIES ON A STEADY FLOW OF LIFE-GIVING BLOOD. THAT MOST VITAL OF PUMPS, THE HEART, IS MOSTLY MUSCLE AND, IF MALTREATED, IT CAN WEAKEN AND WASTE, COMPROMISING ITS OWN BLOOD SUPPLY. DISORDERS OF THE HEART AND CIRCULATION ARE GENERALLY CAUSED BY ABUSE AND EXCESS: SMOKING TOBACCO, OBESITY, AND TOO LITTLE EXERCISE.

# CARDIOVASCULAR SYSTEM

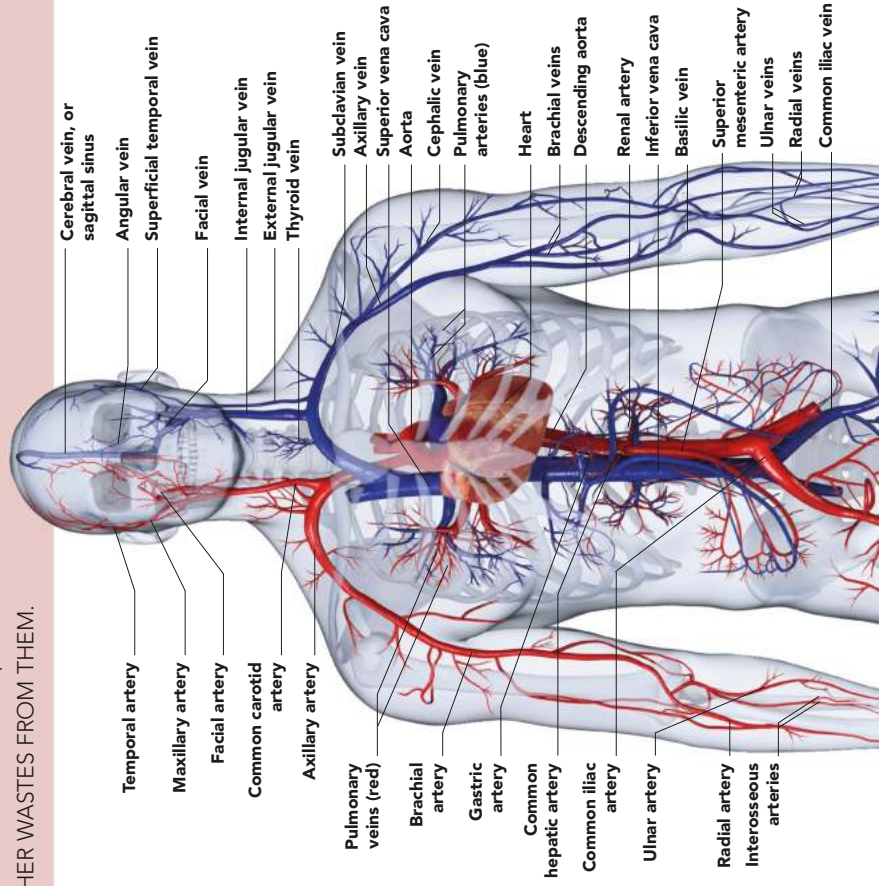


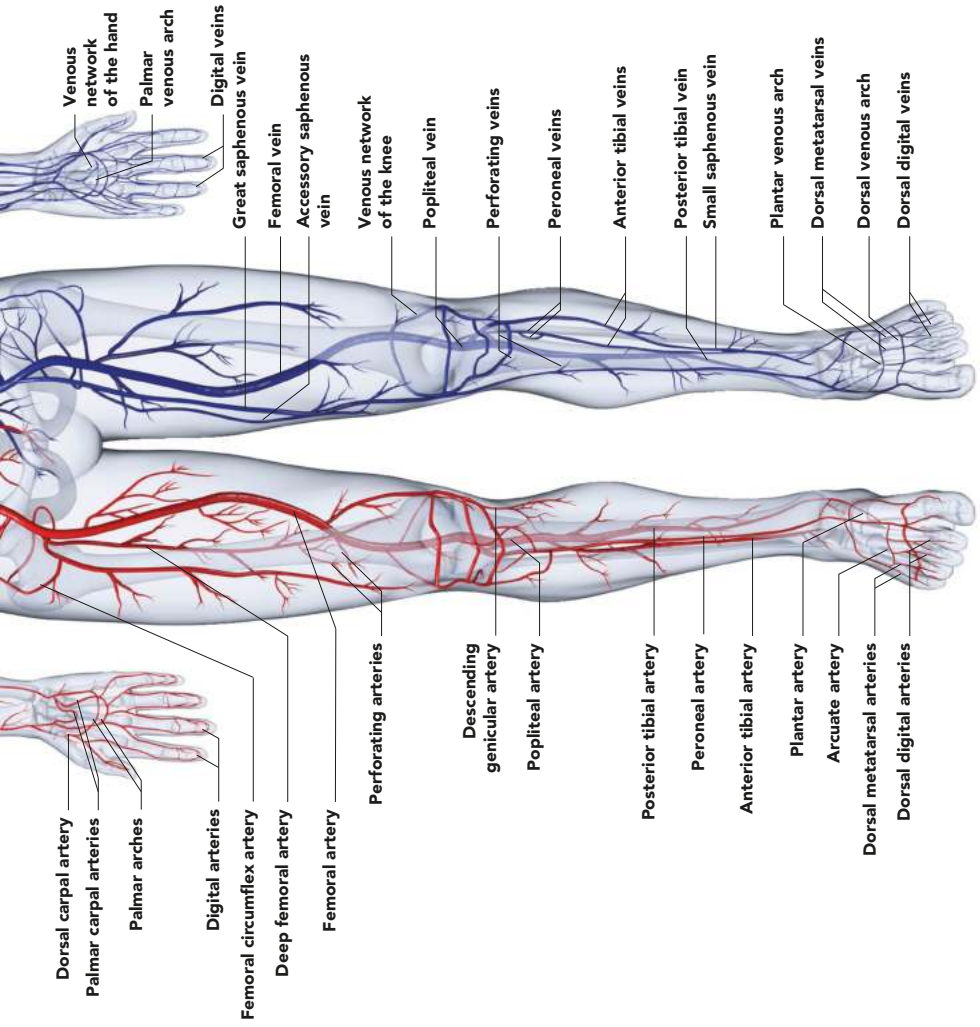
# CARDIOVASCULAR ANATOMY

THE CIRCULATORY (OR CARDIOVASCULAR) SYSTEM DELIVERS OXYGEN AND NUTRIENTS TO VIRTUALLY ALL BODY CELLS, AND REMOVES CARBON DIOXIDE AND OTHER WASTES FROM THEM.

The circulatory system comprises the heart, blood vessels, and blood.

Working as a pump, the heart beats regularly to send oxygen-rich blood into tough, elastic tubes called arteries, which convey the blood around the body. The arteries divide into tiny capillaries, the walls of which are so thin that oxygen, nutrients, and other substances can pass through to surrounding cells and tissues. Waste products flow from the tissues and cells into the blood for disposal. The capillaries join and enlarge to form veins, which take blood back to the heart. In the figure shown here, vessels carrying oxygenated blood (usually arteries) appear red and those carrying deoxygenated blood (usually veins) are blue. This intricate network is some 150,000km (90,000 miles) long – almost equivalent to four times the circumference of the Earth.





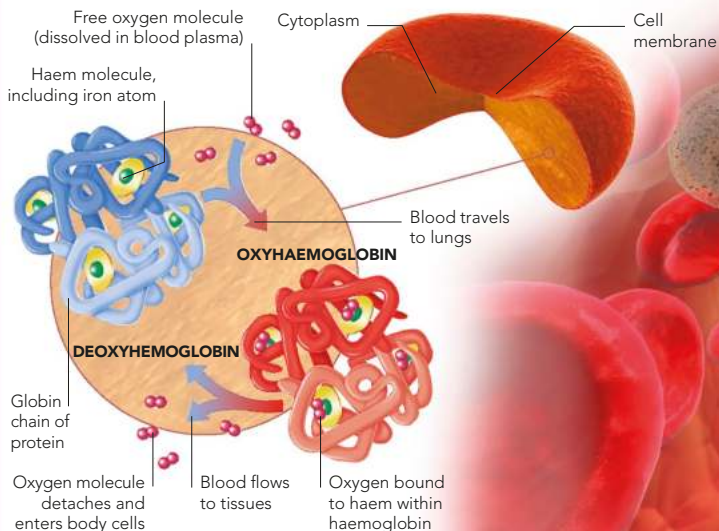
# BLOOD AND BLOOD VESSELS

BLOOD IS A COLLECTION OF SPECIALIZED CELLS SUSPENDED IN A STRAW-COLOURED LIQUID CALLED PLASMA. FLOWING AROUND THE BODY, BLOOD CARRIES OXYGEN AND NUTRIENTS, COLLECTS WASTE, DISTRIBUTES HORMONES, AND SPREADS HEAT.

## WHAT IS BLOOD?

An adult has about 5 litres (11 pints) of blood. Roughly 50–55 per cent of blood is plasma, 90 per cent of which is water. Plasma contains dissolved substances such as glucose (blood sugar), hormones, enzymes, and also waste products such as urea and lactic acid. Plasma also contains proteins such as albumins, fibrinogen (important in clotting), and globular proteins or globulins. Alpha and beta globulins help to transport lipids, which are fatty substances such as cholesterol.

Gamma globulins are mostly the disease-fighting substances known as antibodies. The remaining 45-50 per cent of blood is made up of three types of specialized cells. Red blood cells or erythrocytes carry oxygen; various white blood cells, known as leucocytes, are part of the defence system; and platelets or thrombocytes, which are tiny fragments of much larger cells, are involved in the process of clotting.



## RED BLOOD CELLS AND HAEMOGLOBIN

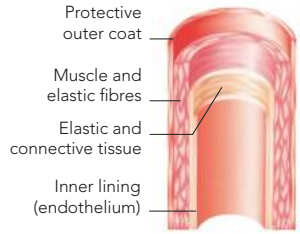
A biconcave disc with no nucleus, each red blood cell contains 300 million haemoglobin molecules. Haemoglobin is composed of haem, an iron-rich pigment, and globin, ribbon-like protein chains. Oxygen in the lungs latches onto haem to make oxyhaemoglobin. In this form, oxygen travels through the bloodstream to all parts of the body.

## BLOOD MAKE-UP

In  $1\text{ mm}^3$  ( $1/16,000\text{ in}^3$ ) of blood float about 5 million red cells, 10,000 white cells, and 300,000 platelets. These cells may have to move in single file through the narrowest blood vessels.

## ARTERIES

Arteries carry blood away from the heart towards organs and tissues. Apart from the pulmonary arteries, all arteries carry oxygenated blood. Their thick walls and muscular and elastic layers can withstand the high pressure that occurs as the heart pumps blood.

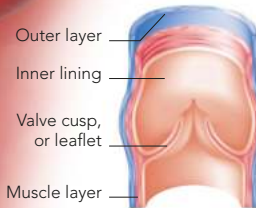


### ARTERY SECTION

Four layers are found in an artery wall. The blood-carrying space, or lumen, is in the centre.

## VEINS

A vein is more flexible than an artery, and its walls are thinner. The blood inside a vein is under relatively low pressure, and flows slowly and smoothly. Many larger veins, particularly the long veins in the legs, contain valves that prevent the backflow of blood, a job helped by muscles around the veins that contract during movement.



### VEIN SECTION

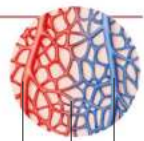
The muscle layer of a vein is thin and enclosed by two layers; the innermost layer of some veins has valves at regular intervals.

## CAPILLARIES

The smallest and most numerous of the blood vessels, capillaries convey blood between arteries and veins. A typical capillary is about 0.01mm ( $\frac{1}{2,500}$  in) in diameter, only slightly wider than a red blood cell. Many capillaries enter tissue to form a capillary bed, where oxygen and other nutrients are released, and where waste matter passes into the blood.

### CAPILLARY BED

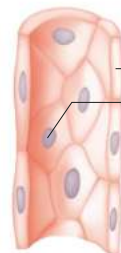
Capillaries link small arteries (arterioles) to veins (venules).



**Arteriole**  
Carries blood rich in oxygen

**Capillary**

**Venule**  
Contains blood low in oxygen



**Capillary wall**  
**Cell nucleus**

### CAPILLARY WALL

The thin capillary wall allows easy movement of substances between surrounding tissues.

### White blood cell

Also called leucocytes, white blood cells are a vital part of the body's defence system

### Platelet

Tiny, short-lived cell fragment that has an important role in the clotting of blood

### Red blood cell

Red blood cells (erythrocytes) have a lifespan of around 3 months

### Blood vessel wall

The thickness of the wall is dependent on the pressure of blood flowing through it

# HEART STRUCTURE

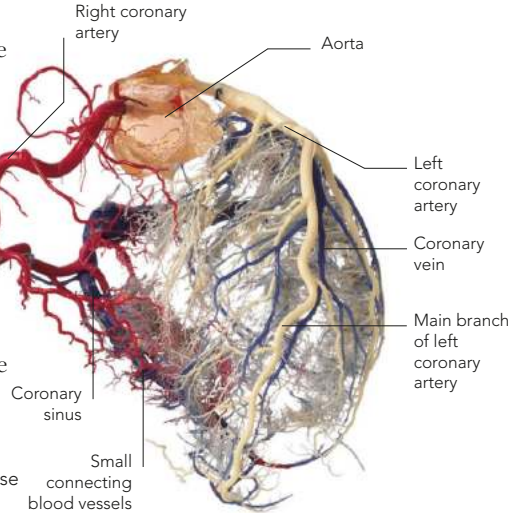
THE HEART IS A POWERFUL ORGAN ABOUT THE SIZE OF A CLENCHED FIST. LOCATED JUST TO THE LEFT OF CENTRE IN BETWEEN THE LUNGS, IT OPERATES AS TWO COORDINATED PUMPS THAT SEND BLOOD AROUND THE BODY.

## THE HEART'S BLOOD SUPPLY

The muscular wall, or myocardium, of the heart is constantly active and needs a generous supply of oxygen and energy from blood. To provide this, the heart muscle has its own blood vessels – the right and left coronary arteries. These vessels branch from the main artery, the aorta, just after it leaves the heart, and send smaller blood vessels into the heart muscle. Waste from heart tissue is removed by the coronary veins, in particular by the coronary sinus, a large vein at the back of the heart.

### CORONARY VESSELS

There are many connecting vessels between the coronary arteries. If an artery becomes blocked, these can provide an alternative route for the blood flow.

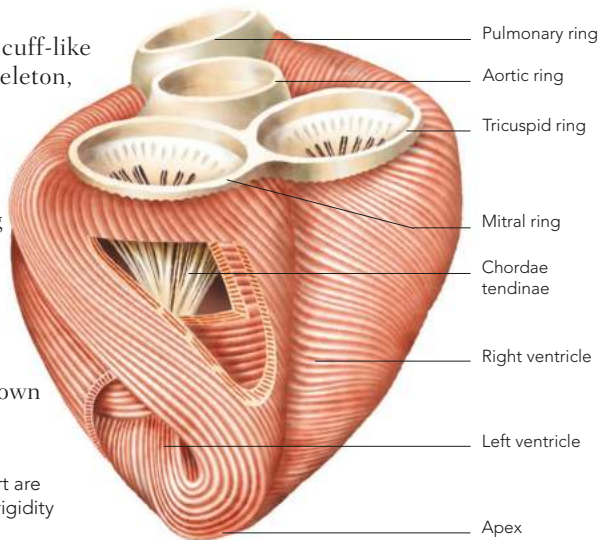


## CARDIAC SKELETON

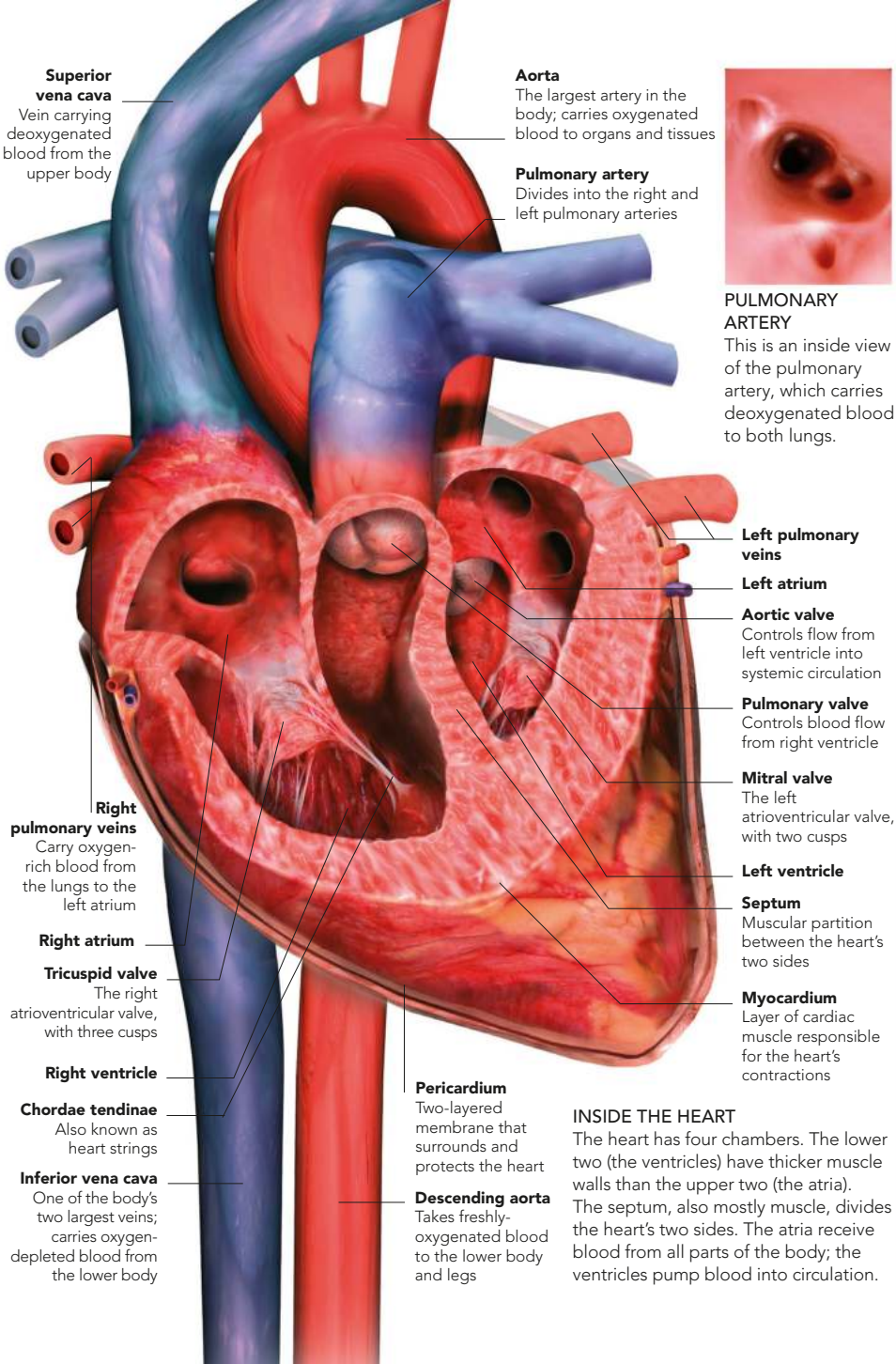
In the upper heart, four rigid, cuff-like rings, known as the cardiac skeleton, provide points of attachment for the four heart valves and for the heart muscle. The wrap-around muscle fibres in the ventricle walls, and the timing of their contractions, means the ventricles squirt blood from the apex (lower end) upwards, and out through the pulmonary and aortic valves, rather than squeezing blood down to pool in the apex region.

### FIBROUS FRAMEWORK

Four rings of fibrous tissue in the heart are known as the cardiac skeleton. Their rigidity prevents the valves from deforming.





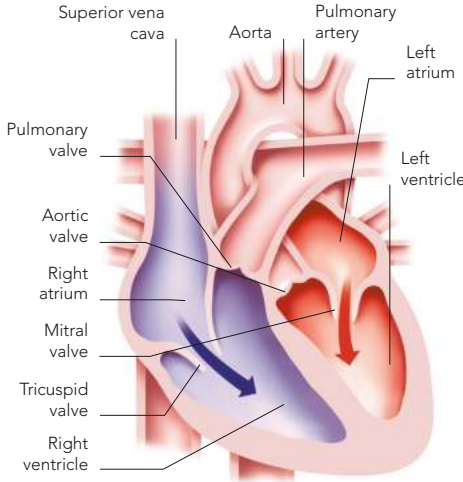
**INSIDE THE HEART**

The heart has four chambers. The lower two (the ventricles) have thicker muscle walls than the upper two (the atria). The septum, also mostly muscle, divides the heart's two sides. The atria receive blood from all parts of the body; the ventricles pump blood into circulation.

## HEART VALVES

The heart has four valves to control blood flow. Each has the same basic structure, although they differ in certain details. The two atrioventricular valves lie between the atria and ventricles. The mitral valve, on the left side, has two cusps, while its right

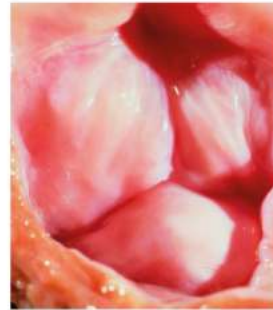counterpart, the tricuspid valve, has three. The two semilunar valves are at the exits from the ventricles: the pulmonary valve between the right ventricle and the pulmonary artery, and the aortic valve between the left ventricle and the aorta.



TWO CUSPS



THREE CUSPS



### PULMONARY VALVE

This valve lies between the right ventricle of the heart and the pulmonary artery. It opens as the right ventricle contracts and forces blood out of the heart towards the lungs.

### FUNCTION OF HEART VALVES


The tricuspid valve controls blood flow from the right atrium to the right ventricle; the pulmonary valve, from the right ventricle into the pulmonary artery; the mitral valve, from the left atrium to the left ventricle; and the aortic valve, from the left ventricle into the aorta.

### MITRAL VALVE

This image of a healthy human heart valve shows the heart strings (chordae tendinae) and valve cusps. The mitral valve lies between the left atrium and the left ventricle.



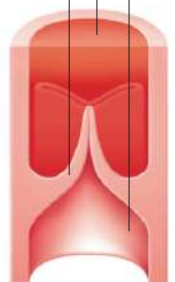
Direction of blood flow  
Valve cusp open  
Blood pushes against valve



### HEART VALVE OPEN

The flexible cusps are forced apart by the pressure of blood as the heart contracts.

Blood at high pressure  
Valve cusp shut  
Blood at low pressure

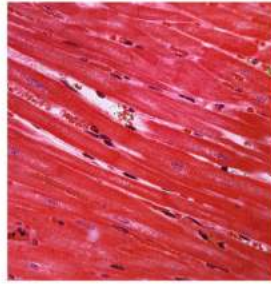


### HEART VALVE CLOSED

Back pressure causes the cusps to close and seal at their edges, to stop reverse blood flow.

## CARDIAC MUSCLE

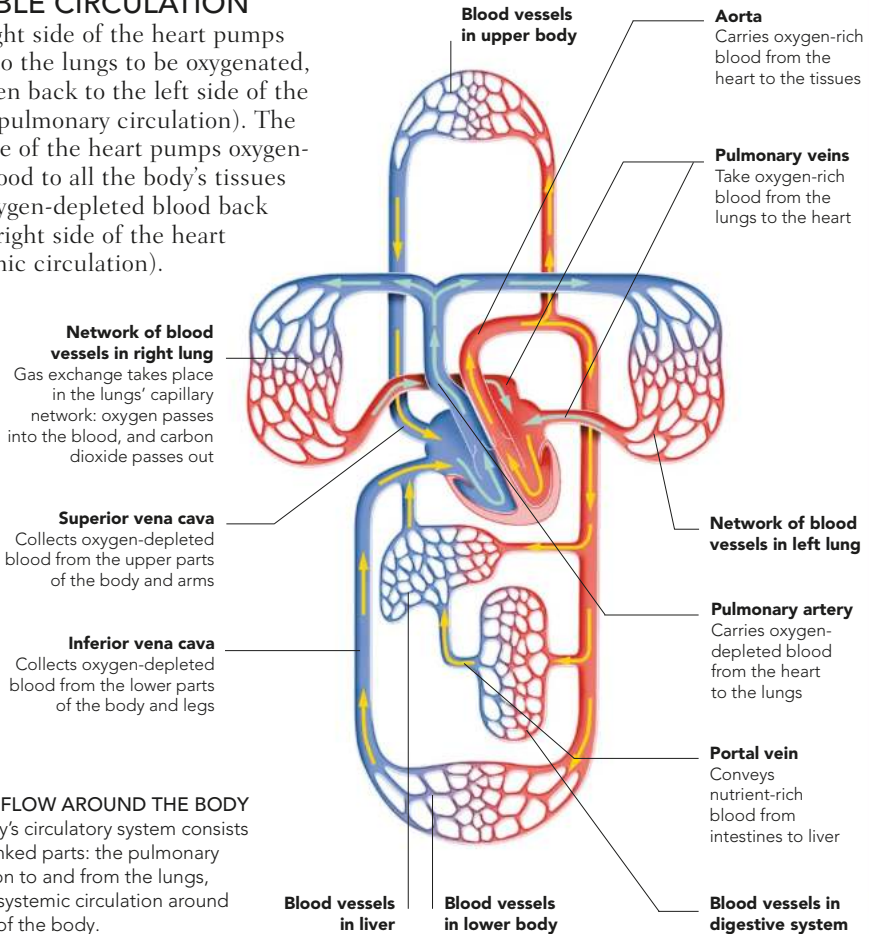
The walls of the heart are made of a special type of muscle known as cardiac muscle, which is found only in the heart. Unlike other types of muscle, cardiac muscle can contract repeatedly without becoming tired. However, to maintain this constant activity, the muscle requires a continuous, ample supply of oxygenated blood, provided by the coronary arteries.



**CARDIAC MUSCLE TISSUE**  
Cardiac muscle is a type of involuntary muscle, with short, branched, striated muscle fibres.

## DOUBLE CIRCULATION

The right side of the heart pumps blood to the lungs to be oxygenated, and then back to the left side of the heart (pulmonary circulation). The left side of the heart pumps oxygen-rich blood to all the body's tissues and oxygen-depleted blood back to the right side of the heart (systemic circulation).



## BLOOD FLOW AROUND THE BODY

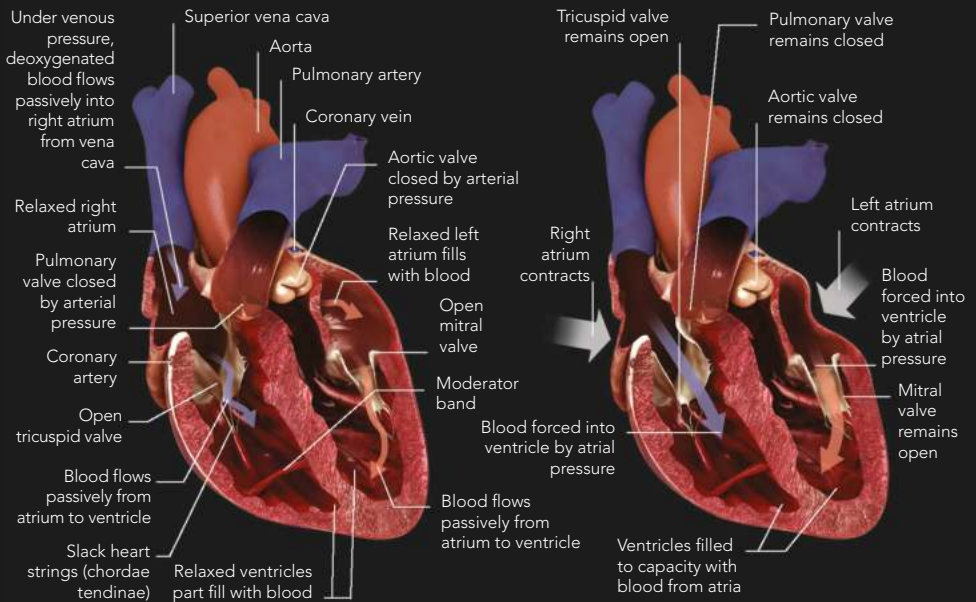
The body's circulatory system consists of two linked parts: the pulmonary circulation to and from the lungs, and the systemic circulation around the rest of the body.

# HOW THE HEART BEATS

THE HEART IS A DYNAMIC, UNTIRING, PRECISELY ADJUSTABLE DOUBLE-PUMP THAT FORCES BLOOD AROUND THE BODY'S IMMENSE NETWORK OF BLOOD VESSELS – PERHAPS MORE THAN THREE BILLION TIMES DURING A LIFETIME.

The heart's two lower chambers (ventricles) have thick, muscular walls that contract to squeeze blood into the arteries. The upper chambers (atria) have thinner walls and act partly as reservoirs for blood entering from the main veins. Each heartbeat has two main phases: in the first phase (diastole),

the heart relaxes and refills with blood; in the second phase (systole), it contracts, forcing the blood out. The whole cycle takes, on average, less than a second. During activity or stress, both the beating rate and the volume of blood pumped out of the heart increase greatly.



## 1 RELAXATION (LATE DIASTOLE)

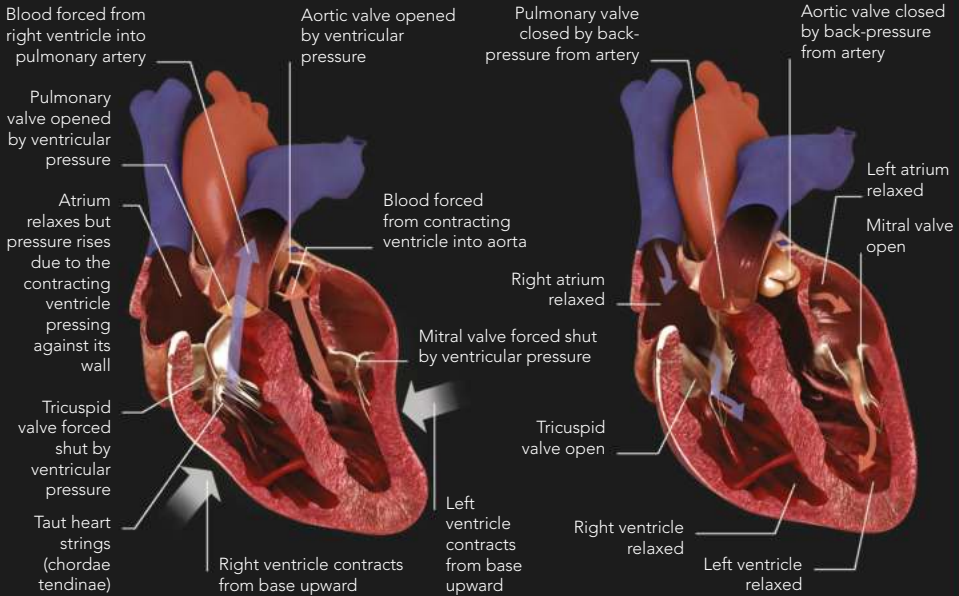
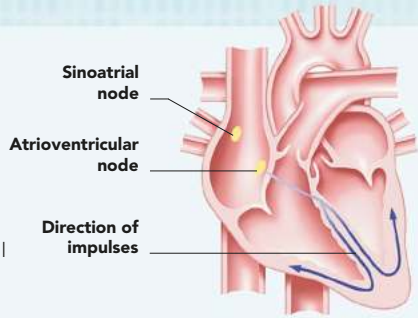
During this phase of the heartbeat sequence, the muscular walls of the heart relax. The atrial chambers balloon slightly as they fill with blood coming in under quite low pressure from the main veins. Deoxygenated blood from the body enters the right atrium, while oxygenated blood from the lungs enters the left atrium. Some of the blood in the atria flows down into the ventricles. By the end of this phase, the ventricles are filled to about 80 per cent of capacity.

## 2 CONTRACTION OF THE ATRIA (ATRIAL SYSTOLE)

The heart's natural pacemaker, known as the sinoatrial node, is located in the upper part of the right atrium. It "fires" electrical impulses, similar to those generated by nerves, which set off the contraction phase. Some impulses spread through the atrial walls and stimulate their cardiac muscle to contract. This contraction squeezes the blood inside the atria through the atrioventricular (tricuspid and mitral) valves into the ventricles, whose walls remain relaxed.

## HEARTBEAT SYNCHRONIZATION

Contractions of the atria and the ventricles are synchronized by electrical impulses from the sinoatrial node, the heart's natural pacemaker. Towards the end of diastole, the sinoatrial node sends out electrical impulses. These impulses travel through the atria, making them contract (atrial systole). Some impulses travel to the atrioventricular node, which sends them through conducting fibres to the ventricles, which contract in response (ventricular systole). The electrical impulses then travel back towards the atria. The sinoatrial node then fires again to continue the cycle.



### 3 CONTRACTION OF THE VENTRICLES (VENTRICULAR SYSTOLE)

During this most active and powerful stage of the heartbeat, the thick cardiac muscle in the ventricle walls contracts, stimulated by electrical impulses relayed by the atrioventricular node. This causes a rise in ventricular pressure, which opens the aortic and pulmonary valves at the exits of the ventricles. Blood is forced out into the main arteries, making the atrioventricular valves snap shut.

### 4 RELAXATION (EARLY DIASTOLE)

The walls of the ventricles begin to relax, causing ventricular pressure to reduce. The pressure of the recently ejected blood in the main arteries is now high, so both the aortic and pulmonary valves close. This prevents backflow into the ventricles. As ventricular pressure on the atrioventricular valves relaxes, the valves open. This reduces pressure in the atria, allowing blood to enter once again from the main veins.

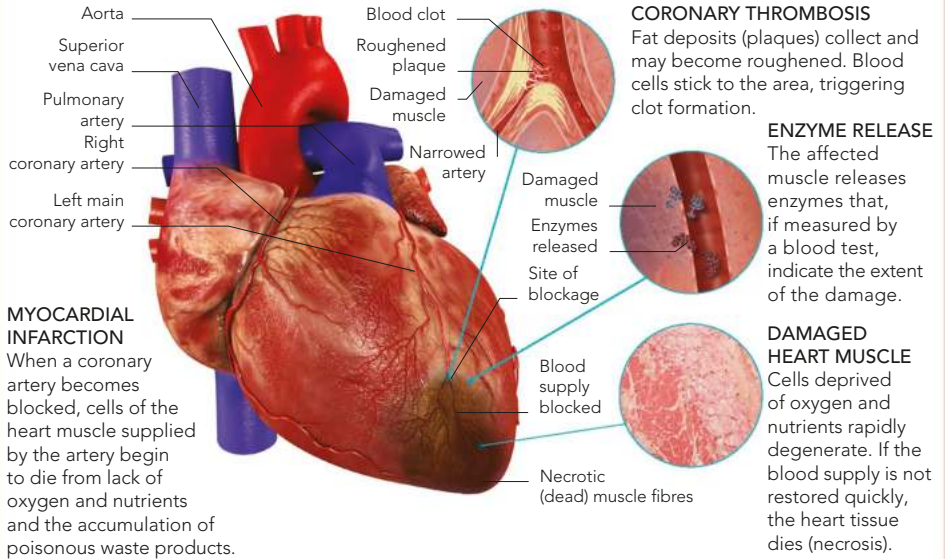
# CARDIOVASCULAR DISORDERS

DISORDERS OF THE CARDIOVASCULAR SYSTEM MAY AFFECT THE HEART ITSELF, CAUSING STRUCTURAL DAMAGE OR DISRUPTING HEART RHYTHM. BLOCKAGES IN BLOOD VESSELS CAN STARVE TISSUES OF OXYGEN, LEADING TO SERIOUS PROBLEMS ANYWHERE IN THE BODY.

## HEART ATTACK

A heart attack (myocardial infarction) is the result of coronary heart disease due to atherosclerosis (see opposite), and the subsequent formation of a blood clot, or thrombus. Once formed, the clot can completely block blood flow to an area of heart muscle, starving it of oxygen and eventually causing tissue death. If possible, the blood flow

must be restored to the damaged cells as quickly as possible. A heart attack usually occurs suddenly, with little or no warning. The chest pain is usually severe, is not necessarily brought on by exertion, and persists despite resting. A heart attack can also cause sweating, shortness of breath, nausea, and loss of consciousness.



## ANGINA

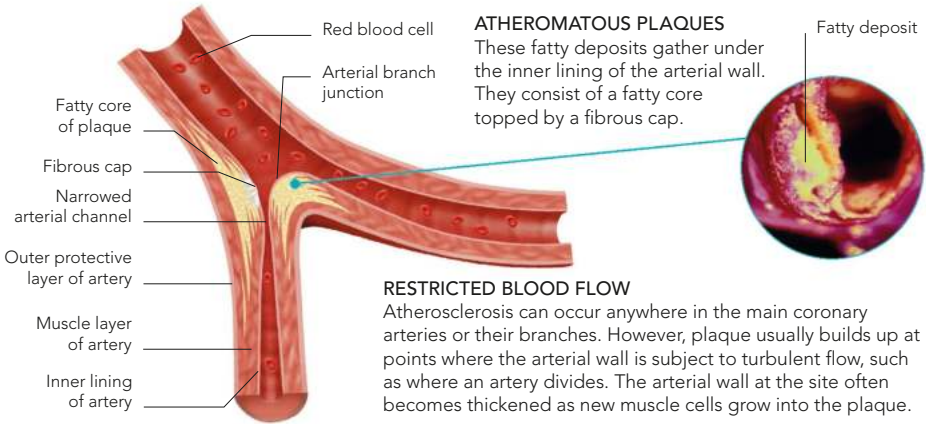
Angina is caused by a temporarily inadequate supply of blood to the heart muscle, usually because of arterial narrowing as a result of atherosclerosis (see opposite). The pain most often occurs when the heart's workload is increased, for example with exercise, and fades with rest. Other triggers of angina are stress, cold weather, or a

large meal. An attack of angina typically begins with a heavy, constricting pain behind the breastbone. This can spread into the throat and jaw, and down into the arms, especially the left one. The pain usually subsides within about 10-15 minutes. People with angina often take medication to dilate (widen) the coronary arteries.

## ATHEROSCLEROSIS

The process that leads to atherosclerosis begins with abnormally high levels of excess fats and cholesterol in the blood. These substances infiltrate the lining of arteries, forming deposits known as atheroma. This can happen in any of the body's arteries, including those supplying the brain with blood, when the result may be a stroke. The atheromatous deposits gradually form raised patches known as plaques. These consist of

fatty cores within the arterial wall, covered by fibrous caps. The plaques narrow the space within the artery, restricting the overall flow of blood to tissues beyond the site. They also cause turbulence that disrupts the flow of blood, and the eddies over the plaque surface make the blood more likely to clot. The major risk factors for atherosclerosis include smoking, a diet high in saturated fats, lack of exercise, and excess weight.



### ATHEROMATOUS PLAQUES

These fatty deposits gather under the inner lining of the arterial wall. They consist of a fatty core topped by a fibrous cap.

### RESTRICTED BLOOD FLOW

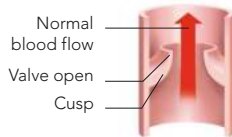
Atherosclerosis can occur anywhere in the main coronary arteries or their branches. However, plaque usually builds up at points where the arterial wall is subject to turbulent flow, such as where an artery divides. The arterial wall at the site often becomes thickened as new muscle cells grow into the plaque.

## VALVE DISORDERS

There are two main types of heart valve disorder: stenosis and incompetence.

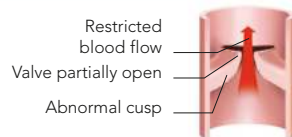
In stenosis, the valve outlet is too narrow and so restricts blood flow. The condition may be congenital (present at birth), due to an infection such as rheumatic fever, or part of the ageing process. In incompetence, the heart valve does not close fully, allowing backflow of blood.

This problem can result from a heart attack or an infection of the valve.



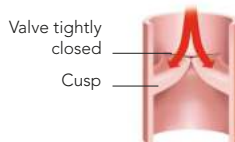
### NORMAL VALVE OPEN

As the heart contracts, the high pressure pushes the cusps of the valve open, allowing blood to flow.



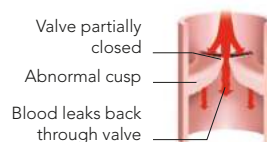
### STENOSIS

The valve stiffens and cannot open fully. Blood flow is restricted, so the heart beats harder to compensate.



### NORMAL VALVE CLOSED

The pressure on the other side of the valve increases and the valve cusps snap shut, preventing backflow.

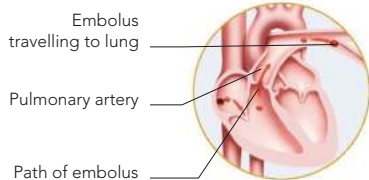


### INCOMPETENCE

The cusps do not close properly, and blood leaks backward. The heart must work harder to circulate blood.

## EMBOLISM

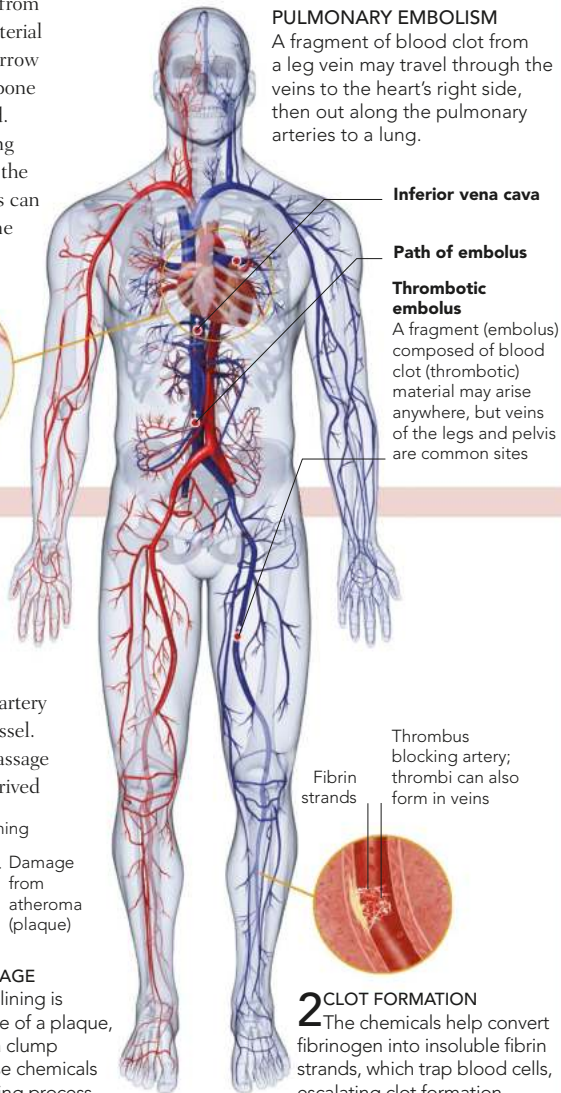
Most emboli are fragments of a blood clot (thrombus), or even a whole clot, that has detached from its original site and travelled in the bloodstream to lodge in a blood vessel. An embolus may also be made of fatty material from an atheromatous plaque (see p.157) in an arterial wall, crystals of cholesterol, fatty bone marrow that has entered the circulation following a bone fracture, or an air bubble or amniotic fluid. In a pulmonary embolism, a clot originating elsewhere in the body travels in the veins to the lungs. Clots that form in the heart or arteries can block the blood circulation anywhere in the body. An embolus is most likely to block a



blood vessel where it narrows or branches, depriving the tissues of oxygen beyond the site of the blockage. The symptoms of an embolism depend on the site affected.

### PULMONARY EMBOLISM

A fragment of blood clot from a leg vein may travel through the veins to the heart's right side, then out along the pulmonary arteries to a lung.

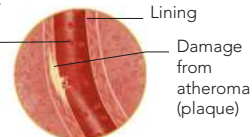


## THROMBOSIS

Thrombosis is the blockage of a blood vessel by a blood clot. It is most likely to occur where normal blood flow is disrupted, which may be due to plaques of fatty atheromatous tissue in the walls of an artery (see p.157) or inflammation of the blood vessel. The clot eventually narrows or blocks the passage for blood so that the tissues beyond are deprived of oxygen and nutrients.

### THROMBUS FORMATION

Thrombosis can occur in arteries and veins, but commonly happens at a site of atherosclerosis in an artery wall, which disrupts the normal blood flow.



**1 INTERNAL DAMAGE**  
When an artery lining is damaged by rupture of a plaque, platelets in the area clump together and release chemicals that begin the clotting process.

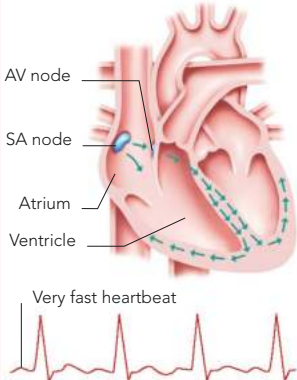
**2 CLOT FORMATION**  
The chemicals help convert fibrinogen into insoluble fibrin strands, which trap blood cells, escalating clot formation.



## ARRHYTHMIA

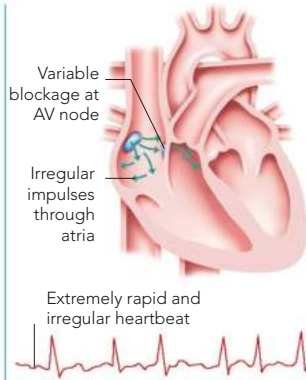
An arrhythmia is a heart rate that is unusually slow or fast, or erratic. A normal heartbeat is initiated by specialized cells in the natural “pacemaker”, the sinoatrial (SA) node, at the top of the right atrium. They send electrical impulses out through the atrial muscle tissue, stimulating it to contract.

These signals are relayed by the atrioventricular (AV) node along nerve-like fibres through the septum (central dividing wall) and into the thick muscle tissue of the ventricle walls. A fault in the system can lead to various arrhythmias, including those described here.



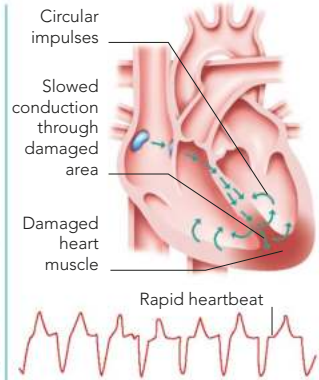
### SINUS TACHYCARDIA

In sinus tachycardia there is a regular but rapid heart rate, usually more than 100 beats per minute.



### ATRIAL FIBRILLATION

Fibrillations are rapid, disordered, weak contractions with a rate as high as 500 per minute.



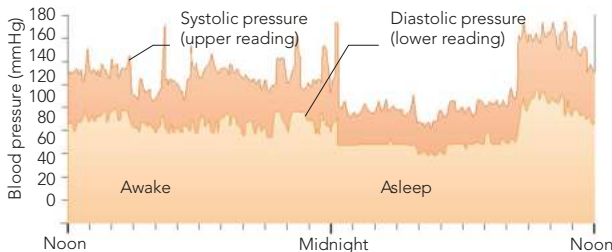
### VENTRICULAR TACHYCARDIA

Very fast ventricular contractions may be caused by heart muscle damage, for example due to a heart attack.

## HYPERTENSION

Blood is under pressure as the heart pumps it around the circulation. In hypertension, this pressure is persistently above normal limits. There are no symptoms of hypertension at first, but despite this, over time it increases the risk of many serious disorders, such as stroke, heart disease, and kidney failure. Contributing factors

to hypertension include certain genetic influences and diet and lifestyle factors, such as being overweight, drinking excessive amounts of alcohol, smoking, and having a high-salt diet. Hypertension is most common in middle-aged and elderly people. A stressful lifestyle may aggravate the condition.



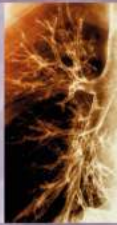### BLOOD PRESSURE GRAPH

Normal blood pressure varies according to activity levels. This graph shows that during sleep, both the systolic and diastolic pressures (see pp.154–155) are much lower.



OXYGEN IS VITAL FOR LIFE. THE RESPIRATORY SYSTEM TRANSFERS OXYGEN FROM THE AIR TO THE BLOOD, SO THE CARDIOVASCULAR SYSTEM CAN DISTRIBUTE IT, WHILE THE MUSCULAR AND SKELETAL SYSTEMS DRIVE THE MOVEMENTS OF BREATHING. THE AIR IS OFTEN CONTAMINATED WITH DUST PARTICLES, HARMFUL MICROBES, ALLERGENS, IRRITANTS, AND CANCER-CAUSING CHEMICALS. ALL OF THESE CAN DAMAGE THE SYSTEM'S DELICATE PARTS, MAKING RESPIRATORY DISORDERS AMONG THE MOST COMMON ILLNESSES.

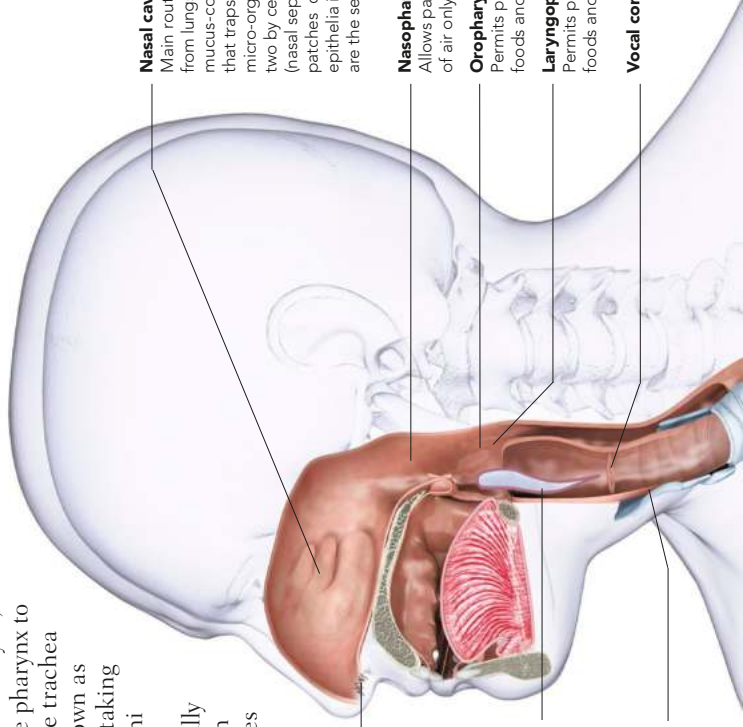
# RESPIRATORY SYSTEM



# RESPIRATORY ANATOMY

THE RESPIRATORY SYSTEM, IN CLOSE CONJUNCTION WITH THE CIRCULATORY SYSTEM, IS RESPONSIBLE FOR SUPPLYING ALL BODY CELLS WITH ESSENTIAL OXYGEN AND REMOVING POTENTIALLY HARMFUL CARBON DIOXIDE FROM THE BODY.

Air enters the body mainly through the nostrils. The nostrils lead into the nasal cavity, which joins with the pharynx (throat). The larynx, home to the vocal cords, joins the pharynx to the trachea (windpipe). The trachea splits into two airways, known as the primary bronchi, each taking air to one lung. The bronchi divide into secondary and tertiary bronchi, and eventually into minute bronchioles. In the lungs, exchange of gases takes place in tiny sacs called alveoli.



## Nasal cavity

Main route for air to and from lungs; lined with a sticky, mucus-covered membrane that traps dust particles and micro-organisms; divided into two by central plate of cartilage (nasal septum); also contains patches called olfactory epithelia in roof of cavity, which are the sensory organs of smell

## Nasopharynx

Allows passage of air only

## Oropharynx

Permits passage of foods and fluids

## Laryngopharynx

Permits passage of foods and fluids

## Vocal cord

## Pharynx

Short tube that begins at rear of nasal cavity and ends at larynx (voice box)

## Nose hairs

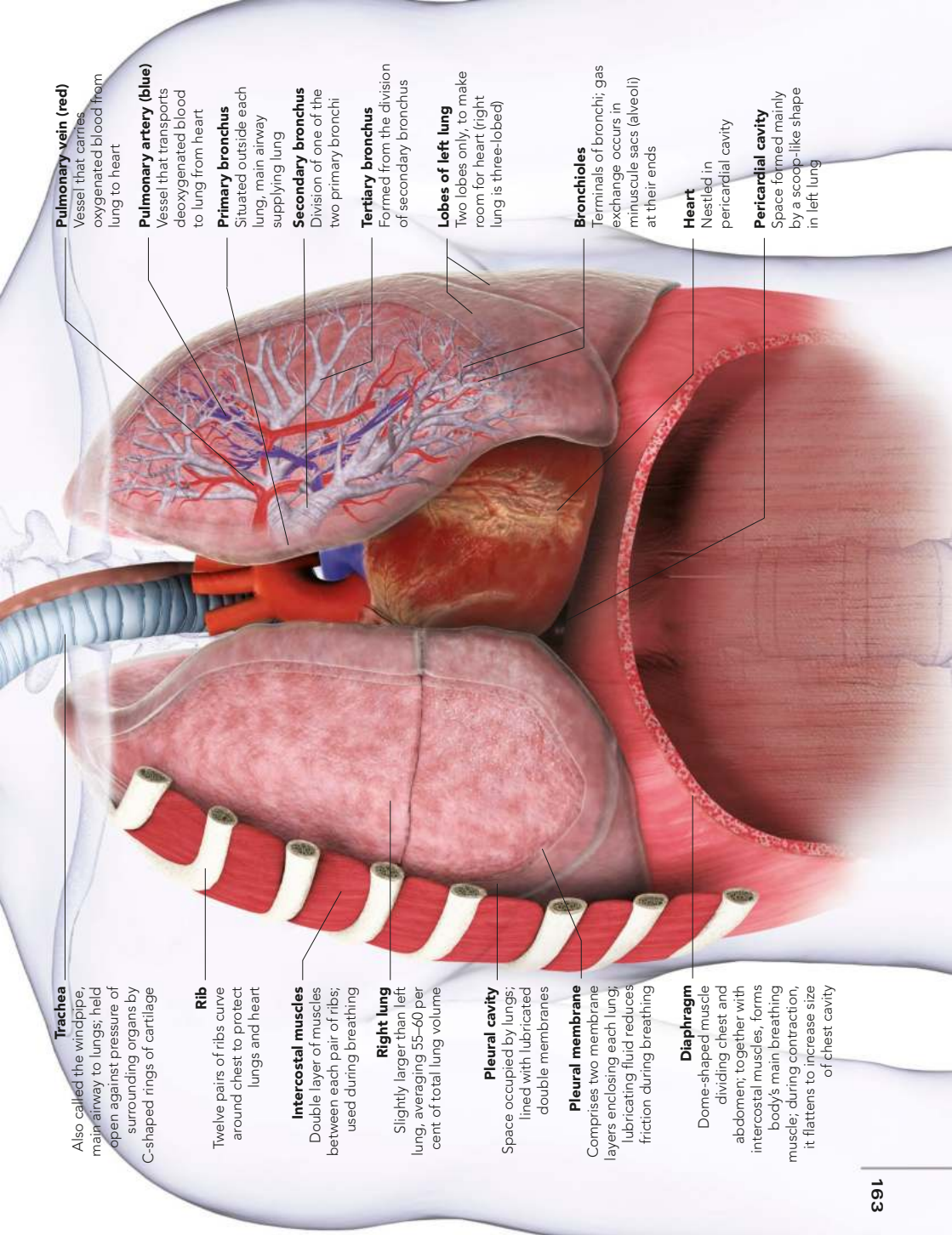
Situated inside entrance of nostrils; help to filter out large particles of dust and debris

## Epiglottis

Cartilage flap that tilts over entrance to larynx when swallowing, to prevent food, drink, and saliva entering trachea

## Larynx

Short, cartilaginous tube joining pharynx with trachea; together with vocal cords within it, the larynx plays a vital role in speech production



### Trachea

Also called the windpipe, main airway to lungs; held open against pressure of surrounding organs by C-shaped rings of cartilage

### Rib

Twelve pairs of ribs curve around chest to protect lungs and heart

### Intercostal muscles

Double layer of muscles between each pair of ribs; used during breathing

### Right lung

Slightly larger than left lung, averaging 55–60 per cent of total lung volume

### Pleural cavity

Space occupied by lungs; lined with lubricated double membranes

### Pleural membrane

Comprises two membrane layers enclosing each lung; lubricating fluid reduces friction during breathing

### Diaphragm

Dome-shaped muscle dividing chest and abdomen; together with intercostal muscles, forms body's main breathing muscle; during contraction, it flattens to increase size of chest cavity

### Pulmonary vein (red)

Vessel that carries oxygenated blood from lung to heart

### Pulmonary artery (blue)

Vessel that transports deoxygenated blood to lung from heart

### Primary bronchus

Situated outside each lung, main airway supplying lung

### Secondary bronchus

Division of one of the two primary bronchi

### Tertiary bronchus

Formed from the division of secondary bronchus

### Lobes of left lung

Two lobes only, to make room for heart (right lung is three-lobed)

### Bronchioles

Terminals of bronchi; gas exchange occurs in minuscule sacs (alveoli) at their ends

### Heart

Nested in pericardial cavity

### Pericardial cavity

Space formed mainly by a scoop-like shape in left lung

# LUNGS

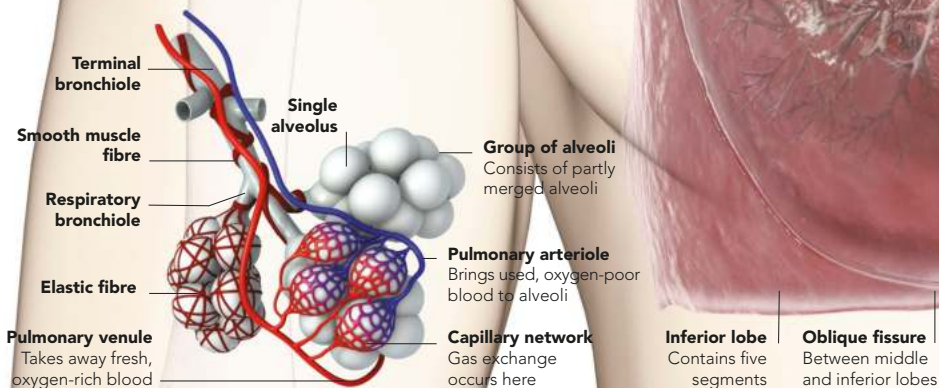
THE TWO SPONGE-LIKE LUNGS FILL MOST OF THE CHEST CAVITY AND ARE PROTECTED BY THE RIBS. THEIR ESSENTIAL FUNCTION IS GAS EXCHANGE – TAKING IN VITAL OXYGEN FROM THE AIR AND EXPELLING WASTE CARBON DIOXIDE.

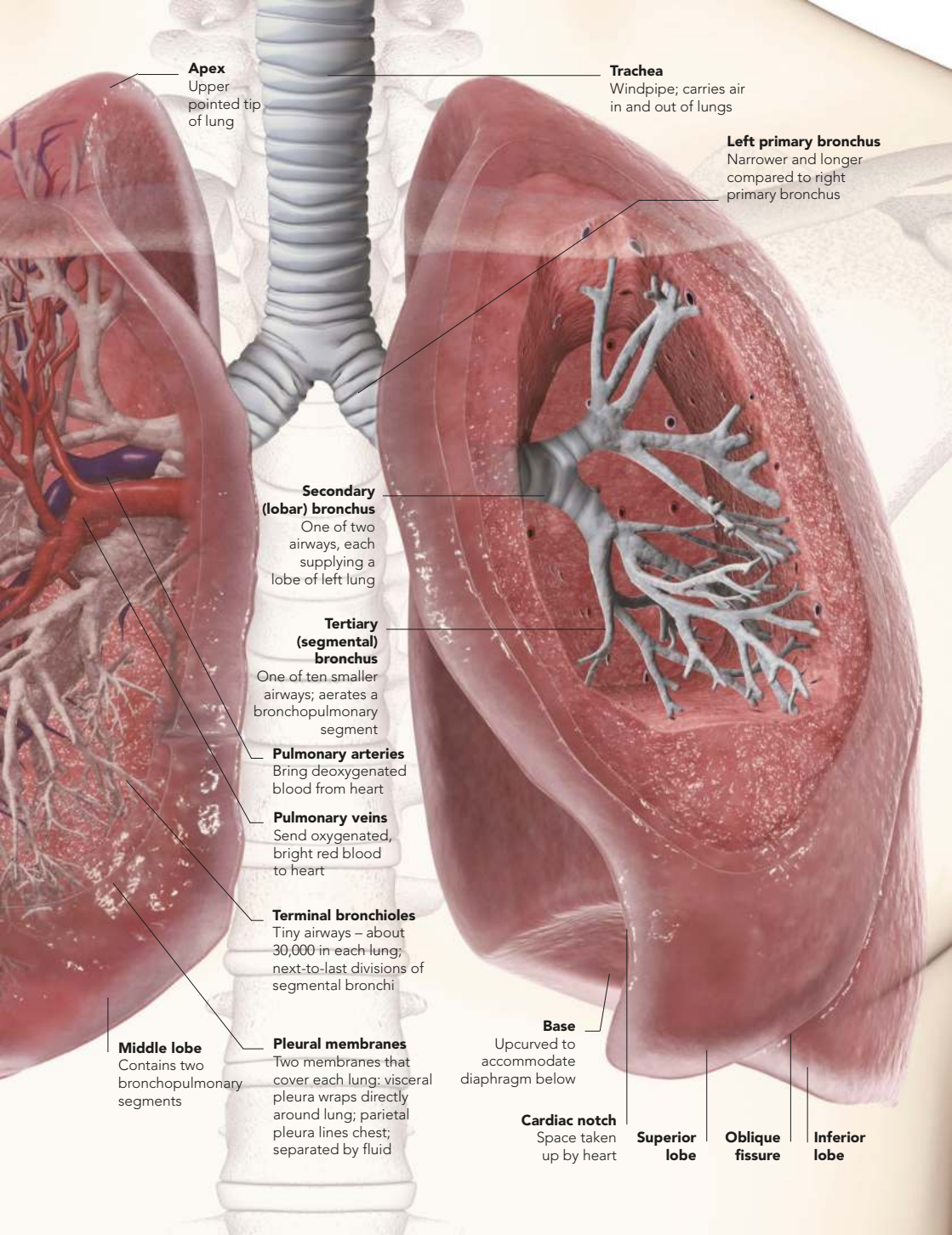
## LUNG STRUCTURE

Air enters the lungs from the trachea, which branches at its base into two main airways, the primary bronchi. Each primary bronchus enters its lung at a site called the hilum, which is also where the main blood vessels pass in and out of the lung. The primary bronchus divides into secondary bronchi, and these subdivide into tertiary bronchi, all the time decreasing in diameter. Many subsequent divisions form the narrowest airways: the terminal and then respiratory bronchioles, which distribute air to the alveoli.

## ALVEOLI

The lungs' microscopic air sacs, known as alveoli, are elastic, thin-walled structures arranged in clumps at the ends of respiratory bronchioles. Around the alveoli are networks of capillaries. Oxygen passes from the air in the alveoli into the blood by diffusion through the alveolar and capillary walls (see p.166). Carbon dioxide diffuses from the blood into the alveoli. There are more than 300 million alveoli in both lungs, providing a huge surface area for gas exchange.





**Apex**  
Upper pointed tip of lung

**Trachea**  
Windpipe; carries air in and out of lungs

**Left primary bronchus**  
Narrower and longer compared to right primary bronchus

**Secondary (lobar) bronchus**  
One of two airways, each supplying a lobe of left lung

**Tertiary (segmental) bronchus**  
One of ten smaller airways; aerates a bronchopulmonary segment

**Pulmonary arteries**  
Bring deoxygenated blood from heart

**Pulmonary veins**  
Send oxygenated, bright red blood to heart

**Terminal bronchioles**  
Tiny airways – about 30,000 in each lung; next-to-last divisions of segmental bronchi

**Middle lobe**  
Contains two bronchopulmonary segments

**Pleural membranes**  
Two membranes that cover each lung; visceral pleura wraps directly around lung; parietal pleura lines chest; separated by fluid

**Base**  
Upcurved to accommodate diaphragm below

**Cardiac notch**  
Space taken up by heart

**Superior lobe**

**Oblique fissure**

**Inferior lobe**

# GAS EXCHANGE

THE BODY CANNOT STORE OXYGEN AND NEEDS CONTINUING SUPPLIES. IT ALSO CONSTANTLY PRODUCES CARBON DIOXIDE AS A WASTE PRODUCT. GAS EXCHANGE SWAPS OXYGEN AND CARBON DIOXIDE IN THE LUNGS AND TISSUES.

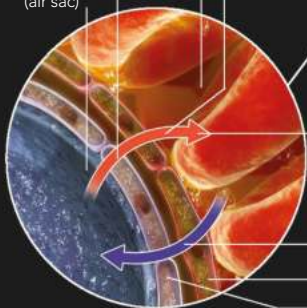Oxygen is drawn into the body by the expanding lungs. When it reaches the ends of the lungs' airways, the gas dissolves into the fluid lining the alveoli (air sacs). It passes into the blood for distribution to each body cell. Inside cells, the oxygen reacts with glucose to free its energy. Toxic carbon dioxide is a byproduct of the process, but gas exchange discharges it into the air. In the lungs and body tissues, gases pass by diffusion: flowing from regions of high to low density.

**1** Oxygen in air dissolves into fluid lining the alveolus and diffuses through alveolar wall and blood capillary wall

**2** Oxygen enters blood plasma inside capillary

Fluid-lined alveolus (air sac)

Blood capillary



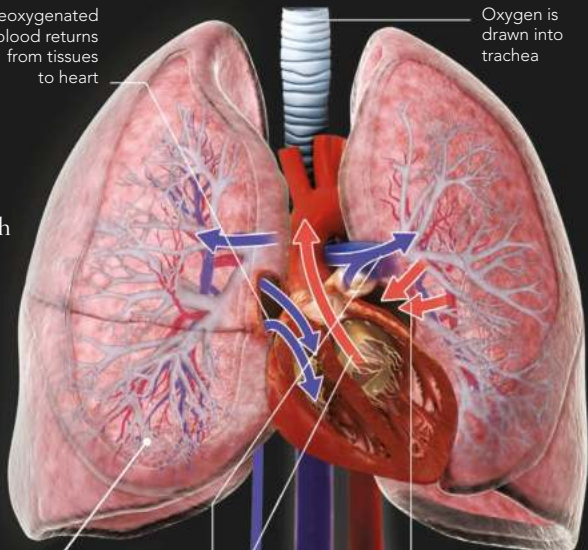
**3** Oxygen quickly bonds to haemoglobin in red blood cells

**4** Carbon dioxide diffuses out of blood plasma and enters air in alveolus

Cell of capillary wall  
Cell of alveolar wall

Deoxygenated blood returns from tissues to heart

Oxygen is drawn into trachea



Heart pumps deoxygenated blood into lungs

Oxygen-rich blood leaves heart

Oxygen-rich blood returns to heart

**5** Oxygenated blood leaves heart along the aorta (the body's main artery) and circulates to body tissues

## EXCHANGE IN THE LUNGS

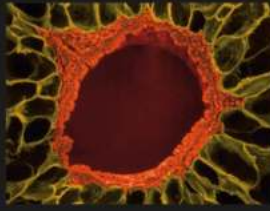
When fresh, oxygen-rich air reaches the alveoli – the tiny dead-end air spaces in the lungs – it must pass through several layers to reach the red cells in the blood. But these layers are so thin that the total distance is only 0.001mm ( $\frac{1}{2500}$  in).

Lower vena cava (one of the body's two main veins) returns deoxygenated blood from lower body to heart



## EXCHANGE IN THE BODY TISSUES

Oxygen levels are higher in the blood than in surrounding tissues. The difference in levels forces oxygen to break its bonds to the haemoglobin in red blood cells and diffuse out of the blood into the adjacent cells. The reverse applies to carbon dioxide, which diffuses from the tissue into the blood plasma.



## BRONCHIOLE AND ALVEOLI

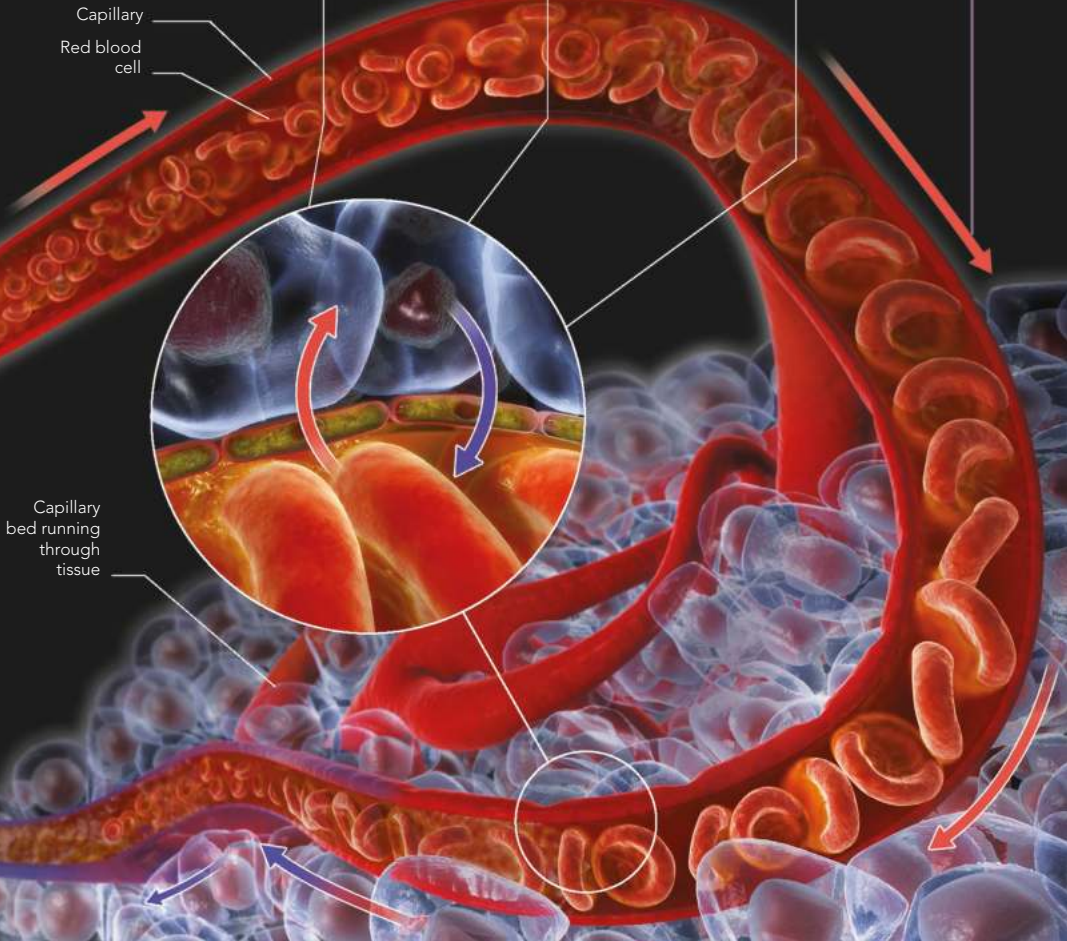
This microview shows a cross-sectioned bronchiole (red) surrounded by alveoli that have been cut through, so that they resemble air bubbles in a sponge.

**6** Oxygenated blood is carried through tissues in capillaries thinner than hair

**7** Arriving red blood cells are rich in oxygen, which is bound to haemoglobin in the body of each cell

**8** Oxygen leaves the haemoglobin within the blood cells, and diffuses across capillary walls and into tissue cells

**9** Carbon dioxide diffuses out of tissue cells, across wall of blood capillary, and into blood plasma



# BREATHING AND VOCALIZATION

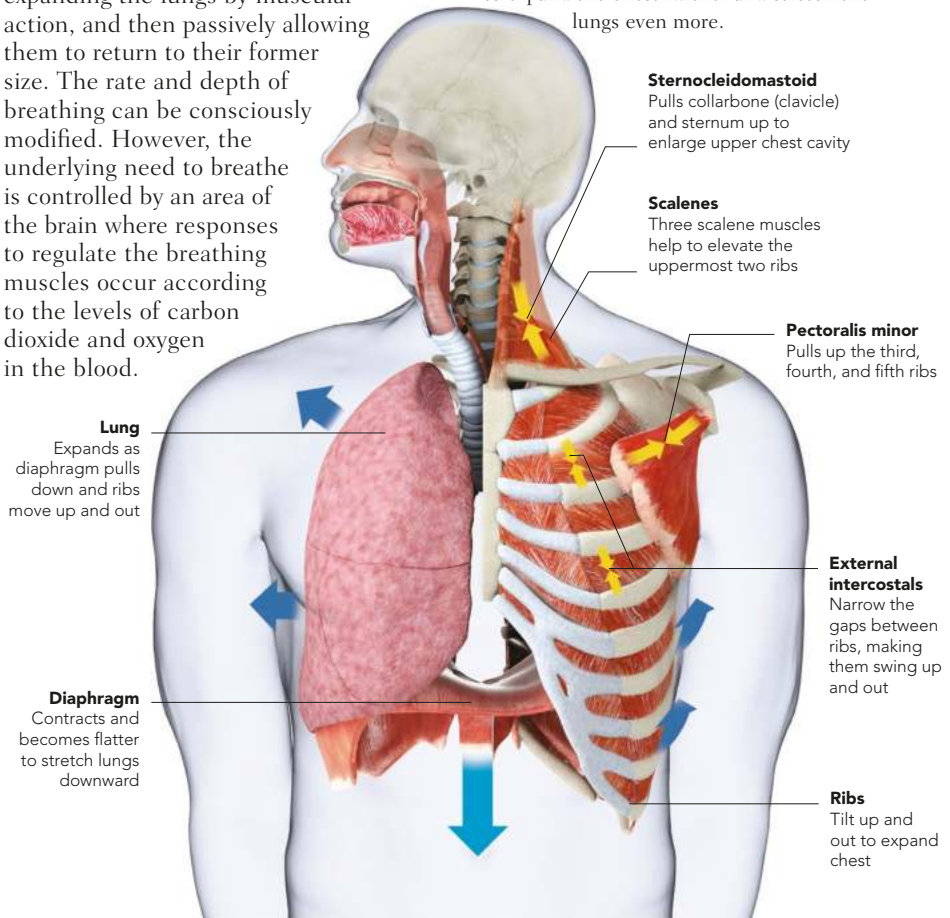
THE MOVEMENTS OF BREATHING, ALSO KNOWN AS BODILY RESPIRATION, BRING FRESH AIR CONTAINING OXYGEN DEEP INTO THE LUNGS AND THEN REMOVE STALE AIR CONTAINING THE WASTE PRODUCT CARBON DIOXIDE.

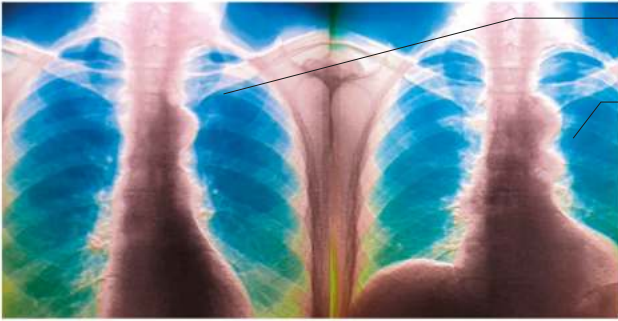
## BREATHING

The movement of air into and out of the lungs is generated by differences in pressure within the lungs compared to the surrounding atmospheric pressure. These differences are produced by forcefully expanding the lungs by muscular action, and then passively allowing them to return to their former size. The rate and depth of breathing can be consciously modified. However, the underlying need to breathe is controlled by an area of the brain where responses to regulate the breathing muscles occur according to the levels of carbon dioxide and oxygen in the blood.

## INHALATION

The chief muscles used in respiration at rest are the diaphragm at the base of the chest and the external intercostals between the ribs. For forceful inhalation, additional muscles assist in moving the ribs and sternum to expand the chest further and stretch the lungs even more.





Chest cavity expands as diaphragm and intercostal muscles contract

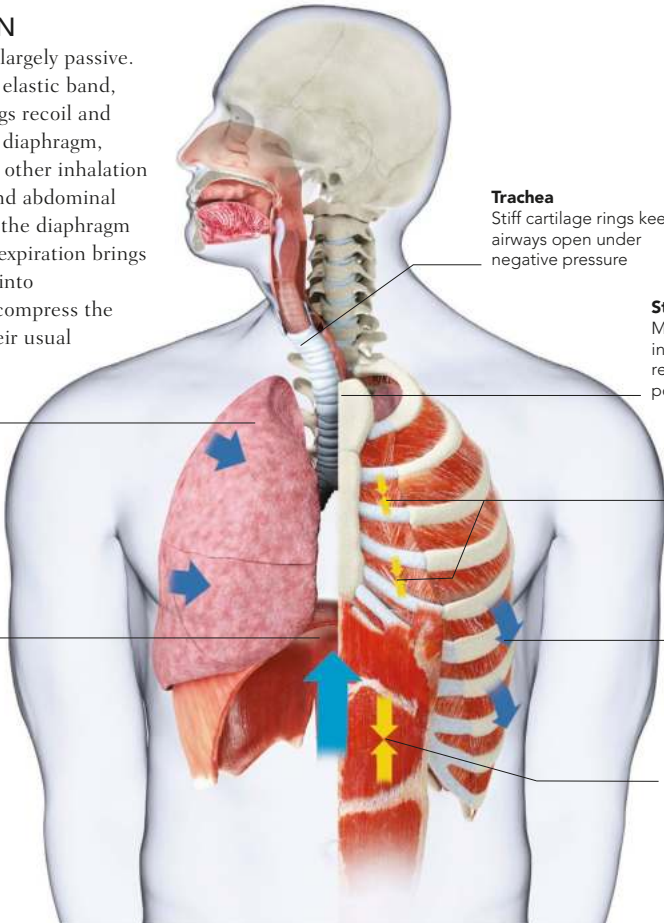
Chest cavity decreases in size as diaphragm and intercostal muscles relax

**DIAPHRAGM MOVEMENT**

The abdominal contents (dark area at the bottom of this X-ray) are flattened by the diaphragm muscle during inhalation (left) and then rise up during exhalation (right).

**EXHALATION**

Breathing out is largely passive. Like a stretched elastic band, the enlarged lungs recoil and shrink when the diaphragm, intercostals, and other inhalation muscles relax, and abdominal pressure pushes the diaphragm upward. Forced expiration brings further muscles into play, to actively compress the lungs beyond their usual resting volume.



**Lung**  
Shrinks with diminishing chest cavity volume

**Diaphragm**  
Relaxes and pushes up into dome shape

**Trachea**  
Stiff cartilage rings keep airways open under negative pressure

**Sternum**  
Moves down and inward as ribs return to resting position

**Internal intercostals**  
Pull ribs down for forced exhalation

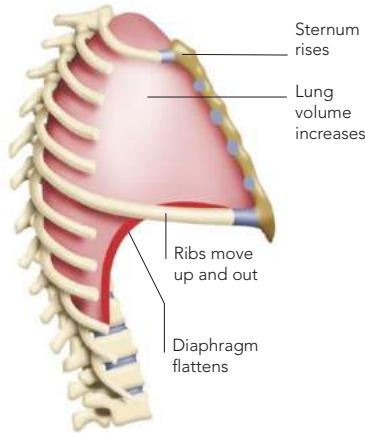
**Ribs**  
Are drawn in and tilt down

**Rectus abdominis**  
Pulls on ribs five to seven and sternum, to depress ribcage and assist expiration

## VOLUME AND PRESSURE

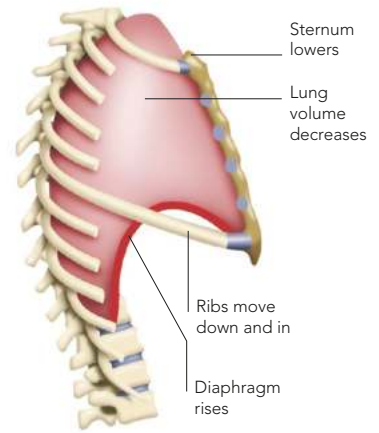
Breathing alters the volume of the chest (thoracic cavity). The lungs “suck” on to the inner chest wall, so that as the cavity expands, they also become larger. The main expanding forces are provided by the diaphragm and intercostal muscles. At rest, the diaphragm carries out most of the work, as 0.5 litres (17fl oz) of air – the tidal volume – shifts in and out with each breath (12 to 17 times every minute). Rate

and volume increase automatically if the body needs more oxygen, as during exercise. Then forced inspiration can suck in an extra 2 litres (70fl oz), and forced expiration expels almost as much, leading to a total air shift, or vital capacity, of more than 4.5 litres (150fl oz) in a large, healthy adult. The breathing rate can triple, producing a total air exchange more than 20 times greater than at rest.



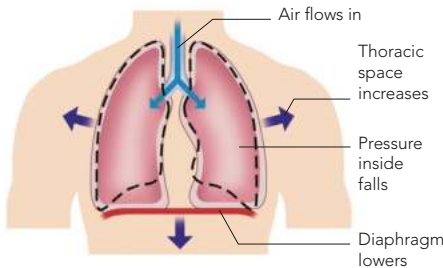
### BREATHING IN

The diaphragm contracts to become less dome-like, while the ribs swing upward and outward with a “bucket handle” action to raise the sternum.



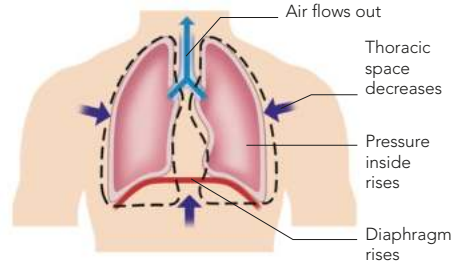
### BREATHING OUT

The diaphragm relaxes, and the elastic, stretched lungs recoil to become smaller again, allowing the sternum and ribs to move down and inward.



### NEGATIVE PRESSURE

As the lung volume increases, the air pressure within decreases. Atmospheric pressure outside the body is now higher, and air is drawn down the airways and into the lungs – in effect, air is “sucked” in.

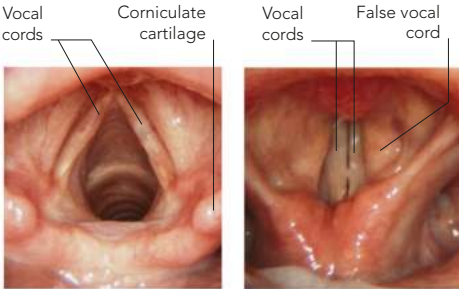


### POSITIVE PRESSURE

As the lung volume diminishes when exhaling, the air is compressed, which raises its pressure within the lungs. So the air is pushed back along the airways and out of the nose and mouth.

## VOCALIZATION

The vocal cords are two bands of fibrous tissue within the larynx. During breathing they are separated by a V-shaped gap (the glottis). Sound is produced when the cords tighten together and vibrate as air from the lungs passes between them. Pitch varies according to the tension in the cords. The false vocal cords above help to close off the larynx during swallowing.



### CORDS APART

A laryngoscope view shows the vocal cords during normal breathing, when air passes through the gap between them.

### CORDS ADJACENT

Laryngeal muscles swing the arytenoid cartilages, to which the vocal cords are attached, and bring them together.

## RESPIRATORY REFLEXES

The respiratory reflexes of coughing and sneezing aim to blow out excess mucus, dust, irritants, and obstructions – coughing from the lower pharynx, larynx, trachea, and lung airways, and sneezing from the nasal chambers and nasopharynx. For a cough, the lower pharynx, epiglottis, and larynx close so that air pressure builds up in the lungs, and is released explosively, rattling the vocal cords. In a sneeze, the tongue closes off the mouth, to force air up and out through the nose.



### MUCUS SPRAY

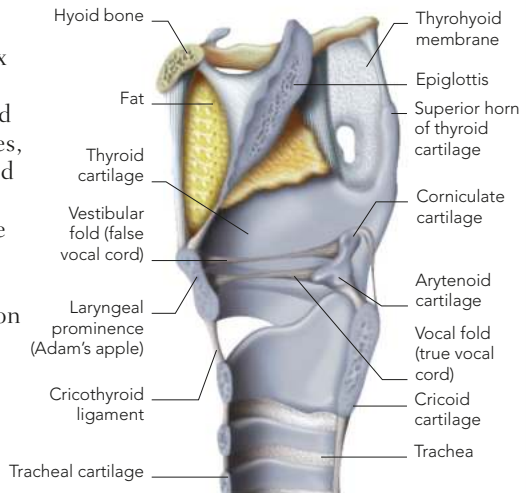
Coughs (as shown here) and sneezes propel a spray of tiny mucus droplets from the respiratory airways for distances of up to 3m (10ft).

## THE LARYNX

The larynx is sited between the pharynx and the trachea. It has a framework of nine cartilages, comprising the paired arytenoids, cuneiforms, and corniculates, and the unpaired epiglottic, thyroid, and cricoid. The thyroid cartilage forms a prominent mound under the skin of the neck, called the “Adam’s apple”, which is larger and more pronounced in adult males. The cartilages are held in position by numerous muscles and ligaments.

### INTERNAL STRUCTURE

The larynx forms a hollow chamber through which air flows silently during normal breathing. The areas of cartilage tilt to bring the vocal cords together for speech.



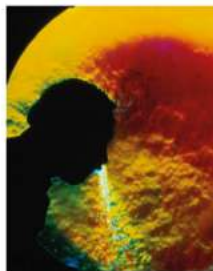
# RESPIRATORY DISORDERS

MILLIONS OF MICROBES FLOAT IN THE AIR, AND EACH BREATH BRINGS THOSE PARTICLES INTO THE RESPIRATORY TRACT, HEIGHTENING THE RISK OF A RESPIRATORY INFECTION. OTHER TYPES OF RESPIRATORY DISORDER INCLUDE DAMAGE CAUSED BY ALLERGIES OR IRRITANTS, AND CANCERS.

## COMMON COLD

The common cold is one of the most frequently experienced illnesses but also generally one of the less serious. At least 200 different and highly contagious types of virus can cause the problem. They spread in fluid that floats through air, in tiny droplets of mucus coughed or sneezed out by people with colds, and also in films of moisture transferred from person to person by close contact, such as shaking hands, or via shared objects, such as cups. Symptoms involve frequent sneezing, a runny nose, which at first runs with a clear, thin

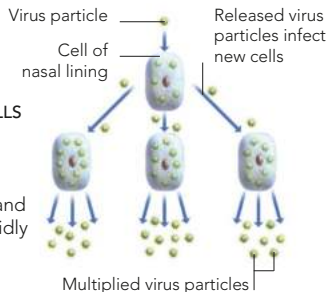
discharge that may later become thicker and greenish-yellow, a headache, slightly raised temperature, and perhaps a sore throat, cough, and reddened eyes. Antibiotic drugs are ineffective as they do not work against viruses. Cold viruses change (mutate) so rapidly that even if antiviral drugs could be made to tackle existing strains, they would be ineffective against the new ones. Most cold remedies, such as decongestants and inhalants, treat the symptoms while the body's immune system attacks the invading microbes.



**SPREADING INFECTION**  
Coughs and sneezes can rapidly spread common cold viruses by spraying them up to 3m (10ft) in mucous droplets.

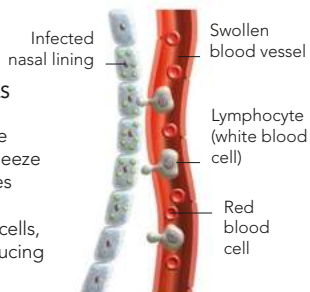
### 1 VIRUS INVADES CELLS

Virus particles in air land on and invade the cells lining the nose and throat. They rapidly replicate, killing their host cells.



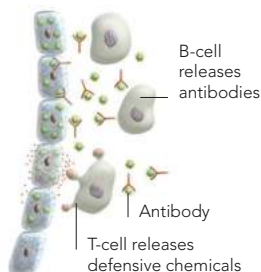
### 2 WHITE CELLS ARRIVE

Defensive white blood cells squeeze out of capillaries towards the infected lining cells, which are producing thin mucus.



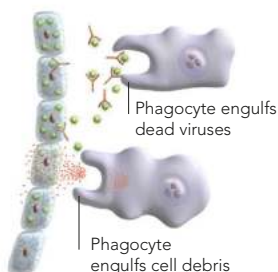
### 3 ANTIBODY PRODUCTION

White blood cells known as B-cells produce antibodies, which immobilize the virus; other white blood cells destroy infected cells.



### 4 CLEARING UP

Other white blood cells called phagocytes engulf virus particles, damaged nasal lining cells, and other debris. The cold subsides.

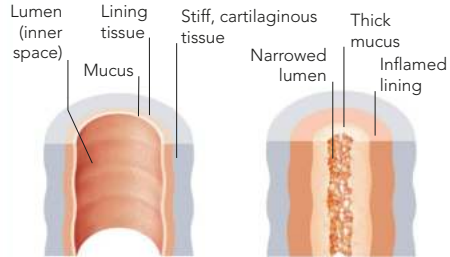


## INFLUENZA

Influenza is primarily an upper respiratory tract infection, but it also has body-wide symptoms: raised temperature, sensations of being hot and sweaty and then cold with shivers, muscle aches, and exhaustion. Even after the main infection has cleared up, there may be lingering depression and fatigue. The influenza viruses are coded A, B, and C and are very contagious. Influenza A tends to produce regular outbreaks and can also affect domestic animals such as pigs, horses, and fowl. Influenza B usually causes more sporadic outbreaks in places where many people gather and interact. Influenza C is less likely to produce serious symptoms. The type A virus is most likely to change or mutate. People at risk of dangerous complications, such as the very young or elderly, can be vaccinated before the main risk time of the winter season. Because the virus can mutate, new vaccines are prepared annually.

## ACUTE BRONCHITIS

Bronchitis is inflammation of the larger airways (bronchi) in the lungs. The disorder may be a complication of a respiratory infection. Its acute form develops rapidly, with symptoms including a sputum-producing cough, tight chest, wheezing, and mild fever. Healthy adults usually recover in a few days.



### NORMAL BRONCHUS

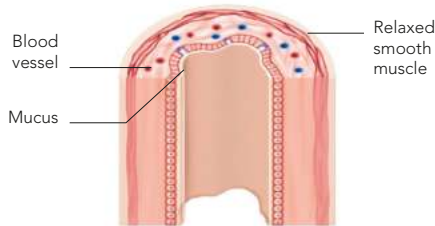
The airway lining secretes a thin layer of mucus. The passageway (lumen) allows free air flow.

### INFLAMED BRONCHUS

The airway lining swells and produces excess mucus, which may be coughed up.

## ASTHMA

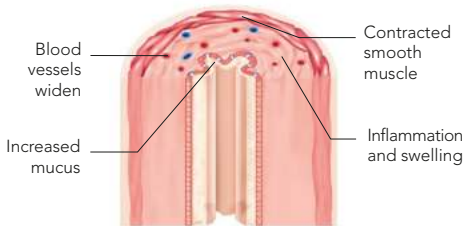
Asthma is an inflammatory lung disease that causes recurrent attacks of breathlessness and wheezing due to narrowed airways. Some people have the occasional slight episode; others are prone to severe and even life-threatening attacks. The muscle in the walls of the airways contracts spasmodically, causing constriction of the tubes.



### HEALTHY AIRWAY

The bronchiole has relaxed smooth muscle in its walls and a thin coating of protective mucus covering the lining. The passage of air is unrestricted.

The narrowing is worsened by the secretion of excess mucus. Most cases develop in childhood and may be linked to allergy-based problems such as eczema. In many children, the trigger for an attack is an allergic reaction to a foreign substance, such as inhaled particles of pollen, animal hair, or house dust mite droppings.



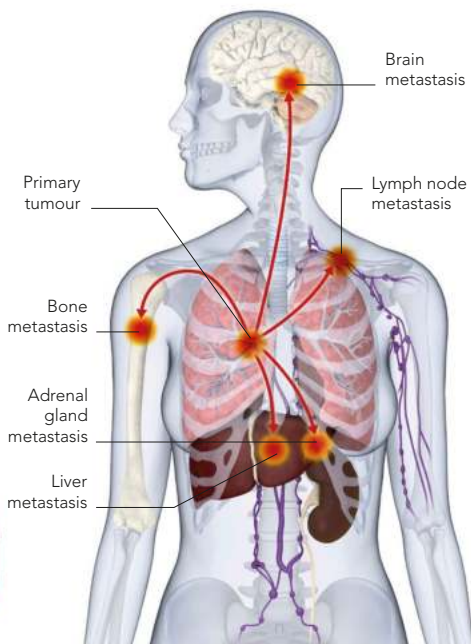
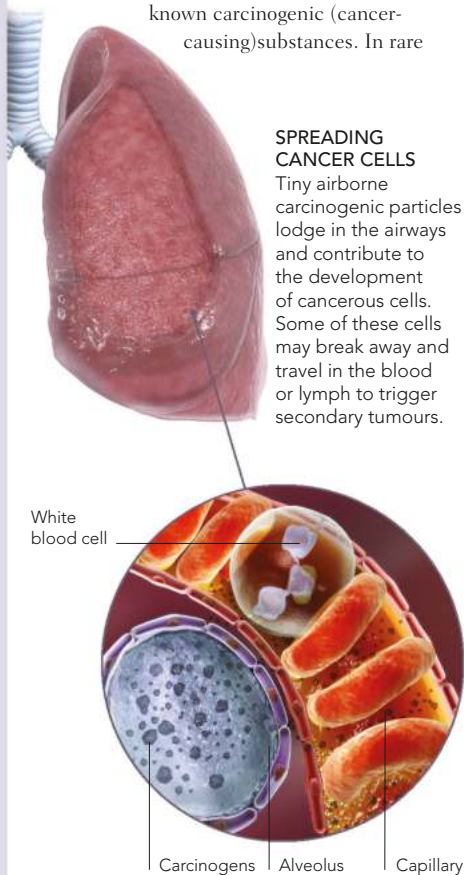
### ASTHMATIC AIRWAY

In an asthma attack, the muscle wall contracts and inflammation causes swelling of the airway lining. The mucus thickens, further narrowing the airway.

## LUNG CANCER

The most common cause of lung cancer – responsible for almost 90 per cent of all cases – is tobacco smoke. In the past, lung cancer was far more common in men than women, because more men than women smoked. However, as more women have taken up smoking, this effect has reduced. The disease is also becoming increasingly common in developing countries, with the spread of tobacco smoking and growing urban populations. Many inhaled irritants trigger the growth of abnormal cells in the lungs, but cigarette smoke contains thousands of known carcinogenic (cancer-causing) substances. In rare

cases, lung cancer is caused by asbestos, toxic chemicals, or the radioactive gas radon. A persistent cough is usually the earliest symptom. Because most people who develop lung cancer are smokers, this is often dismissed as a “smoker’s cough”. Other symptoms include coughing up blood, wheezing, weight loss, persistent hoarseness, and chest pain. If tests confirm the presence of lung cancer, a lobectomy (removal of a lung lobe) or pneumonectomy (removal of a whole lung) may be performed. This is usually advised only if the tumour is small and has not spread. Chemotherapy and radiotherapy may be given, alone or in combination.



### THE SPREAD OF LUNG CANCER

Lung cancer can spread (metastasize) to other parts of the body. Metastases in bones can cause pain and fractures; in the brain, headaches and confusion; and in the liver, weight loss and jaundice.



# CHRONIC OBSTRUCTIVE PULMONARY DISEASE

Chronic obstructive pulmonary disease (COPD) consists primarily of chronic bronchitis and emphysema, two conditions that usually occur

together. In this disorder there is progressive damage to lung tissue, causing restricted airflow in and out of the lungs and shortness of breath.

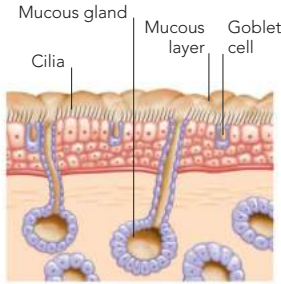
## CHRONIC BRONCHITIS

In chronic bronchitis, the main airways leading to the lungs, the bronchi, become inflamed, congested, and narrowed due to irritation caused by tobacco smoke, frequent infections, or prolonged exposure to pollutants. The inflamed airways begin to produce too much mucus (sputum), resulting in a typical cough that at first

is troublesome mostly in damp, cold months but then persists throughout the year. Symptoms such as hoarseness, wheezing, and breathlessness also develop. Eventually a person becomes short of breath even at rest. If a secondary respiratory infection develops, the sputum may change appearance from clear or white to yellow or green.

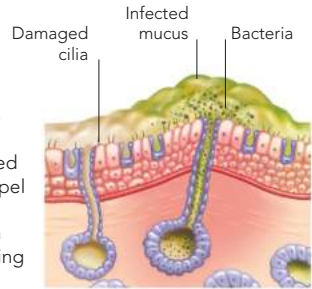
### NORMAL AIRWAY LINING

Glands produce mucus that traps inhaled dust and germs. Tiny surface hairs (cilia) propel the mucus up into the throat, where it is coughed up or swallowed.



### AIRWAY IN CHRONIC BRONCHITIS

Inhaled irritants cause glands to produce more mucus. Damaged cilia cannot propel mucus along, so it becomes a bacterial breeding ground.



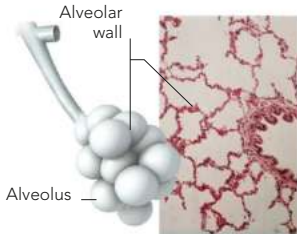
## EMPHYSEMA

In emphysema, the air sacs (alveoli) become overstretched. They rupture and merge, which reduces their oxygen-absorbing surfaces and makes gas exchange less efficient. Air also becomes trapped inside them, the lungs over-inflate, and the volume of air moving in and out of the lungs is

reduced. Most people affected by emphysema are long-term heavy smokers, although a rare inherited condition called alpha-1-antitrypsin deficiency can also cause the disorder. The lung damage is usually irreversible, but giving up smoking may slow the progression of the disease.

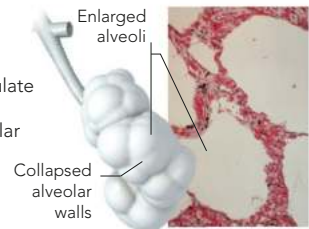
### HEALTHY TISSUE

The alveoli are grouped, like grapes, and each tiny sac is partly separate from the others. The walls are thin and elastic so they can stretch.



### DAMAGED TISSUE

Smoke or other pollutants stimulate chemicals that cause the alveolar walls to break down, reducing the area for gas exchange.





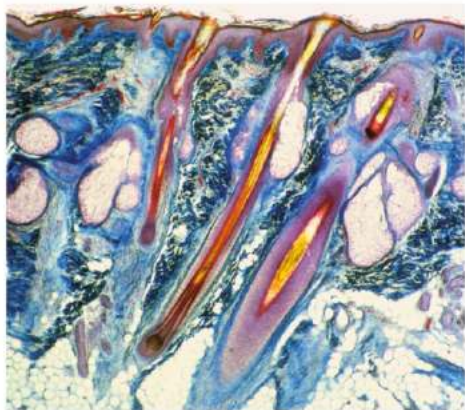
FEW BODY PARTS RENEW AS RAPIDLY AS THE SKIN. EVERY MONTH THE OUTER LAYER OF EPIDERMIS IS COMPLETELY REPLACED, AT A RATE OF 30,000 FLAKE-LIKE DEAD CELLS PER MINUTE. THE HAIR AND NAILS ARE LIKEWISE SELF-RENEWING. SKIN REFLECTS ASPECTS OF GENERAL HEALTH, ESPECIALLY DIET AND LIFESTYLE. INTERNAL DISORDERS OR EXTERNAL FACTORS CAN BRING PROBLEMS SUCH AS RASHES, SPOTS, AND SORES. SKIN GROWTHS MAY FOLLOW EXPOSURE TO HARMFUL CHEMICALS OR TO ULTRAVIOLET AND OTHER HAZARDOUS RADIATION.

# SKIN, HAIR, AND NAILS



# SKIN, HAIR, AND NAIL STRUCTURE

THE SKIN IS ONE OF THE LARGEST ORGANS OF THE BODY, WEIGHING 3–4KG (6–9LB) AND WITH A SURFACE AREA OF ALMOST 2M<sup>2</sup> (21SQ FT). IT IS FORMED FROM MANY TYPES OF CELL, SOME OF WHICH PRODUCE HAIR AND NAIL TISSUE.



## SKIN SECTION

This micrograph shows three hair follicles and globules of sebum in the dermis (blue), with the thin epidermis (purple) on top.

## SKIN STRUCTURE

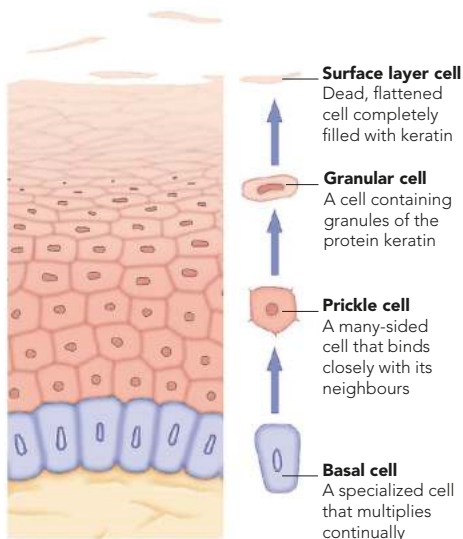
The skin is not just a thin, waterproof covering but a complex organ consisting of a variety of specialized cells. The skin's thickness varies from about 0.5mm ( $\frac{1}{50}$ in) on delicate areas such as the eyelids, to 5mm ( $\frac{1}{5}$ in) or more on areas of wear and tear, such as the soles of the feet. Skin has two main layers: the outer epidermis, the main function of which is protection, and the underlying dermis. The dermis contains thousands of sensors that are sensitive to touch. It also contains sweat glands and blood vessels, which play a vital role in temperature regulation. Under the dermis is a layer known as subcutaneous fat. This acts as a buffer and provides insulation against extreme heat and cold.

## SKIN RENEWAL

The epidermis continually renews and replaces itself. The basal layer consists of box-like cells that multiply quickly and are gradually pushed up to the surface by new cells forming below. As the cells move upwards, they develop tiny prickles that bind them together. They then flatten and fill with a waterproofing protein called keratin. Finally, the cells die, and reach the surface resembling interlocking roof tiles. As they flake away with wear and tear, more cells arrive to replace them.

## EPIDERMAL LAYERS

The procession of skin cells from base to surface creates four layers (five in areas of great friction, such as the palms and soles) in the epidermis. As each cell moves upwards, it fills with keratin.



**STRUCTURE OF SKIN**

A patch of skin the size of a fingernail contains 5 million cells of at least a dozen main kinds, 100 sweat glands, 1,000 touch sensors, 100-plus hairs with sebaceous glands, up to 1m (3<sup>1</sup>/<sub>3</sub>ft) of tiny blood vessels, and about 0.5m (1<sup>2</sup>/<sub>3</sub>ft) of nerve fibres.

**Touch sensor**  
Specialized nerve ending at edge of epidermis; other touch sensor types lie deeper in dermis

**Hair shaft**  
Part of hair that projects above skin surface

**Arrector pili muscle**  
Tiny muscle that pulls up hair when cold

**Sweat**  
Drops of perspiration ooze from sweat pores

**Basal epidermal layer**  
Layer in which fast cell division renews epidermis above

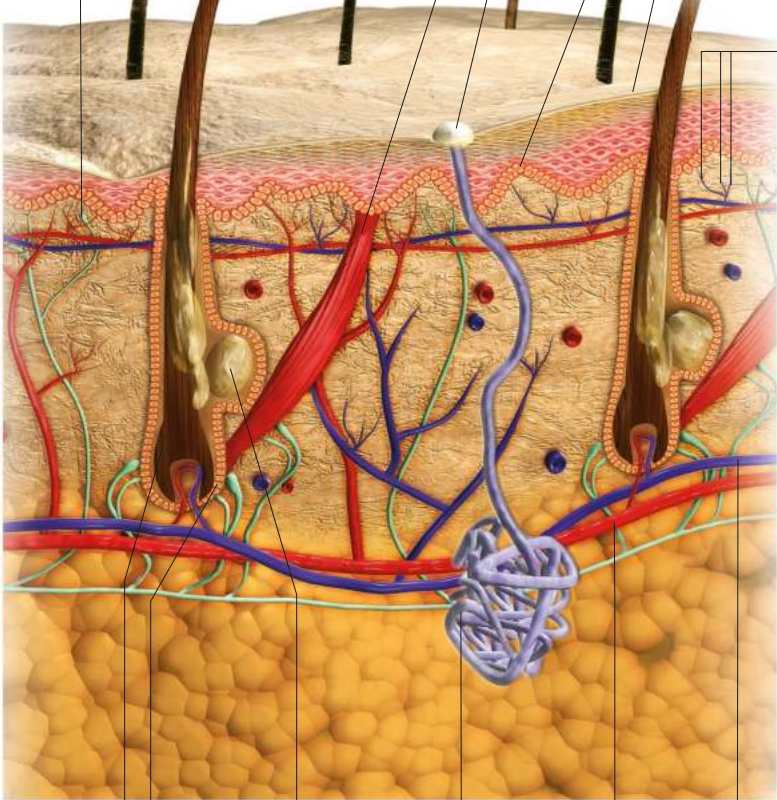
**Epidermal surface**  
Cornified layer of flat, dead skin cells

**Capillaries**  
Tiny blood vessels that supply oxygen and nutrients to tissues and collect waste

**Epidermis**  
Outer protective layer consisting of tough, flat cells

**Dermis**  
Layer containing blood vessels, glands, and nerve endings

**Subcutaneous fat**  
Acts as an insulator, shock absorber, and energy store



**Hair bulb**  
Lowest part of hair, where growth occurs

**Hair follicle**  
Pouch of epidermis at root of hair

**Sebaceous gland**  
Produces sebum that protects hair and lubricates skin

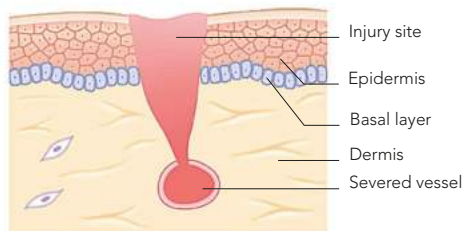
**Sweat gland**  
Coiled knot of tubes secreting watery sweat

**Arteriole**  
Supplies oxygenated blood

**Venule**  
Carries away waste

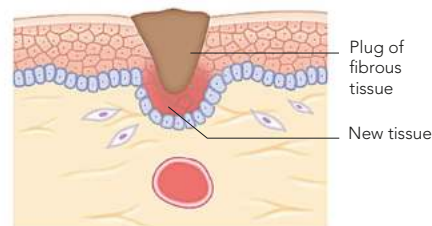
## SKIN REPAIR

If the skin surface is breached, contents leak from damaged cells and stimulate the repair process. Platelets in the blood and the blood-clotting protein fibrinogen together form a mesh of fibres that traps red cells as the beginning of a clot.



### 1 INJURY

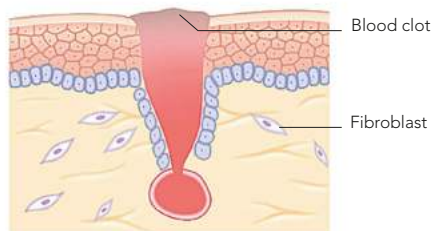
The wound breaks open cells and releases their contents. These components attract various defence and repair cells.



### 3 PLUGGING

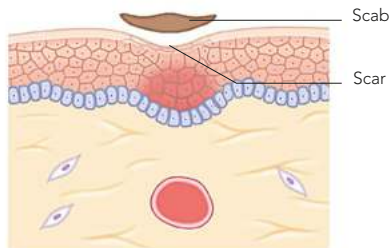
Fibroblasts produce a plug of fibrous tissue within the clot, which contracts and shrinks. New tissue begins to form beneath.

Tissue-forming fibroblast cells collect in the area, as do white cells called neutrophils, which ingest cell debris and foreign matter such as dirt and germs. The clot gradually hardens and expels fluid to become a scab, as the skin heals.



### 2 CLOTTING

Blood seeps from the vessel and forms a clot. Fibroblasts multiply and migrate to the damaged area.

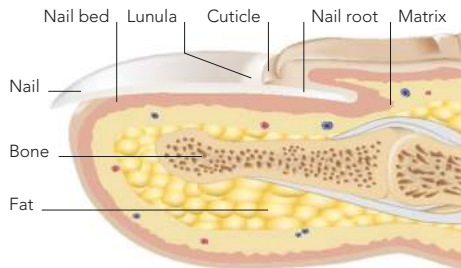


### 4 SCABBING

The plug hardens and dries into a scab, which eventually detaches. A scar may remain, but usually fades with time.

## NAIL STRUCTURE

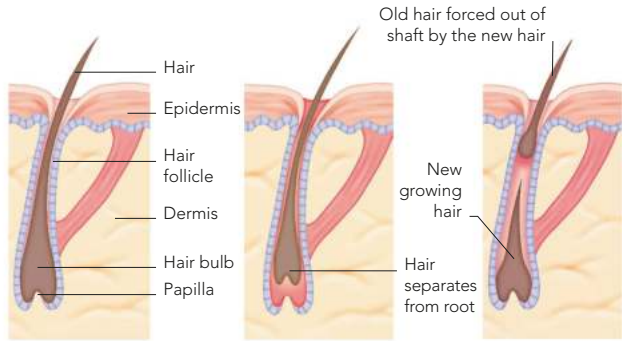
Fingernails and toenails are hard plates made of a tough protein called keratin. Growth takes place under a fold of flesh (cuticle) at the nail base. The nail matrix adds keratinized cells to the nail root, and the whole nail is continuously pushed forward along the nail bed towards its free edge. Most nails grow about 0.5mm ( $\frac{1}{50}$ in) each week, with fingernails lengthening faster than toenails.



CROSS-SECTION THROUGH NAIL AND FINGER

## HAIR GROWTH

Hairs are rods of dead cells filled with keratin. The root, or bulb, is buried in a pit, the follicle. As extra cells add to the root, the hair lengthens. Different kinds of hairs grow at varying rates, with scalp hairs lengthening about 0.3mm ( $1/100$ in) each day. Hair does not grow continuously. After three to four years, the follicle goes into a rest phase and the hair may fall out. Three to six months later, the follicle activates again and begins to produce a new hair.



### ACTIVELY GROWING

New cells created at the root get pushed up so the hair gets longer.

### INACTIVE PHASE

Activity in the follicle stops and the hair stops growing.

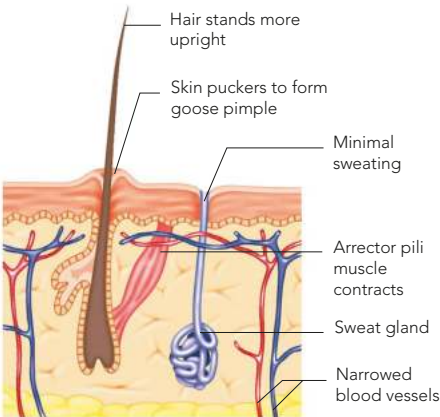
### NEW GROWTH

The follicle root reactivates and starts to produce a new hair as the old one falls out.

## TEMPERATURE REGULATION

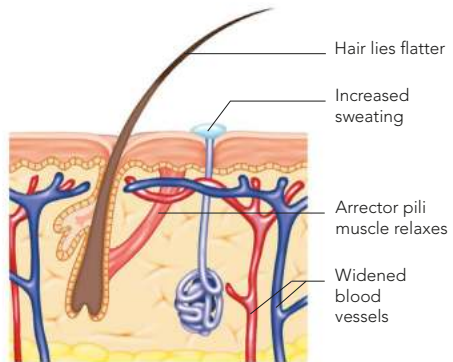
One of the skin's functions is to help maintain a constant body temperature. If the body is too hot, blood vessels in the dermis widen (vasodilate) to allow extra blood flow so more heat can be lost from the surface, and sweat glands produce more

sweat, which evaporates, drawing away body heat. If the body is cold, the skin's blood vessels narrow (vasoconstrict) to minimize heat loss, and sweating is reduced. Tiny hairs are pulled upright by the arrector pili muscles to trap an insulating layer of air.



### FEELING COLD

Tiny body hairs are raised, creating goose pimples at their bases. The skin's blood vessels constrict, reducing blood flow, and sweat glands reduce their activity.



### FEELING HOT

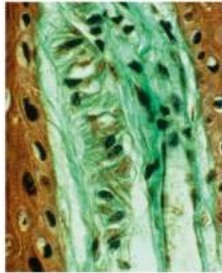
Tiny body hairs lie flatter and the goose pimples disappear. The blood vessels widen, increasing blood flow, and sweat glands increase sweat production.

# SKIN AND EPITHELIAL TISSUES

SKIN PROTECTS THE UNDERLYING TISSUES AND ALSO PROVIDES THE SENSE OF TOUCH. IT IS A SPECIALIZED TYPE OF EPITHELIUM. EPITHELIAL TISSUES OCCUR THROUGHOUT THE BODY, PROVIDING COVERINGS AND LININGS FOR BODY PARTS AND ORGANS.

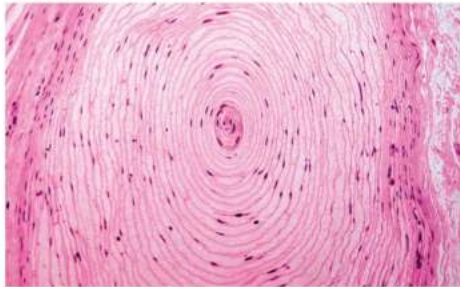
## COMPLEXITIES OF TOUCH

The sense of touch is based in the lower of the skin layers, the dermis. Microsensors – the endings of tiny nerve cells – in the dermis detect various physical changes, from light contact to heavy, painful pressure. On average, a skin patch the size of a fingernail contains about 1,000 receptors. However, the skin on the fingertips has more than 3,000 receptors that detect light touch for precise feeling. There are also receptor fibres



### LIGHT-TOUCH SENSOR

This microscope view shows a Meissner's corpuscle (green) in a fingertip. It is important for light, discriminatory touch.



### DEEP-PRESSURE SENSOR

Pacinian corpuscles have a multi-layered structure and are the largest of the skin receptors, in some areas being more than 1mm ( $1/25$ in) long.

### Superficial nerve endings

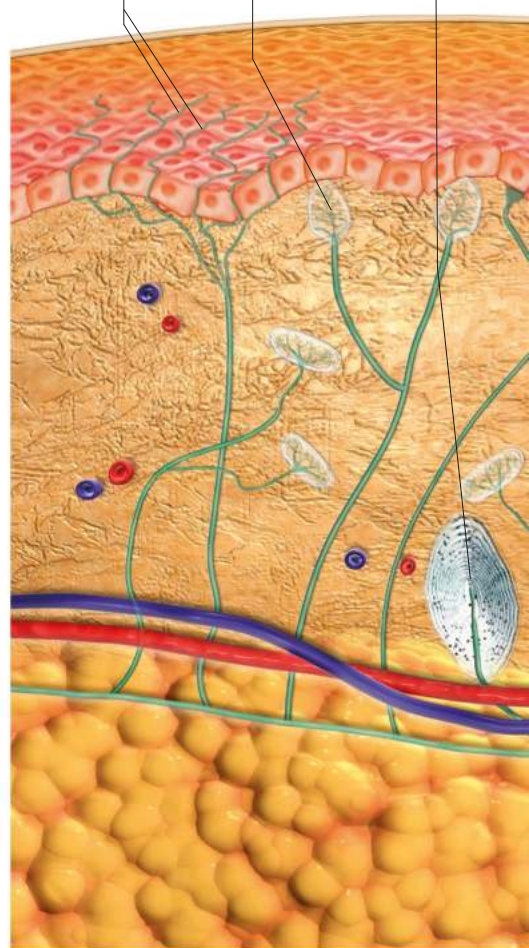Penetrate the epidermis; occur everywhere in the skin and include free nerve endings

### Meissner's corpuscle

Upper dermal nerve ending; mostly located just below the base of the epidermis

### Pacinian corpuscle

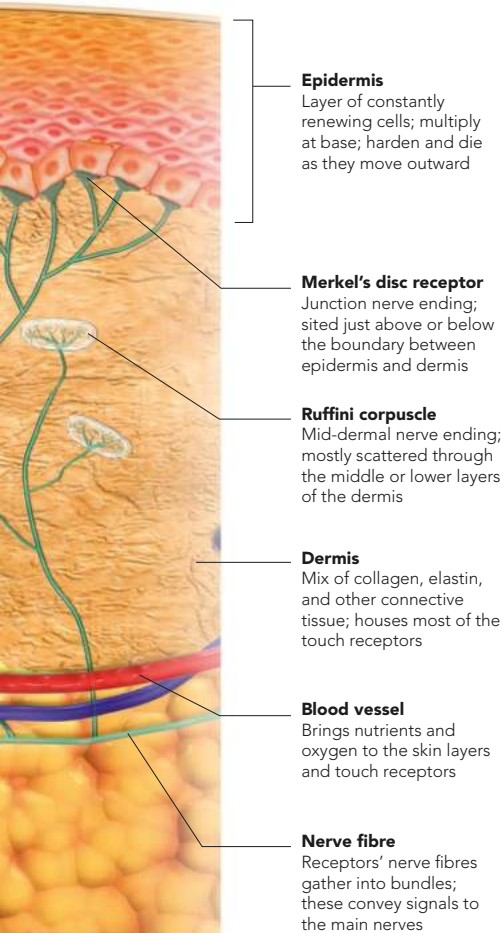
Located deep in the dermis





## SKIN MICRORECEPTORS

Deformation of the layers within a receptor, and expansion or contraction as a result of temperature changes, generate nerve impulses. The impulses travel along the receptor's nerve fibre, which joins with bundles of other fibres in the deep dermis or tissue layers below. Most receptors "fire" nerve signals infrequently and irregularly when not stimulated, increasing their firing rate when the skin is touched.

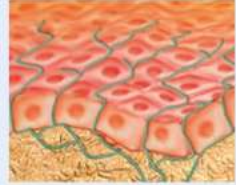


## TYPES OF SENSOR

Each type of microsensor is set at a particular depth in the dermis that best suits its function. The largest receptors, Pacinian corpuscles, are located at the deepest level, near the base of the dermis. Sensors for light touch are located near or just within the epidermal layer.

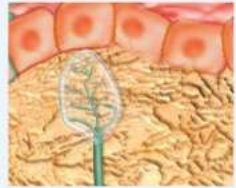### Free nerve endings

Branching, usually unsheathed sensors of temperature, light touch, pressure, and pain. They are found all over the body and in all types of connective tissue.



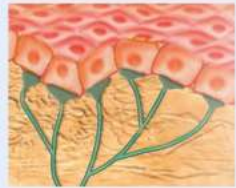
### Meissner's corpuscle

Encapsulated nerve ending in the skin's upper dermis, especially on the palms, soles, lips, eyelids, external genitals, and nipples. It responds to light pressure.



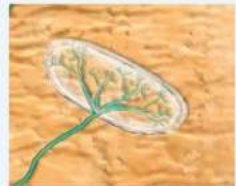### Merkel's disc

Naked (unencapsulated) receptors, usually in the upper dermis or lower epidermis, especially in non-hairy areas. They sense faint touch and light pressure.



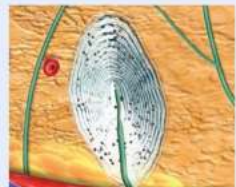
### Ruffini corpuscle

Encapsulated receptor in the skin and deeper tissue that reacts to continuous touch and pressure. In joint capsules, it responds to rotational movement.



### Pacinian corpuscle

Large, covered receptor located deep in the dermis, as well as in the bladder wall, and near joints and muscles. It senses stronger, more sustained pressure.



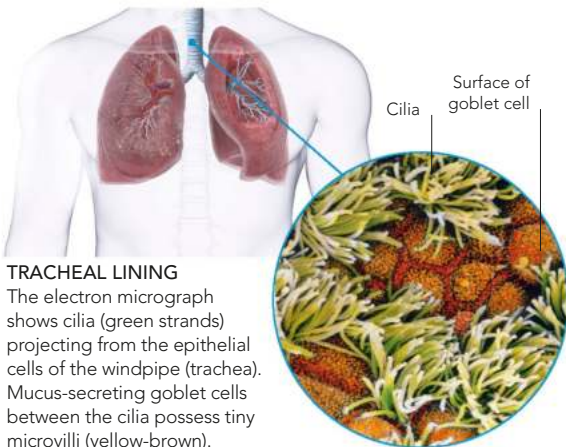
## EPITHELIUM

Epithelial tissue, also called epithelium, is an important structural element that acts as a lining or covering for other body tissues. Epithelium can be classified according to the shape and layout pattern of individual cells (see opposite), and also by the arrangement of cells into one or more layers. Most epithelial tissues form

membranes and are specialized for protection, absorption, or secretion. They do not contain blood vessels, and their cells are usually anchored to, and stabilized by, a basement membrane. There may be other cell types present, such as goblet cells that secrete blobs of mucus for release on to the surface.

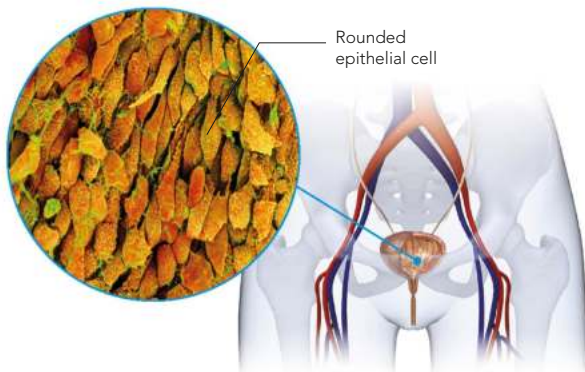
## PSEUDOSTRATIFIED EPITHELIUM

This type of columnar epithelium seems to be arranged in vertical layers. However, it actually consists of a single layer of cells of varying shapes and heights. The nuclei (control centres) of the different cell types are also at different levels, creating a layered (stratified) effect. Taller cells may be specialized into mucus-making goblet cells or ciliated cells that trap foreign particles. This type of epithelium occurs in the airway linings, and in the excretory and male reproductive passages and ducts.



### TRACHEAL LINING

The electron micrograph shows cilia (green strands) projecting from the epithelial cells of the windpipe (trachea). Mucus-secreting goblet cells between the cilia possess tiny microvilli (yellow-brown).



### BLADDER LINING

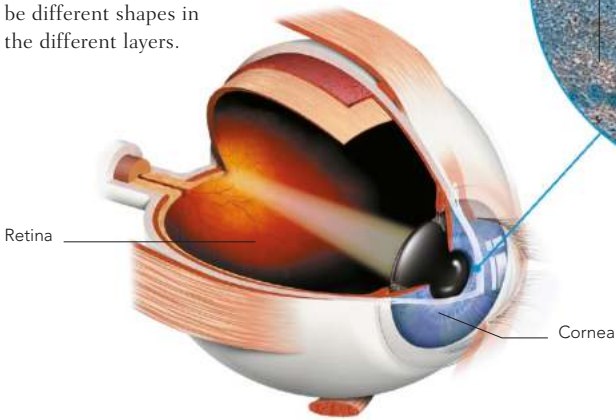
The electron micrograph shows the tightly packed epithelial cells of the bladder lining. They are soft and pliable, enabling them to stretch as the bladder fills with urine.

## TRANSITIONAL EPITHELIUM

This epithelial tissue is similar to layered (stratified) epithelium, but is able to stretch without tearing. There are usually columnar cells in the basal layer, which become more rounded in the upper layers. As these layers stretch, the cells flatten, or become more squamous. Transitional epithelium is well suited to the urinary system, where it lines areas within the kidneys, ureters, bladder, and urethra. It allows these organs to bulge as urine flows through at pressure. The epithelium also secretes mucus that protects it from acidic urine.

## SIMPLE AND LAYERED EPITHELIUM

Simple epithelium is composed of a single layer of cells. This type of tissue is often found in areas where substances need to pass through easily, a single-cell thickness offering minimal resistance. For example, in the air sacs in the lungs, simple epithelium allows the exchange of gases to take place. Layered (stratified) epithelium has two or more layers, and is better for protection in areas such as the mouth or oesophagus. Some complex epithelium has more than five layers, but two or three is more usual. The cells may be different shapes in the different layers.



## CORNEA STRUCTURE

The epithelium covering the cornea is transparent and about five layers thick. It permits light rays to enter the eye.

## EPITHELIUM IN THE EYE

The eye contains two types of epithelium: simple epithelium in the pigmented layer of the retina, and stratified squamous epithelium in the domed front "window" of the cornea.

## TYPES OF EPITHELIAL CELL

The cells that make up the epithelial layers are usually classified according to their shape. Since most epithelial cells, as a consequence of their

locations in the body, are subject to friction, compression, and similar physical wear and tear, they divide rapidly to replace themselves.

### Squamous

Plate-like or flattened cells, wider than deep, resembling paving slabs or crazy-paving; flattened nucleus.

Features: Cells allow selective diffusion, or permeability, allowing certain substances to pass, owing to thinness of the layer.

### Cuboidal

Cube- or box-shaped cells, occasionally hexagonal or polygonal; nucleus usually in cell centre.

Features: Substances absorbed from one side of the layer can be altered as they pass through the cytoplasm of the cuboidal cells, before leaving.

### Columnar

Tall, slim cells, often square, rectangular, or polygonal; large, oval nucleus near cell base.

Features: Protect and separate other tissues; may be topped with cilia for movement of fluid outside the cell or microvilli for absorption.

### Glandular

Epithelial cells modified for secretion, usually cuboidal or columnar with secretory granules or vacuoles.

Features: Layers of these cells may be infolded to form pits, pockets, grooves, or ducts, as in sweat glands.

## SKIN AND HAIR DEFENSIVE FUNCTIONS

Skin is the body's first line of defence against potential harm. As such, it is well equipped to prevent physical damage due to its supple, cushioned qualities. The epidermal cells that form skin's outermost layers are tightly knit together, but allow a certain amount of pliability. The cells are almost entirely full of the tough protein keratin, which resists attack by many kinds of chemicals. The natural secretion of sebum from the millions of sebaceous glands, each associated with a hair follicle, is slightly oily at body temperature and spreads easily. It furnishes the skin with partially water-repellent and antibiotic qualities, inhibiting the growth of certain microorganisms, and prevents hairs from becoming too brittle.

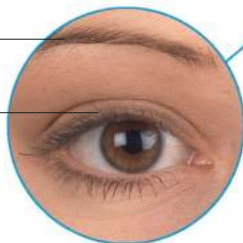
### SCALP HAIR

Head hairs help to keep rainwater from the scalp, absorb or deflect some of the energy in knocks and blows, and shield the head from extremes of temperature.



### Eyebrow

### Eyelash



### Sebum oils and waxes

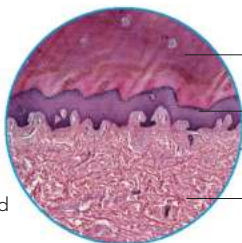
Mixture of lipid-rich secretions (palmitic, stearic, oleic, linoleic, and other fatty acids) softens and lubricates skin and repels water

### EYEBROWS AND EYELASHES

The arch of relatively coarse, fast-growing eyebrow hairs helps to divert sweat or rainwater on the forehead that might trickle into the eyes. Eyelashes produce swirling air currents when blinking, which push floating particles away from the eye surface.

### THICKENED SKIN

Areas of skin subjected to regular pressure respond by thickening their epidermis for greater protection and buffering, as in this magnified image of skin from the foot.



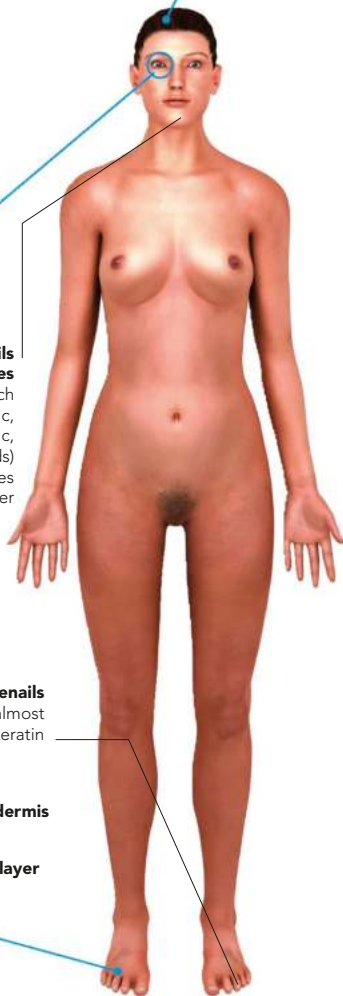### Thick epidermis

### Basal cell layer

### Dermis

### Toenails

Made of almost solid keratin

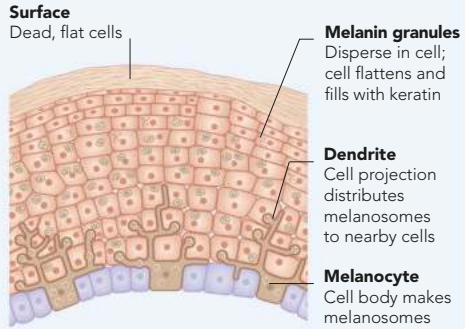


## ULTRAVIOLET DEFENCES

The Sun's rays include a spectrum of colour wavelengths, as well as infrared or IR rays and ultraviolet, UV, rays. Both UV-A and UV-B wavelengths are invisible, but exposure to the latter, in particular, is linked to skin cancers. Skin's defence is its dark pigment, melanin. This forms a screen in the upper epidermis and shields the multiplying cells in the base of the epidermis.

### MELANIN PRODUCTION

Melanocytes are melanin-producing cells in the base of the epidermis. They make parcels of melanin granules, known as melanosomes, which pass into surrounding cells.



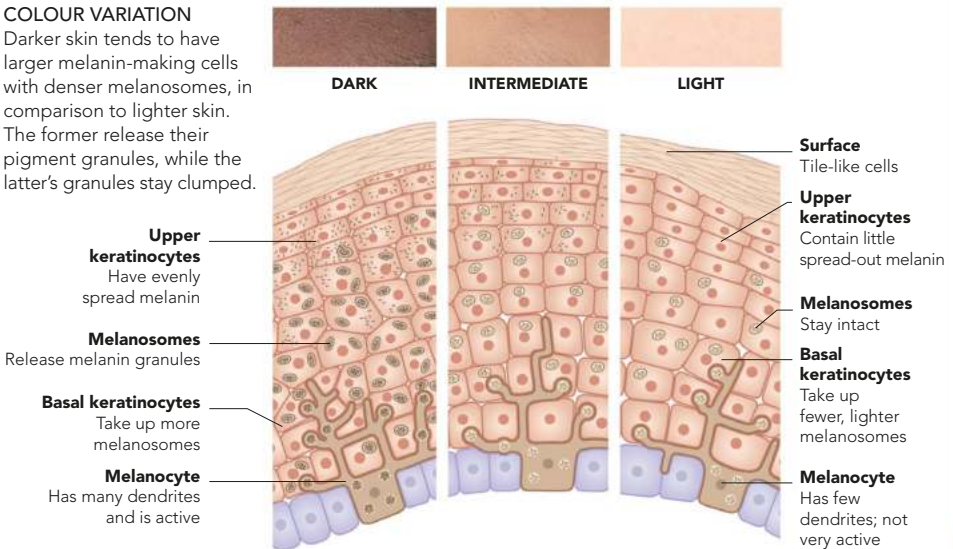
## SKIN PIGMENTATION

Skin colour depends on the type and quantity of two melanin pigments – reddish pheomelanin and brown-black eumelanin – in the epidermis, and on the way the pigment granules are distributed. Each melanocyte has finger-like dendrites that touch surrounding cells (basal keratinocytes). The melanocyte produces

pigment granules within organelles called melanosomes. These move along the dendrites and into nearby cells. Darker skin has larger melanocytes with more melanosomes. Lighter skin has smaller melanocytes and fewer melanosomes. Exposure to UV rays stimulates the melanocytes so the skin darkens.

### COLOUR VARIATION

Darker skin tends to have larger melanin-making cells with denser melanosomes, in comparison to lighter skin. The former release their pigment granules, while the latter's granules stay clumped.



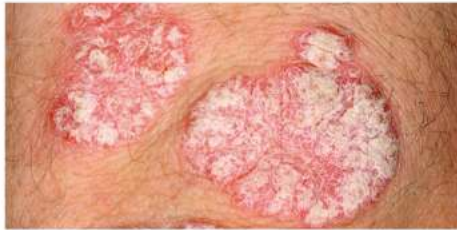
# SKIN DISORDERS

SKIN CONTAINS SOME OF THE FASTEST-MULTIPLYING CELLS IN THE BODY. SEVERAL OF ITS DISORDERS, SUCH AS MOLES, RESULT FROM PROBLEMS IN THIS SELF-RENEWAL SYSTEM. THE SKIN IS ALSO SUSCEPTIBLE TO INJURY, ALLERGIC REACTION IN THE FORM OF RASHES, AND INFECTIONS.

## RASHES

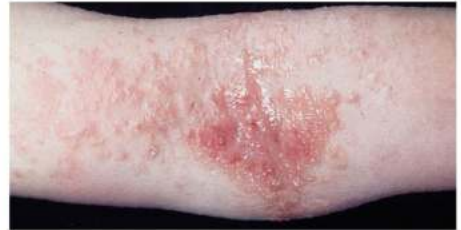Some skin rashes are localized, while others are more widespread. Often, the cause of a rash is not clear. The condition may affect quality of life and require long-term control with self-help measures and medication. Psoriasis is a widespread, patchy rash that flares up at intervals. Episodes may be triggered by infection, injury, stress, or as a side-effect of drug treatment. Eczema is one of the commonest rashes, especially in children. It is

often linked to allergic conditions such as asthma and rhinitis (hay fever). Impetigo is a blistering of the skin caused by bacterial infection, typically through a cut, a cold sore (*Herpes simplex virus*), or scratched, weeping eczema. In vitiligo, the body makes antibodies that attack the skin's pigment-making cells, or melanocytes. It occurs in patchy areas over the body; in about one-third of cases, the pigmentation spontaneously returns.



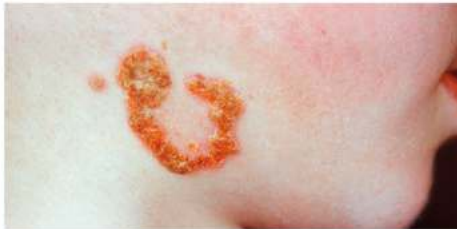### PSORIASIS

There are several types of psoriasis, mostly characterized by intermittently itchy patches of red, thickened, scaly skin, as dead epidermal cells accumulate. Common sites are the knees, elbows, lower back, scalp, and behind the ears.



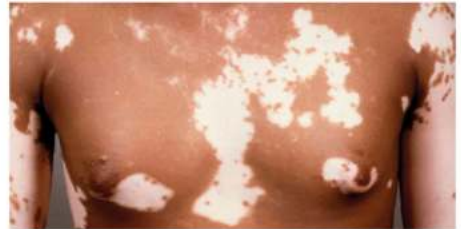### ECZEMA

A typical eczema rash is inflamed and itchy, with small fluid-filled blisters or episodes of dry, scaly, thickened, and cracked skin. Common sites are the hands and creased areas of skin, such as the wrists, elbows, and knees. The condition is also known as dermatitis.



### IMPETIGO

This bacterial infection is common on the face, most often around the nose and mouth. The skin develops fluid-filled blisters, which burst. This stage is followed by redness, weeping, and crusting that may itch.



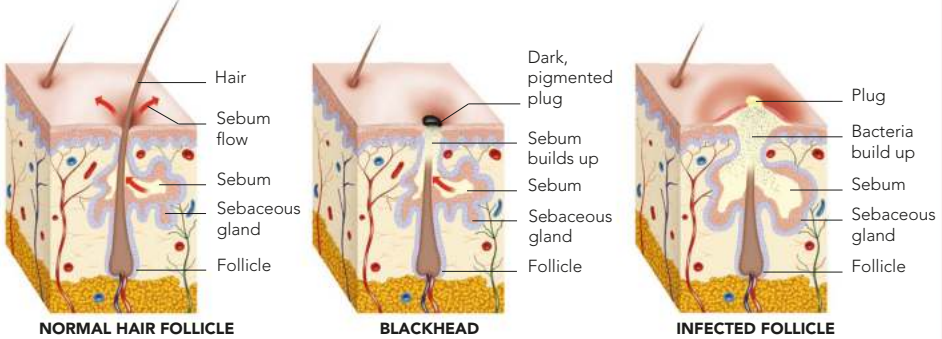
### VITILIGO

Depigmented patches of skin develop over months or years, especially on the face and hands. The areas are more distinct in people with dark skin. They do not carry any medical risks to health.

## ACNE

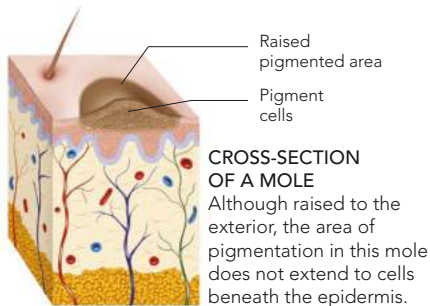
In acne vulgaris, the sebaceous glands produce an excessive amount of the oily-waxy secretion, sebum. This reacts in contact with air and forms a plug in the skin pore, which may appear dark with pigmentation (not dirt), as a blackhead or

comedone, or pale, as a whitehead. A combination of trapped sebum, dead skin cells, and bacterial infection inflame the area, and a pustule develops. Acne is a common problem at puberty, when hormone surges cause increased sebum output.



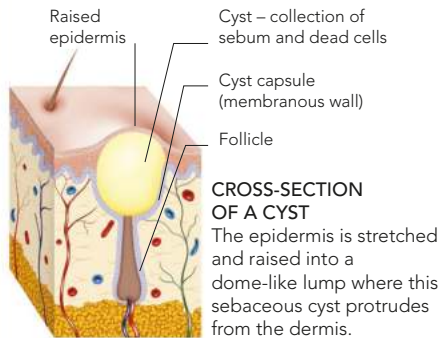
## MOLE


A mole, or naevus, is a localized overproduction and aggregation of the skin's pigment cells (melanocytes), with increased amounts of melanin pigment. Moles are very common – most adults have 10–20 moles by the age of 30 years. They can occur almost anywhere on the body and are variable in size, but usually less than 1cm ( $\frac{2}{8}$ in) across. Rarely, moles become malignant (cancerous); any change in size or appearance, itching, or bleeding should be discussed with a doctor.



## CYST

The most common type of cyst is a sebaceous cyst that forms in a hair follicle. A cyst contains sebaceous secretions and dead cells, which are restrained in a strong, bag-like capsule. Its surface mound is usually smooth, and some cysts have a paler or darker central region. Common sites include the scalp, face, trunk, and genitals, although they can occur just about anywhere. Treatment may be needed if the cyst becomes enlarged, unsightly, painful, or infected.

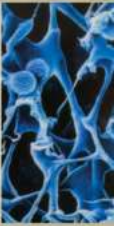



THE HUMAN BODY IS PROTECTED BOTH BY ITS SKIN AND BY THE LYMPH AND IMMUNE SYSTEMS. EVERY DAY IT IS OPEN TO ATTACK. EXTERNALLY, THERE IS THE DAILY BATTLE AGAINST PHYSICAL HARM. WITHIN, THERE ARE GERMS THAT HAVE GAINED ENTRY, AND THE BODY'S OWN CELLS, WHICH CAN TURN AGAINST IT. THE IMMUNE SYSTEM FIGHTS ON BOTH THESE FRONTS, CHIEFLY WITH ROVING WHITE BLOOD CELLS. THEIR TRANSPORT AND SUPPLY NETWORKS USE THE BLOOD, AND ALSO THE FLUID, VESSELS, AND NODES OF THE LYMPHATIC SYSTEM.



# LYMPH AND IMMUNITY



# LYMPH AND IMMUNE SYSTEMS

THE IMMUNE SYSTEM, INCORPORATING THE LYMPHATIC SYSTEM, IS THE MAIN MEANS BY WHICH THE BODY IS PROTECTED FROM INVASION BY MICROORGANISMS.

The lymphatic system contains lymph, a fluid that originates in the interstitial spaces between cells. Lymph drains into networks of tiny capillaries in tissue spaces that unite to form larger vessels called lymphatics. Nodes scattered along the length of the lymphatics filter and store the lymph. Organs, such as the thymus and spleen, and lymphoid tissue, such as tonsils and Peyer's patches, complete the system. They contain many specialized white blood cells, which protect the body against non-self material such as microorganisms.

## Adenoids

Also called pharyngeal tonsils; lie at rear of nasal cavity; help to filter air and destroy microorganisms

## Tonsils

Two pairs of tonsils (palatine and lingual) at back of mouth – on either side of pharynx, and at base of tongue – help to guard against inhaled microbes

## Right lymphatic duct

Collects lymph from upper-right quadrant of body, including right arm and right sides of head and chest

## Cervical (neck) nodes

Collect lymph from right or left side of the face, scalp, nasal cavity, and throat

## Axillary (armpit) nodes

Drain lymph from arm, breast, chest wall, and upper abdomen

## Right subclavian vein

One of two main exit points at which lymph drains into blood system

## Thoracic duct

Also called left lymphatic duct; collects lymph from both legs, abdomen, left arm, and left sides of head and chest

## Supratrochlear node

Collects lymph from hand and forearm

## Cisterna chyli

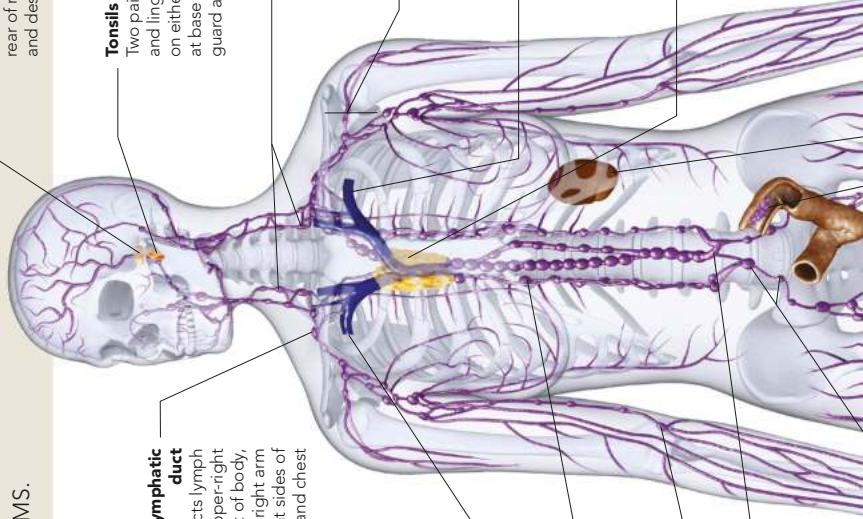
Enlarged lymph vessel formed from vessels from legs and lower body; eventually narrows into thoracic duct

## Left subclavian vein

Point at which lymph from left and lower body enters blood after collecting in thoracic duct

## Thymus gland

Site of maturation of immune-system T-lymphocytes (T-cells); T-cells develop from stem cells, which migrate here from bone marrow



**Lumbar lymph nodes**  
Drain lymph from abdominal organs

## AUXILIARY IMMUNE SYSTEM

Many organs have a role in protecting the body against invading microbes. They form an auxiliary immune system that includes the skin, microscopic hairs, gastric enzymes, and useful bacteria.

**Tear (lacrimal) glands**

Tear fluid contains an antibacterial enzyme, lysozyme, that flushes across the eyeball with each blink

**Respiratory tract**

Nostril hairs trap airborne particles; mucus and cilia in lining of nose and trachea trap and remove dust, microorganisms, and debris

**Small intestine**

Digestive enzymes, including those in pancreatic juices, attack microbes that survive the stomach

**Large intestine**

The body's natural gut flora ("friendly" bacteria and other microorganisms) suppress unwanted, harmful microbes

**Mouth, and throat**

Salivary glands (yellow) produce antibacterial saliva, while mucus and saliva trap airborne particles in throat

**Stomach**

Powerful hydrochloric acid and digestive enzymes in the gastric juices help to destroy ingested organisms

**Genito-urinary tract**

The mucous lining helps to trap foreign matter, and harmless bacteria restrict the growth of potentially harmful organisms

**Skin**

The mechanical barrier formed by skin is the first defence against invading organisms, as well as protecting the body against physical forces such as extremes of temperature, radiation, and various chemicals

**Spleen**

Largest lymph organ; spleen acts as store for some types of lymphocyte and as a major site for filtering blood

**Peyer's patch**

One of a few clusters of lymphoid nodules in lower part of small intestine; helps to protect against microbes ingested in food

**Deep inguinal (groin) node**

Drains lymph from the legs, lower abdominal wall, and external genitals

**Popliteal lymph nodes**

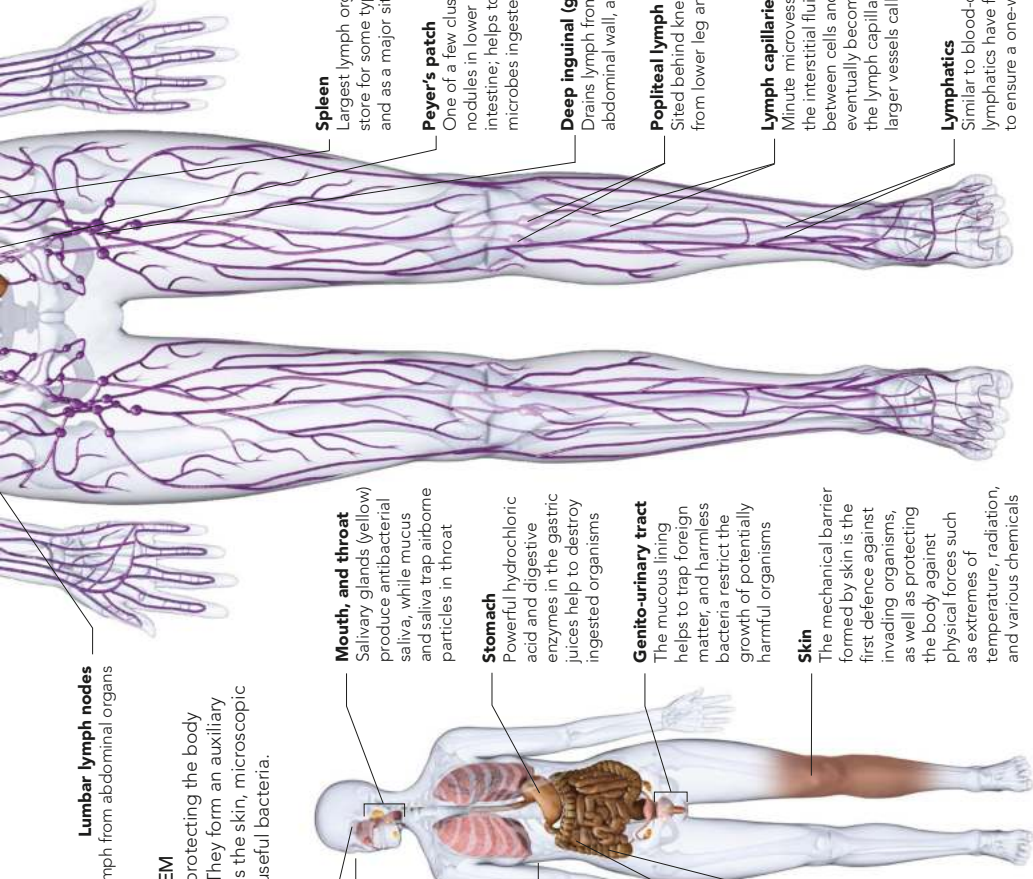
Sited behind knees; drain lymph from lower leg and foot

**Lymph capillaries**

Minute microvessels that collect the interstitial fluid, which flows between cells and tissues and eventually becomes lymph fluid; the lymph capillaries unite into larger vessels called lymphatics

**Lymphatics**

Similar to blood-carrying veins, lymphatics have flap-type valves to ensure a one-way flow of lymph



# IMMUNE SYSTEM

THE COMPLEXITIES OF THE IMMUNE SYSTEM CREATE THE CONDITION OF IMMUNITY, IN WHICH, AFTER THE FIRST ATTACK BY A PARTICULAR TYPE OF MICROORGANISM, THE BODY IS PROTECTED OR RESISTANT TO FUTURE INVASIONS.

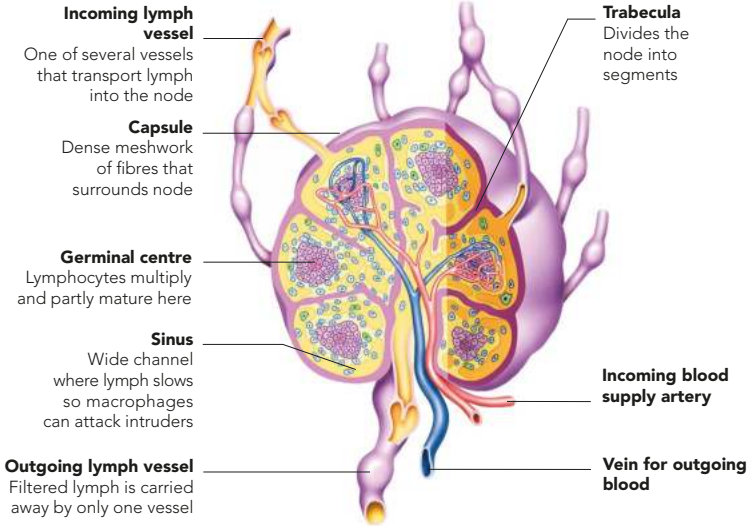
## LYMPH NODES

The lymph nodes produce and harbour lymphocytes that protect the body from disease. They are scattered throughout the body and are also concentrated in groups (see p.192). Small lymphatics

(vessels) bring lymph to a node, while a larger vessel carries it away. The nodes filter and clean the lymph, which then drains into the venous bloodstream. Lymph vessels have valves so the fluid flows one way.

### INSIDE A NODE

A lymph node, or gland, is a mass of segmented lymphatic tissue covered in a fibrous capsule. It contains sinuses, where many scavenging white blood cells, called macrophages, ingest bacteria as well as other foreign matter. Lymph nodes vary in diameter from 1 to 25mm (1/25 to 1in), although they can swell during infection or illness.



## WHITE CELL TYPES

There are numerous types of white blood cell, which are known by the general name of leucocytes. All white blood cells are derived from the bone marrow. Some of them grow and mature into other types.

### Monocyte

Has a nucleus that is big and rounded, or indented; engulfs pathogens.



The largest leucocytes, and the largest cells in the blood, are monocytes. The lymphocytes are the chief immune cells, and they can be either B- or T- cells, depending on the way the lymphocyte develops.

### Lymphocyte

Both types (B- and T- cells) have a large nucleus that almost fills the cell.



### Neutrophil

Granulocyte with many particles and multi-lobed nucleus; engulfs pathogens.



### Basophil

Granulocyte with lobed nucleus; involved in allergic reactions.



### Eosinophil

Granulocyte with B-shaped nucleus; destroys antigen-antibody complexes.



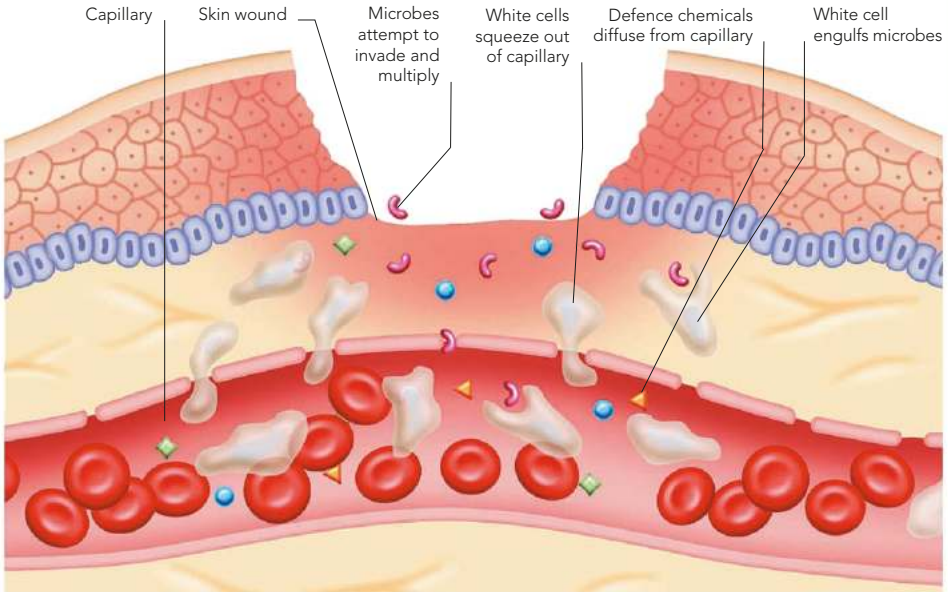
## NON-SPECIFIC RESPONSE

Any damage, such as burns, extreme cold, corrosive chemicals, or invading organisms, elicits a non-specific response. The main response is inflammation (see p.198). The damaged tissue releases chemicals that attract white blood cells. Capillary walls become more permeable and porous to let these cells, along with defensive chemicals and

fluids, enter and accumulate. The white cells surround, engulf, and destroy any pathogens, and the blood may clot to seal the breach.

### INFLAMED TISSUE

The four common signs of inflammation are redness, swelling, increased warmth, and discomfort or pain. They occur after any form of harm in order to limit damage and initiate repair and healing.



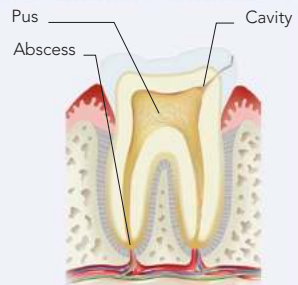
## LOCAL INFECTION

If harmful microbes enter body tissues, both the inflammatory and immune responses act swiftly to limit their spread. White blood cells, fluids, microbes, toxins, and debris accumulate as pus. An abscess forms if the pus gathers in a localized area, putting pressure on surrounding structures. This may cause discomfort and pain,

especially if the surrounding tissues have no flexibility – for example, in a dental abscess.

### DENTAL ABSCESS

Microbes enter through a region of decayed enamel and dentine, infect the pulp, and spread into the root, where pus collects. As pus presses on the pulp nerves, it causes the pain of toothache.

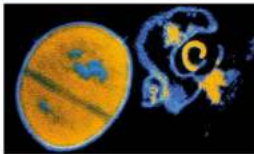
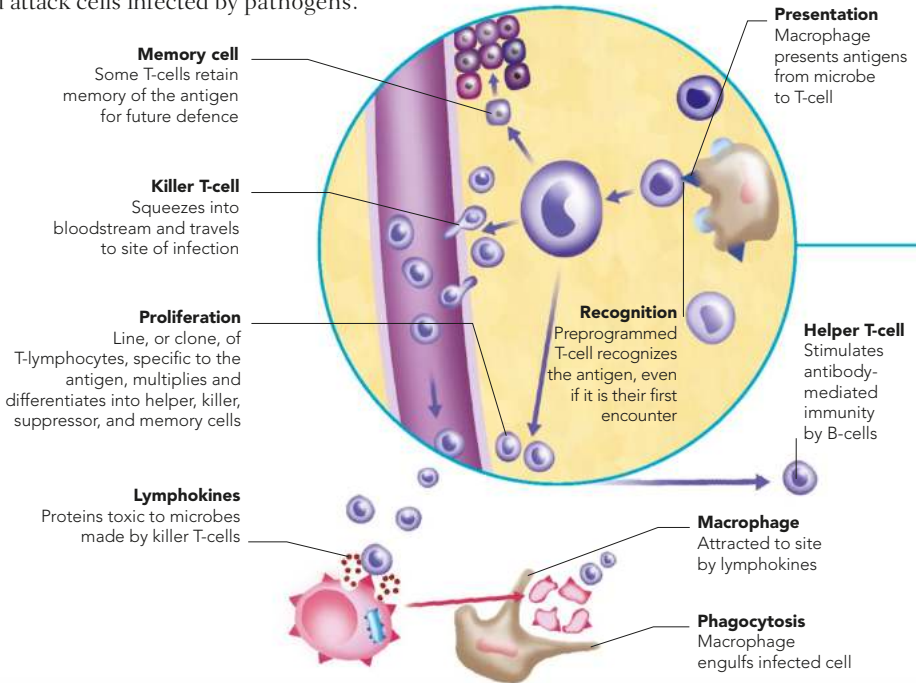


## SPECIFIC RESPONSE

The two main types of specific defence – cell-mediated and antibody-mediated immunity – may accompany non-specific reactions such as inflammation, or follow if infection persists. Both depend on the actions of B- and T- lymphocytes. B-cells make protein antibodies known as gammaglobulins, which react against antigens (foreign proteins). Types of T-cells multiply and attack cells infected by pathogens.

## CELL-MEDIATED IMMUNITY

Once a T-cell recognizes an antigen, it multiplies rapidly and its offspring form several types. Killer T-cells attack and destroy infected cells, which have the antigen on their surface. Helper T-cells activate both B-cells to help antibody-mediated immunity and macrophages to engulf debris. Suppressor (regulatory) T-cells dampen down the body's immune response after the infection has been dealt with.



### LYSED BACTERIUM

Complement dissolves, or lyses, invaders such as bacteria by disrupting their outer membranes (cell shown on right).

## COMPLEMENT SYSTEM

More than 25 proteins and related substances in the blood form the complement system, which joins the fight against invading microbes. Once a complement reaction begins, it carries on in a "cascade", with one protein activating the next, and so on. The complement system has several roles. It generally helps to destroy microbes, and prevent them attacking body cells, encourages the activity of white cells, widens blood vessels, and clears away the antigen–antibody complexes.

**Phagocytosis**  
Macrophage engulfs microorganisms and their antigens

**Invading microbe**  
Pathogenic (harmful) microorganisms such as bacteria

**ANTIBODY-MEDIATED IMMUNITY**

B-cells produce Y- or T-shaped antibodies, and each type acts against a certain microorganism or "non-self"

material by attaching to antigens on its surface. The presence of antigens triggers B-cells to multiply. Some develop into plasma cells, which are the main antibody-producing cells. As with cell-mediated immunity, memory cells are made, which can recognize the same antigen and initiate defence many years later.

**Memory B-cell**  
Some B-cells retain memory of the antigen from a previous infection

**Plasma cell**  
Produces antibodies specific to antigen protein

**Antibodies**  
Float in blood and other fluids

**Macrophage**  
Engulfs antibody-antigen complex

**Transport to lymph node**  
Macrophages travel in blood and lymph

**Lymph node**  
Macrophages engulf microbes and debris and present antigens to T-cells

**Presentation**  
Macrophage presents antigens from microbe to B-cell

**Antibody-antigen reaction**  
Antibodies stick to antigen sites on microbe, forming antibody-antigen complexes (immune complexes)

**Membrane breached**  
Complement proteins break outer membrane

**Additional help**  
The complement pathways can destroy microbes by disrupting their membranes in a process called lysis (see p.200)

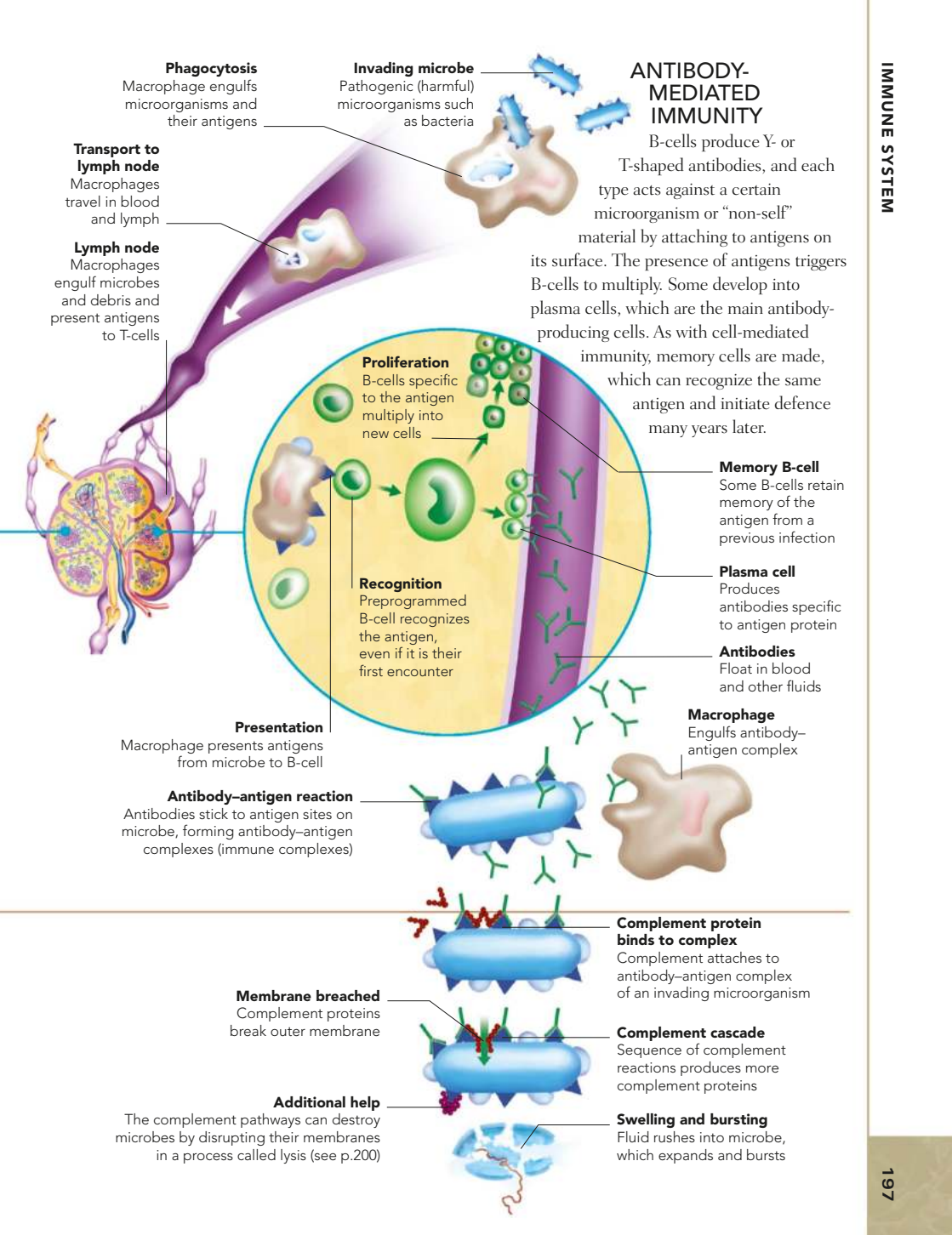
**Proliferation**  
B-cells specific to the antigen multiply into new cells

**Recognition**  
Preprogrammed B-cell recognizes the antigen, even if it is their first encounter

**Complement protein binds to complex**  
Complement attaches to antibody-antigen complex of an invading microorganism

**Complement cascade**  
Sequence of complement reactions produces more complement proteins

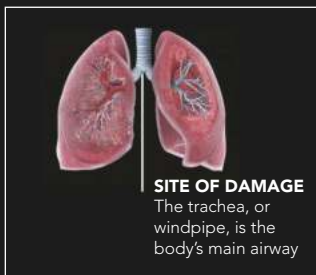**Swelling and bursting**  
Fluid rushes into microbe, which expands and bursts



# INFLAMMATORY RESPONSE

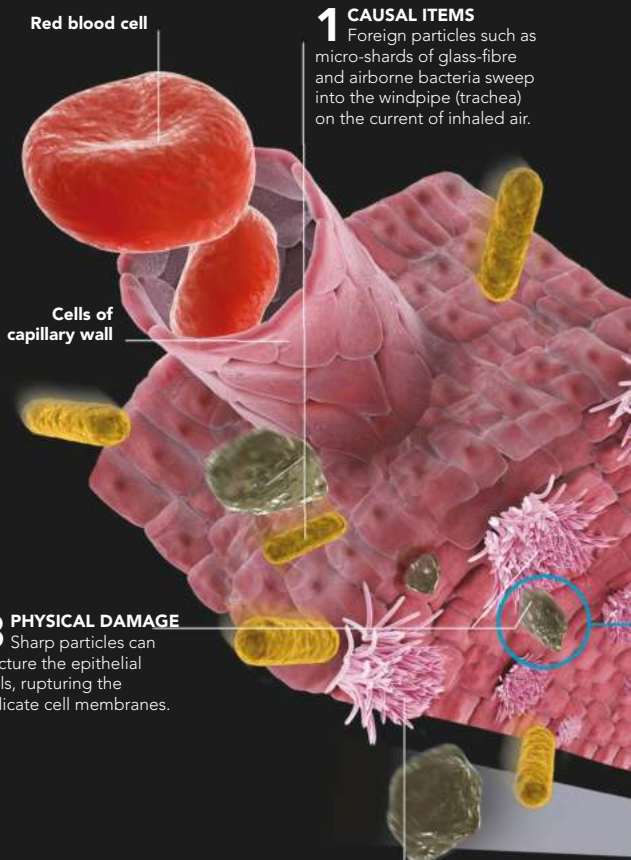
INFLAMMATION IS THE BODY'S RAPID, GENERAL RESPONSE TO ANY KIND OF INSULT OR INJURY, SUCH AS FROM PHYSICAL WOUNDS AND FOREIGN OBJECTS, INFECTING ORGANISMS, CHEMICAL TOXINS, HEAT, OR RADIATION.

The inflammatory response is a non-specific reaction that passes through defined phases and involves various types of white blood cell and defensive chemicals. The four cardinal signs are redness, swelling, heat, and pain. The process acts to attack, break down, and remove invading material, to dispose of the body's damaged cells and tissues, and to initiate healing.



## CAUSE OF INFLAMMATION

The respiratory system is under constant threat from tiny inhaled particles of dust and debris and attack by infecting microbes. Here, the lining (epithelium) of the windpipe (trachea) mounts an inflammatory response to dust and bacteria. In reality, this process usually occurs alongside the specific immune response (see p.196), which targets individual foreign substances.



### 1 CAUSAL ITEMS

Foreign particles such as micro-shards of glass-fibre and airborne bacteria sweep into the windpipe (trachea) on the current of inhaled air.

### 3 PHYSICAL DAMAGE

Sharp particles can fracture the epithelial cells, rupturing the delicate cell membranes.

### Tufts of cilia

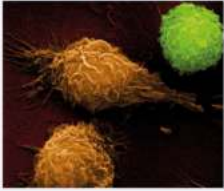
Hair-like projections borne by some cells of the tracheal lining; the cilia "beat" to remove protective mucus covering the cells



## DEFENSIVE CELLS

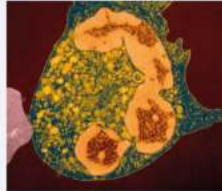
Various types of white blood cell (leucocytes) become involved in inflammation, including the defensive cells called neutrophils and monocytes (see p.194). The monocytes are

immature when they leave the blood vessels and enter the tissues. However, they rapidly develop into active cells called macrophages that replace neutrophils.



### NEUTROPHILS

Among the first cells to take action, these are small but capable of engulfing several pieces of damaged tissue and bacteria.



### MACROPHAGE

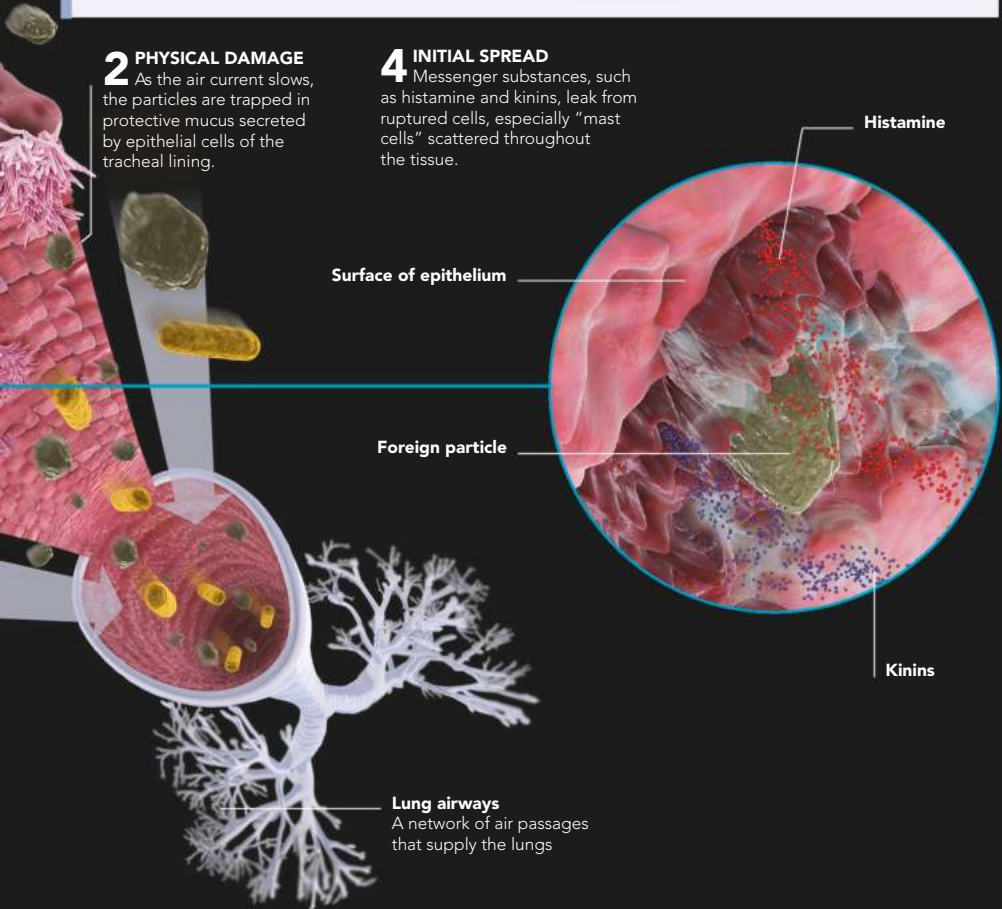
A single macrophage, which means "big eater", can consume up to 100 bacteria or similar-sized items before dying.

## 2 PHYSICAL DAMAGE

As the air current slows, the particles are trapped in protective mucus secreted by epithelial cells of the tracheal lining.

## 4 INITIAL SPREAD

Messenger substances, such as histamine and kinins, leak from ruptured cells, especially "mast cells" scattered throughout the tissue.

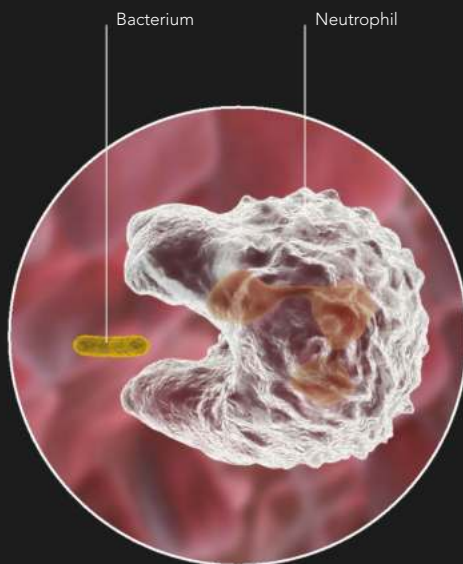


## PHAGOCYTOSIS

Various kinds of white blood cell can surround, engulf, and ingest smaller items, such as bacteria and cellular debris, in a process known as phagocytosis (“cell eating”). The cell exploits its ability to change shape and move, using the intracellular components of microtubules and microfilaments (see p.26) that form its flexible, mobile, internal scaffolding. The ingestion usually takes less than one second, and the consumed material is gradually broken down by enzymes and other chemicals within the cell.

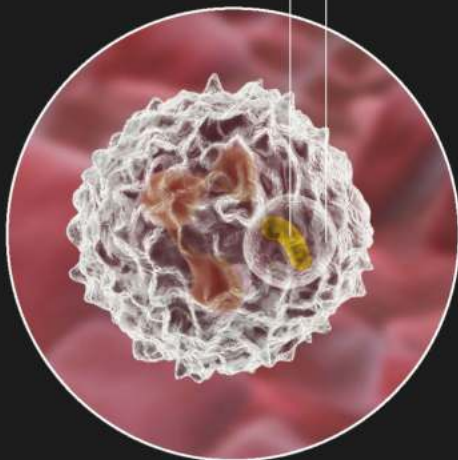
### 1 ENGULFING STAGE

The white cell extends pseudopods (“false feet”) towards and around the unwanted item – here a bacterium. The pseudopods merge to engulf it.

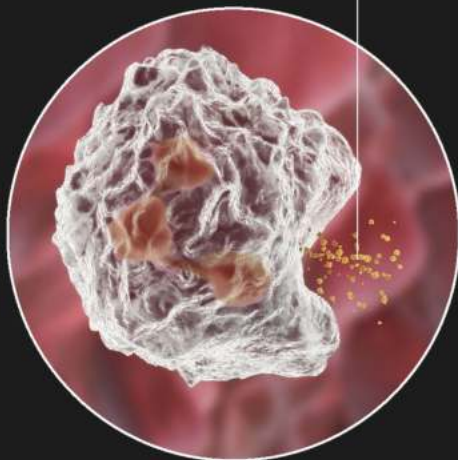


Bacterium is digested

Digestive vesicle



Expulsion of waste products



### 2 LYSIS STAGE

Any unwanted items are trapped in phagocytic vesicles. Together with enzyme-containing lysosomes, these digestive vesicles form phagolysosomes, where lysis (breaking down) occurs.

### 3 EXOCYTOSIS STAGE

Harmless waste products of cell-eating are expelled through the membrane of the white blood cell, or in tiny, membrane-bound, exocytic vesicles, to the extracellular fluid.

**1 CAPILLARIES DILATE**

Histamine stimulates widening of capillaries (vasodilation). As their walls stretch and become thinner, narrow gaps appear and make them more permeable to fluids.

**2 FLUID LEAKAGE**

Increased blood flow produces redness and heat. Plasma (blood's liquid component, pictured as yellow) leaks into the space between the cells, carrying various proteins such as fibrinogen, which helps blood to clot when the skin is broken.

**3 FLUID ACCUMULATION**

Plasma and escaped fluids from damaged cells gather in tissue spaces, causing swelling. This presses on nerve endings, which helps to cause the fourth sign of inflammation – pain.

**4 NEUTROPHILS ARRIVE**

Neutrophils press on the inner lining of capillaries, a stage called margination. They squeeze through the capillary walls in a process called diapedesis, as they leave the blood and enter the tissues.

**Foreign particle**

**Bacterium**

**5 NEUTROPHILS ENTER TISSUES**

Neutrophils are attracted to the damaged tissue by chemical substances the disrupted cells release. This chemically-stimulated movement is termed chemotaxis.

**Particle**

Remains lodged at site of cell damage and continues to release histamine and kinins (see p.199), which flow into the bloodstream

**Bronchial tree**

May be affected by inflammation, or the problem may remain restricted to a patch of the trachea

**RESPONSE**

Once an inflammatory response is triggered, more blood flows to the damaged area. The capillaries widen and become more permeable, allowing plasma and fluid to leak into the space between the cells. White blood cells, such as neutrophils, leave the blood and enter the tissue, drawn to the damaged area by chemicals released from the disrupted cells.

# FIGHTING INFECTIONS

AN INFECTION OCCURS WHEN MICROORGANISMS ENTER THE BODY, THEN SURVIVE, MULTIPLY, AND DISRUPT CELL FUNCTION. THE INFECTION MAY BE LOCAL, SUCH AS IN A WOUND, OR SYSTEMIC, IN WHICH MANY PARTS OF THE BODY ARE AFFECTED.

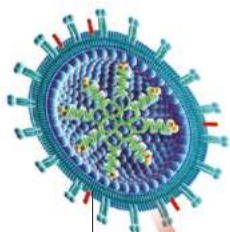
## VIRUSES

Viruses are the smallest microbes; millions would cover the head of a pin. Many types of virus can stay inactive for long periods and survive freezing, boiling, and chemical attack. Yet they can activate suddenly when an opportunity of invading a living cell arises. Viruses are obligate parasites, which

means they must have living cells, or host cells, in order to replicate themselves. The typical virus particle has a single or double strand of genetic material (nucleic acid – either DNA or RNA) surrounded by a shell-like coat of protein (capsid), and sometimes a protective outer envelope.

## LIFE CYCLE OF A VIRUS

Viruses have very few genes (typically 100–300) and cannot process nutrients. To build copies of itself, a virus takes over a host cell's machinery, causing the cell to die or malfunction.



### 1 FREE VIRUS PARTICLE

The complete virus particle, known as a virion, is capable of independent survival and then infection.

### Genetic material

Influenza carries its genetic material as RNA rather than DNA and arranges it on eight segments

### 2 INSERTION OF VIRUS

Viral surface proteins attach to specific receptor sites on the host cell's surface. After attaching itself, part or all of the virus penetrates the host cell.

### 4 NUCLEIC ACID REPLICATION

The host cell makes many copies of the viral RNA molecule and the viral protein coat, using its raw materials and its enzymes.

### 3 NUCLEIC ACID INSERTION

Viral RNA enters the nucleus and then joins the host's nucleic acid. It then replicates itself in great numbers before moving towards the cell's surface.

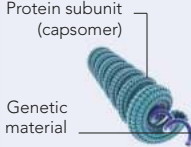
**Virus in host cell**  
Virus sheds its protein coat so RNA can enter host nucleus

## VIRUS SHAPES

There are thousands of different types of virus, with various shapes, such as balls, boxes, polygons, sausages, golfballs, spirals, and even tiny "space rockets". Viruses are classified by their size, shape, and symmetry as well as by the disease or groups of diseases they cause. Some, such as the complex virus known as the T4 bacteriophage, attack human pathogenic bacteria.

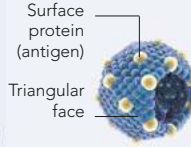
### Spiral (helical)

The protein coat is corkscrew-like, with the genetic material entwined. Examples include myxoviruses and paramyxoviruses.



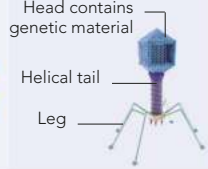
### Icosahedral

Twenty equal-sided triangles connect to form a faceted container. Examples include adenoviruses and herpes viruses.



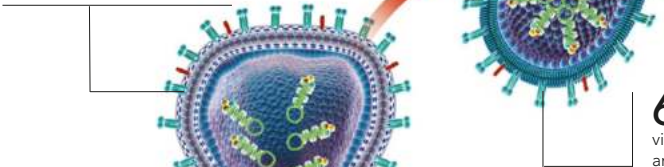
### Complex

Complex viruses resemble a tiny rocket with "landing legs" that settle onto the surface of the host cell. They only attack bacteria.




## 5 BUDDING VIRUS

The nucleic acid (RNA) strands and protein-coat subunits join to form new virus particles. These form buds in the host cell membrane, using part of the membrane as their outer protective envelope.



## 6 RELEASE

The buds separate as free virus particles, ready to spread and infect more cells. All eight separate segments of genetic material (RNA) must be present for the virus to successfully carry the infection further.



### Infected host cell

Host cell may not die after being invaded by an enveloped virus

Viral proteins

### Viral genes are "read"

Short fragments of viral RNA (genes) are read to produce viral proteins

### Replication complete

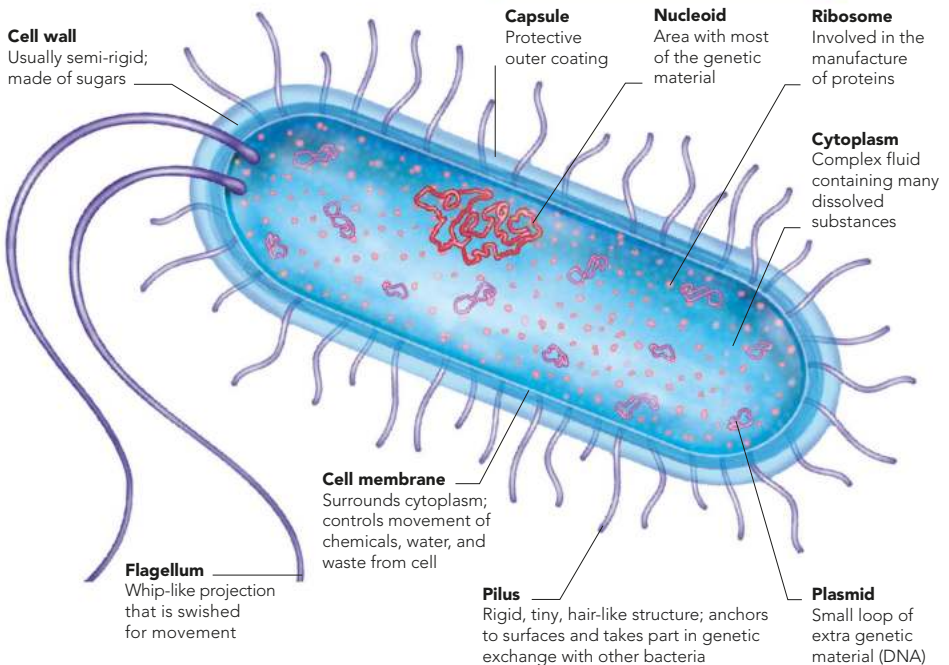
Duplicated viral RNA escapes through nuclear envelope

## BACTERIA

The microorganisms known as bacteria are present almost everywhere – in soil, water, air, food, drink, and on and in our own bodies. Many types of bacteria are harmless; indeed, those present naturally in the human intestines, the “gut flora”, have a beneficial effect in helping to extract nutrients from food. However, hundreds of types of bacteria can cause infections, ranging from mild to lethal. Bacteria are simpler than other single-cell organisms in that their genetic material (DNA) is free in the cell, rather than contained in a membrane-bound nucleus.

### STRUCTURE OF A BACTERIUM

A typical rod-shaped bacterium (bacillus) has a cell membrane enclosing cytoplasm and organelles, such as ribosomes, which are distributed in it. Unlike animal cells, it has a semi-rigid cell wall outside its cell membrane.



### BACTERIAL SHAPES

There are several typical shapes for bacteria, and these, along with the way they are coloured by laboratory stains, are important for classification and working out their origins and relationships. Many thousands of bacterial types are known, with more discovered each year.

#### Cocci

Generally spherical, may exist in clumps, chains, or pairs. Examples include *Staphylococcus* and *Streptococcus*.




#### Bacilli

Oval, or rod-like, with or without surface hairs or flagella. Examples include *Streptobacillus*.



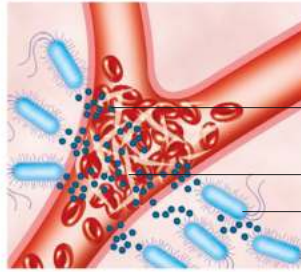
#### Spirilla

Spiral or, more accurately, helical (corkscrew-like) in shape. Examples include *Leptospira* and *Treponema*.



## HOW BACTERIA CAUSE DAMAGE

Disease-causing bacteria can enter the body in several ways: via the airways or digestive tract, during sexual contact, or through broken skin. Some bacteria adhere to and invade body cells. Others produce poisonous substances called bacteriotoxins, or toxins, which may disrupt cell function. For example, the diphtheria toxin from the bacterium *Corynebacterium diphtheriae* damages heart muscle by inhibiting protein production. Some toxins are highly dangerous. A bucket of nerve toxin from *Clostridium botulinum* could kill everyone in the world.



Released toxins

Clot forming

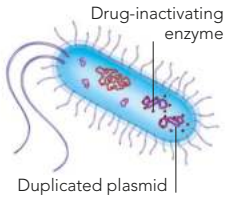
Bacterium

### LEAKING VESSELS

Some bacteria release toxins that cause blood to clot in small blood vessels, depriving tissues and organs of their normal blood supply.

## 1 ROLE OF PLASMIDS

A plasmid may cause a bacterium to make enzymes against antibiotics, or to alter its surface receptors, where antibiotics bind. Then the plasmid duplicates itself.

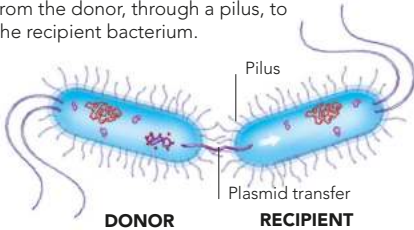


## RESISTANCE TO ANTIBIOTICS

Many bacteria become resistant to antibiotics by changing (mutating) into new strains. Their most effective mechanism is the transfer of plasmids – fragments of the genetic material DNA – between bacteria. The gene for antibiotic resistance crops up by accident, and the bacterium possessing it can pass it to others.

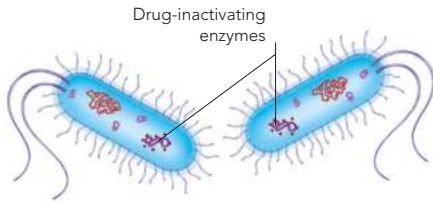
## 2 PLASMID TRANSFER

Plasmid transfer takes place during a process known as conjugation. The plasmid copy is passed from the donor, through a pilus, to the recipient bacterium.



## 3 DRUG-RESISTANT STRAINS

Recipient bacteria inherit the resistant gene. Plasmid transfer produces populations of bacteria resistant to a range of antibiotics.

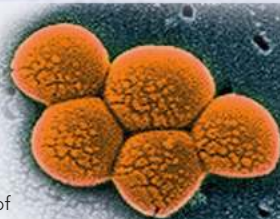

## SUPERBUGS

Some bacteria pass through their life cycle in less than 20 minutes. Fast reproduction, coupled with the incredible numbers of bacteria and rapid transfer of genetic information, gives great scope for mutation (see above). Many strains of bacteria resistant to wide-acting, or broad-spectrum, antibiotics have appeared. These so-called "superbugs" may not be resistant to more specialist, narrow-spectrum, antibiotics.

### MRSA

*Staphylococcus aureus* bacteria resistant to the antibiotic meticillin are known as MRSA, and are a cause of concern in hospitals.

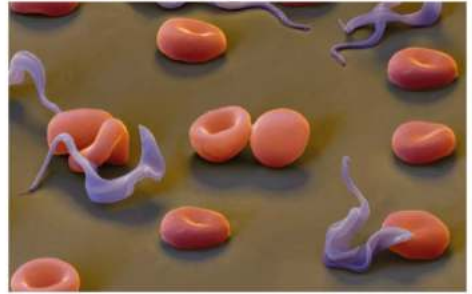
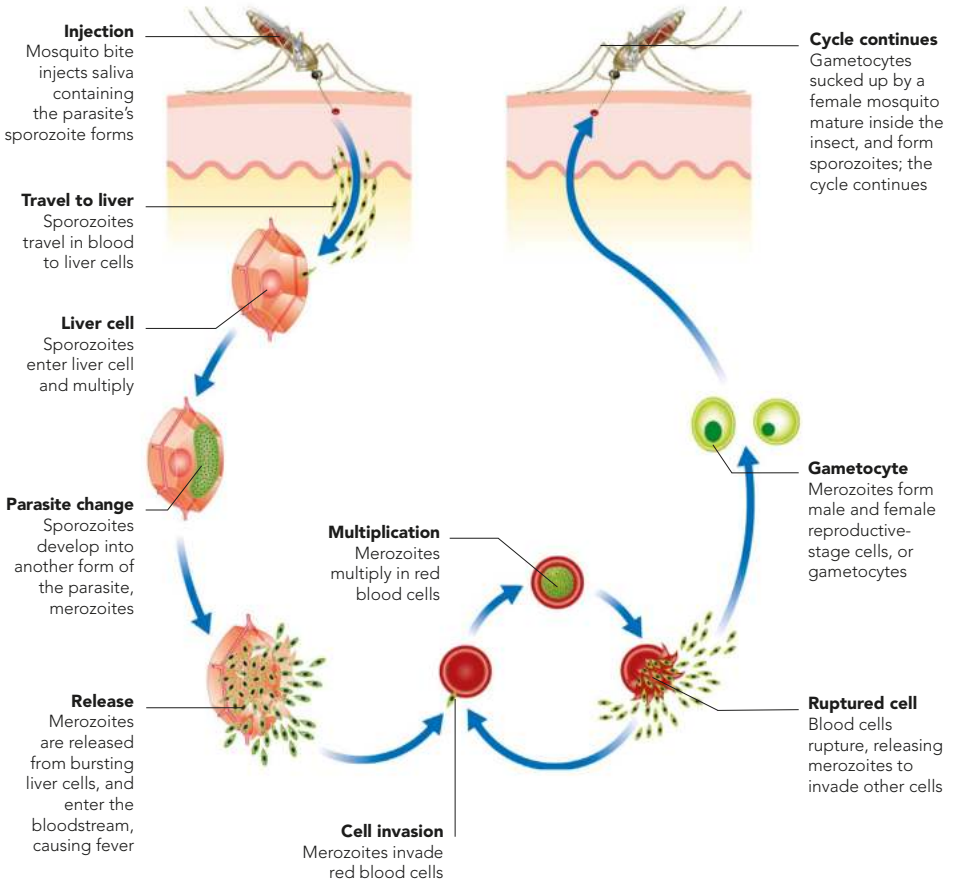


## PROTISTS (PROTOZOA)

Protists are single-celled organisms with genetic material contained in a nucleus. Animal-like protists, sometimes called protozoa, are common and usually harmless, although some, such as *Plasmodium*, cause serious diseases.

### MALARIAL LIFE CYCLE

Five types of *Plasmodium* cause malaria. They are spread by the female *Anopheles* mosquito. Malaria produces chills and high fever, which can recur and prove fatal if not treated. Most *Plasmodium* have a similar life cycle (see below).



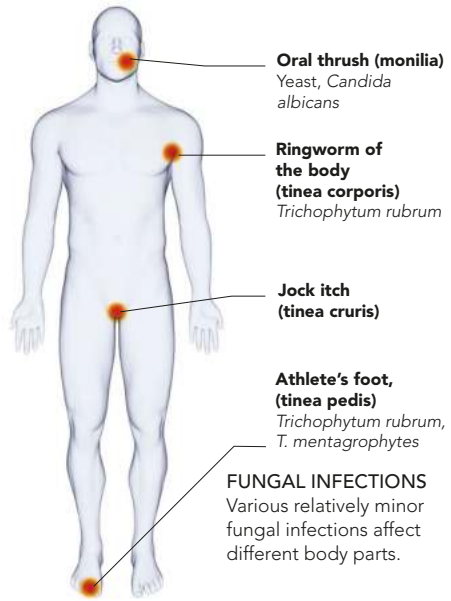
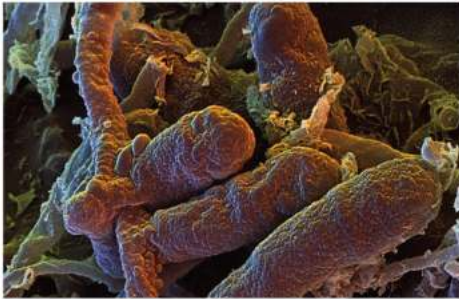### TRYPANOSOMES IN BLOOD

Trypanosomes are worm-like protists (purple), seen here with red blood cells. They cause a disease called trypanosomiasis, or sleeping sickness.



## FUNGI

Disease-causing fungi fall into two main groups: filamentous fungi and single-celled yeasts. Some types – for example, thrush – cause fairly harmless diseases of the skin, hair, nails, or mucous membranes. Others, such as histoplasmosis, result in potentially fatal infections of vital organs such as the lungs. Some infections may be linked to specific occupations such as farming, while others – ringworm (dermatophytosis), for example – are more likely to affect people with damaged immune systems, such as those with HIV–AIDS.

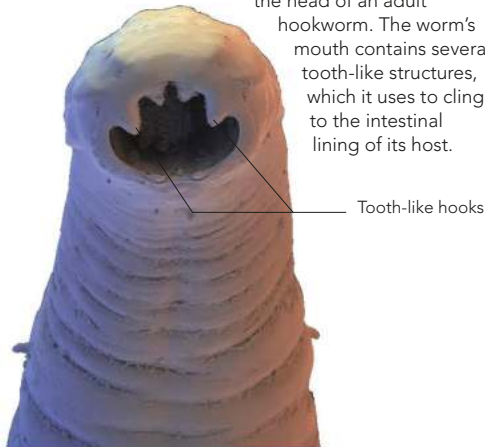


### CAUSE OF ATHLETE'S FOOT

Seen here are microscopic threads of the fungus *Epidermophyton floccosum*, one cause of the white, itchy skin of athlete's foot.

### HOOKWORM

This microscope image shows the head of an adult hookworm. The worm's mouth contains several tooth-like structures, which it uses to cling to the intestinal lining of its host.



## PARASITIC WORMS

Humans, like most other animals, can be infested with parasitic worms that derive all their nutrients from their hosts. At least 20 types of worm-like animals may live in the body as parasites. Most spend at least part of their life cycle in the intestines. A few are members of the annelids, a group of segmented worms that includes common earthworms. Several are roundworms, or nematodes – for example, the hookworm *Ancylostoma duodenale*, which is 1 cm ( $\frac{4}{5}$ in) long and lives in the gut. Another worm-like group is the flatworms; it includes the tapeworms, such as *Taenia*, which live in the gut and may reach 9m (30ft) in length, and flukes, such as *Schistosoma*, which causes schistosomiasis, or snail fever.

# IMMUNE SYSTEM DISORDERS

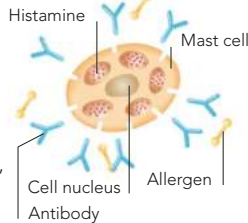
THE IMMUNE SYSTEM SOMETIMES OVER-REACTS, CAUSING AN ALLERGIC RESPONSE. WHEN THE SYSTEM IS WEAK, IMMUNIZATION CAN HELP TO BOOST IT. HOWEVER, IT MAY BECOME SO WEAK – BY AN HIV INFECTION, FOR EXAMPLE – THAT EVEN ORDINARY INFECTIONS CAN BE DANGEROUS.

## ALLERGIES

When first exposed to an allergen, such as nuts or pollen, the immune system makes antibodies to fight it. The antibodies coat the surface of mast cells in the skin, stomach lining, lungs, and upper airways. If the allergen enters the body again, these cells mount an allergic response.

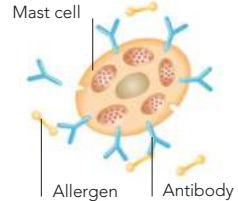
### 1 EXPOSURE

The first time an allergen enters the body, antibodies bind to the surface of mast cells. These cells contain histamine, which normally causes inflammation.



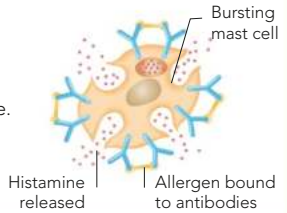
### 2 ANTIBODIES

When the allergen returns, the antibodies are triggered into action. If the allergen links two or more antibodies together, the cell bursts.



### 3 HISTAMINE

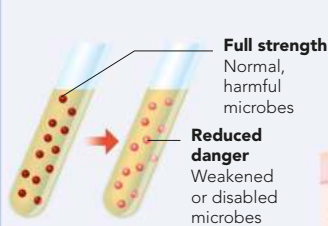
As the cell bursts, it releases histamine, which causes an inflammatory response. This irritates body tissues and produces all the symptoms of an allergy.



## IMMUNIZATION

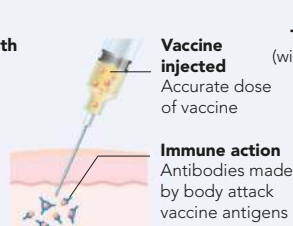
The process of becoming resistant or immune to a particular microbe as a result of infection is known as natural immunization. Resistance can also be developed artificially. In active immunization, dead or weakened versions of the microbe or its toxic products are injected into the body. The immune response occurs, with the production of antibodies,

but the illness does not develop. If urgent protection is needed, or if an immune system is weak, passive immunization can be used by injecting ready-made antibodies. These antibodies provide swift resistance against the microbes, but they gradually degenerate and are not replaced. The body has no memory for making them again.



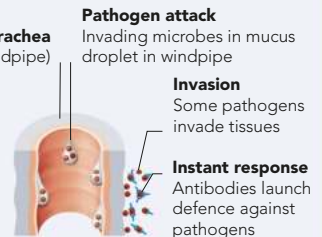
### 1 VACCINE PRODUCTION

A vaccine contains complete or partial microbes, or the toxins they make. It can stimulate the immune response but not cause symptoms.



### 2 VACCINE DELIVERY

Vaccination stimulates the body's immune system to raise antibodies against the antigens on the disease-carrying organisms.



### 3 IMMUNE RESPONSE

A pathogen against which the body has been vaccinated alerts the memory cells, and so the immune system launches an instant defence.

# HIV INFECTION

HIV is carried in blood, semen, vaginal secretions, and breast milk. It is passed on when infected fluids enter the body. HIV infects cells with structures called CD4 molecules on their surface. These CD4+ cells include lymphocytes, which fight infection. The virus multiplies rapidly in CD4+ cells, destroying them in the process. If HIV goes untreated, the number of CD4+ lymphocytes eventually falls so low that the immune system is severely weakened.

## AIDS

HIV can be identified by specific blood or fluid tests. Being HIV positive may lead to AIDS-related illnesses, especially opportunistic infections, caused by organisms that are harmless to healthy people but dangerous to those with reduced immunity; one example is infection by *Candida albicans*, which causes thrush. People who have AIDS may also develop various types of cancer, notably Kaposi's sarcoma.

### 1 FREE HIV PARTICLE

The capsid contains two strands of RNA, each carrying a set of genes for the virus. The spikes on the surface are proteins called gp120 antigens that enable the virus to "dock" on the surface of CD4+ cells.

### 2 BINDING AND INJECTION

The gp120 binds to CD4 molecules and then to co-receptors on the cell surface. The virus fuses with the cell, penetrating the surface. The capsid releases the viral RNA.

### 3 REVERSE TRANSCRIPTION

The virus releases reverse transcriptase into the cell. The enzyme copies the single strands of viral RNA as double-stranded DNA.

### 4 INSERTION OF VIRAL DNA

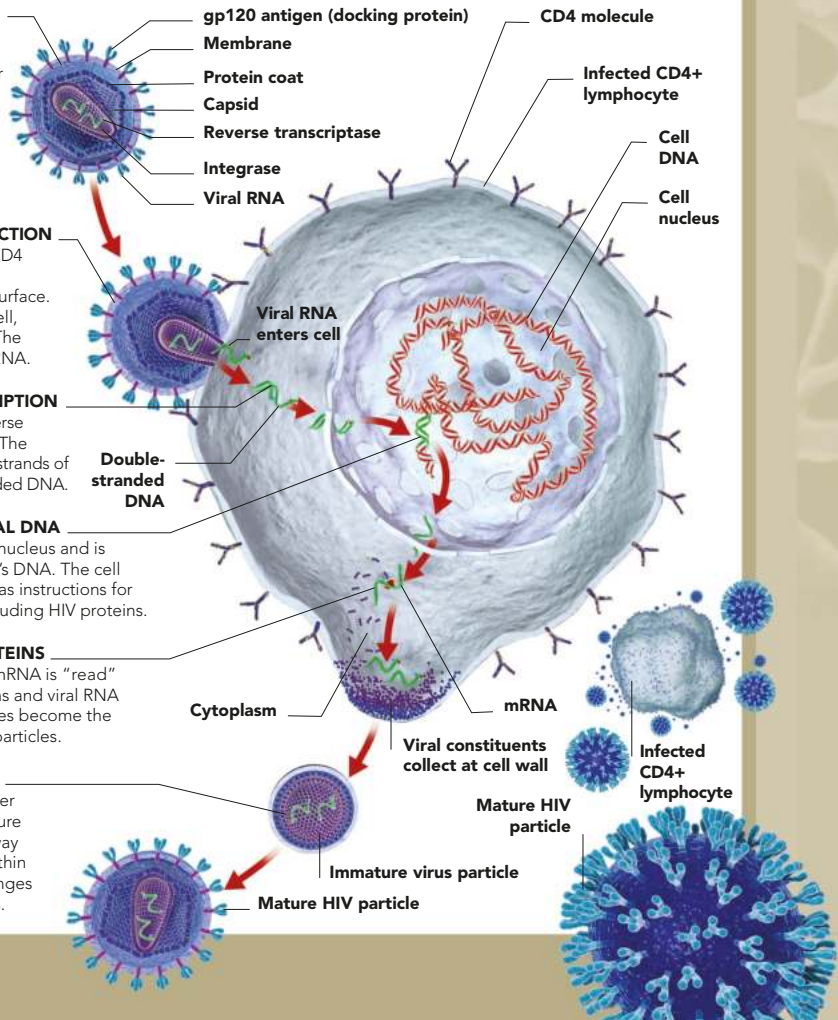
Viral DNA enters the nucleus and is incorporated into the cell's DNA. The cell produces mRNA, which has instructions for making new proteins, including HIV proteins.

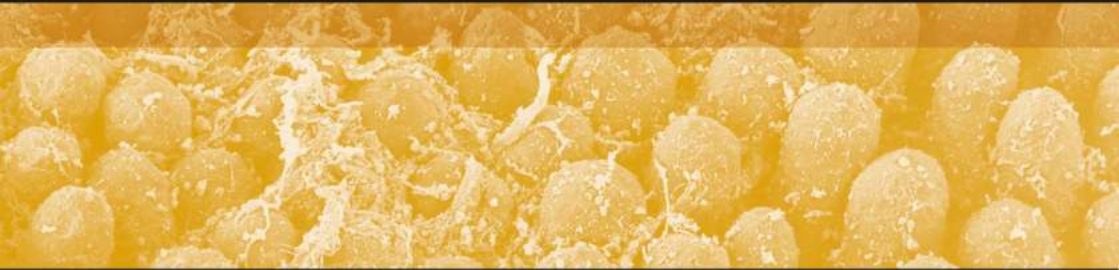
### 5 CREATION OF PROTEINS

In the cytoplasm the mRNA is "read" and chains of HIV proteins and viral RNA are made. These molecules become the components of new HIV particles.

### 6 NEW HIV CREATED

HIV constituents gather at the cell wall. An immature virus forms and breaks away from the cell. Enzymes within the virus bring about changes resulting in a mature virus.





PEOPLE ARE PROBABLY MORE AWARE OF THEIR DIGESTIVE SYSTEM THAN OF ANY OTHER SYSTEM BECAUSE OF ITS FREQUENT MESSAGES. HUNGER, THIRST, WIND (GAS), AND BOWEL MOVEMENTS ALL AFFECT DAILY LIFE. EATING WELL AND REGULAR EXERCISE ARE THE BEDROCKS OF GOOD DIGESTIVE HEALTH. PLENTY OF FRESH VEGETABLES AND FRUIT, ADEQUATE FIBRE, AND A LOW INTAKE OF ANIMAL FATS AND SALT ARE SIMPLE GUIDELINES FOR MAINTAINING NOT JUST THE WELLBEING OF THE DIGESTIVE SYSTEM BUT THAT OF THE WHOLE BODY.



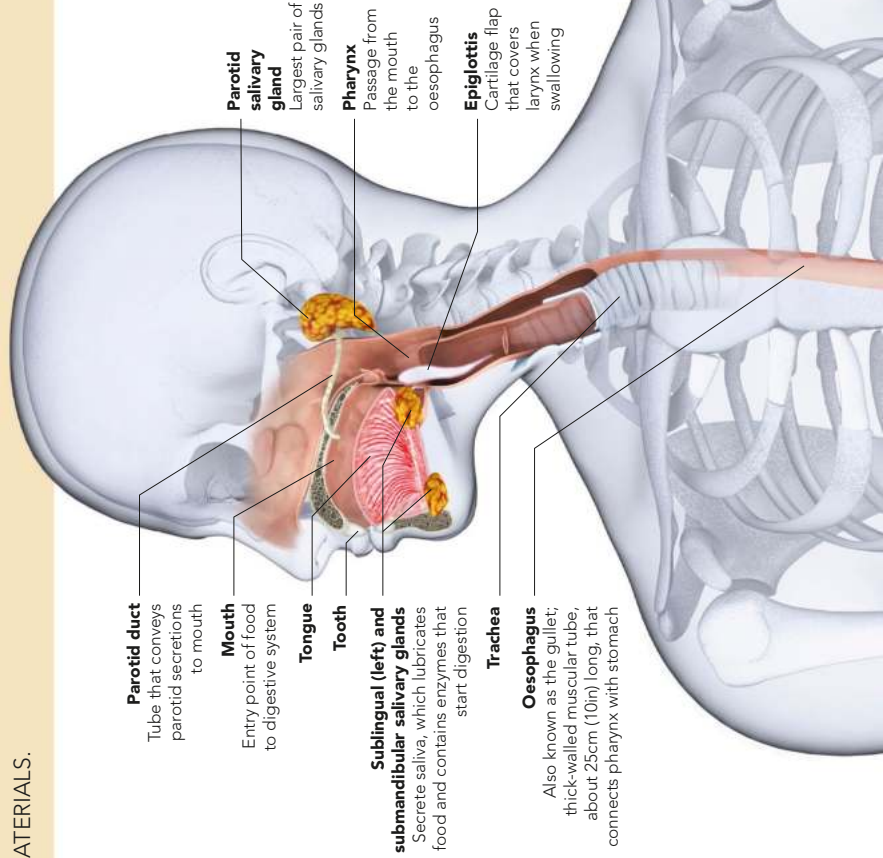
# DIGESTIVE SYSTEM



# DIGESTIVE ANATOMY

THE DIGESTIVE TRACT AND ITS ASSOCIATED ORGANS, INCLUDING THE LIVER, GALLBLADDER, AND PANCREAS, BREAK DOWN FOOD, EXTRACT NUTRIENTS, AND DISPOSE OF WASTE MATERIALS.

After being eaten, or ingested, food embarks on a journey. It can take up to 24 hours to cover a distance of 9m (30ft), through various muscular tubes and chambers. The process begins at the mouth, where food is crushed and ground down by the teeth during chewing. The resulting ball, or bolus, of food continues down the throat (pharynx), then travels through the gullet (oesophagus) to the stomach, small intestine, large intestine, and anus. In the small intestine, chemicals break down food into molecules small enough to absorb into the blood. What cannot be digested is compacted as faeces in the large intestine and eliminated through the anus. Food travels through the system by a process of muscular contraction called peristalsis. The digestive system includes several glands: the spit-making salivary glands; the pancreas, which produces powerful digestive juices; and the body's major nutrient processor, the liver.



**Parotid duct**

Tube that conveys parotid secretions to mouth

**Mouth**

Entry point of food to digestive system

**Tongue**

**Tooth**

**Sublingual (left) and submandibular salivary glands**

Secrete saliva, which lubricates food and contains enzymes that start digestion

**Trachea**

**Oesophagus**

Also known as the gullet; thick-walled muscular tube, about 25cm (10in) long, that connects pharynx with stomach

**Parotid salivary gland**

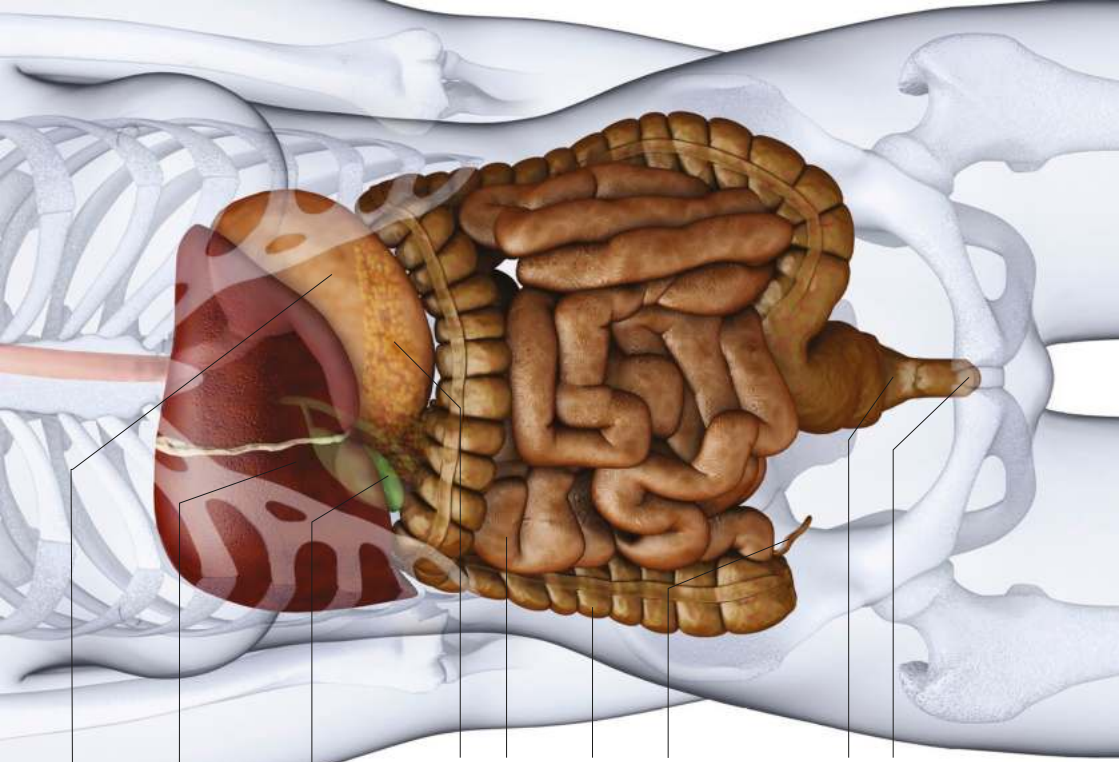
Largest pair of salivary glands

**Pharynx**

Passage from the mouth to the oesophagus

**Epiglottis**

Cartilage flap that covers larynx when swallowing



**Stomach**  
J-shaped muscular bag that churns, digests, and stores food

**Liver**  
Large organ that processes absorbed nutrients, detoxifies harmful substances, and produces bile

**Gallbladder**  
Stores bile produced by liver

**Pancreas (behind stomach)**  
Secretes digestive enzymes, which pour along a duct into first part of small intestine

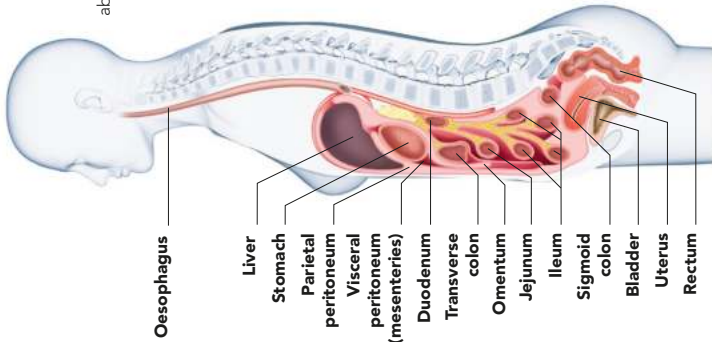
**Small intestine**  
Major site of digestion and absorption of nutrients

**Large intestine**  
Absorbs water from food residue, and forms and stores faeces

**Appendix**  
Also called the vermiform appendix; dead-end tube whose function, if it has one, is as yet unknown

**Rectum**  
Stores waste matter until it can be excreted conveniently

**Anus**  
Short, tube-like, muscular valve that relaxes to let out digestive waste



**Oesophagus**

**Liver**

**Stomach**

**Parietal peritoneum**

**Visceral peritoneum (mesenteries)**

**Duodenum**

**Transverse colon**

**Omentum**

**Jejunum**

**Ileum**

**Sigmoid colon**

**Bladder**

**Uterus**

**Rectum**

**THE PERITONEUM**

The two layers of the peritoneum make a fluid to reduce friction between organs. The parietal peritoneum lines the abdominal wall, and the organs hang from the visceral peritoneum within the abdomen. The omentum is a specialized fatty peritoneum hanging from the stomach.

# MOUTH AND THROAT

DIGESTION STARTS AT THE MOUTH WHERE FOOD IS CHEWED, LUBRICATED WITH SALIVA, TURNED INTO A SOFT, MOIST MASS CALLED A BOLUS, AND SWALLOWED.

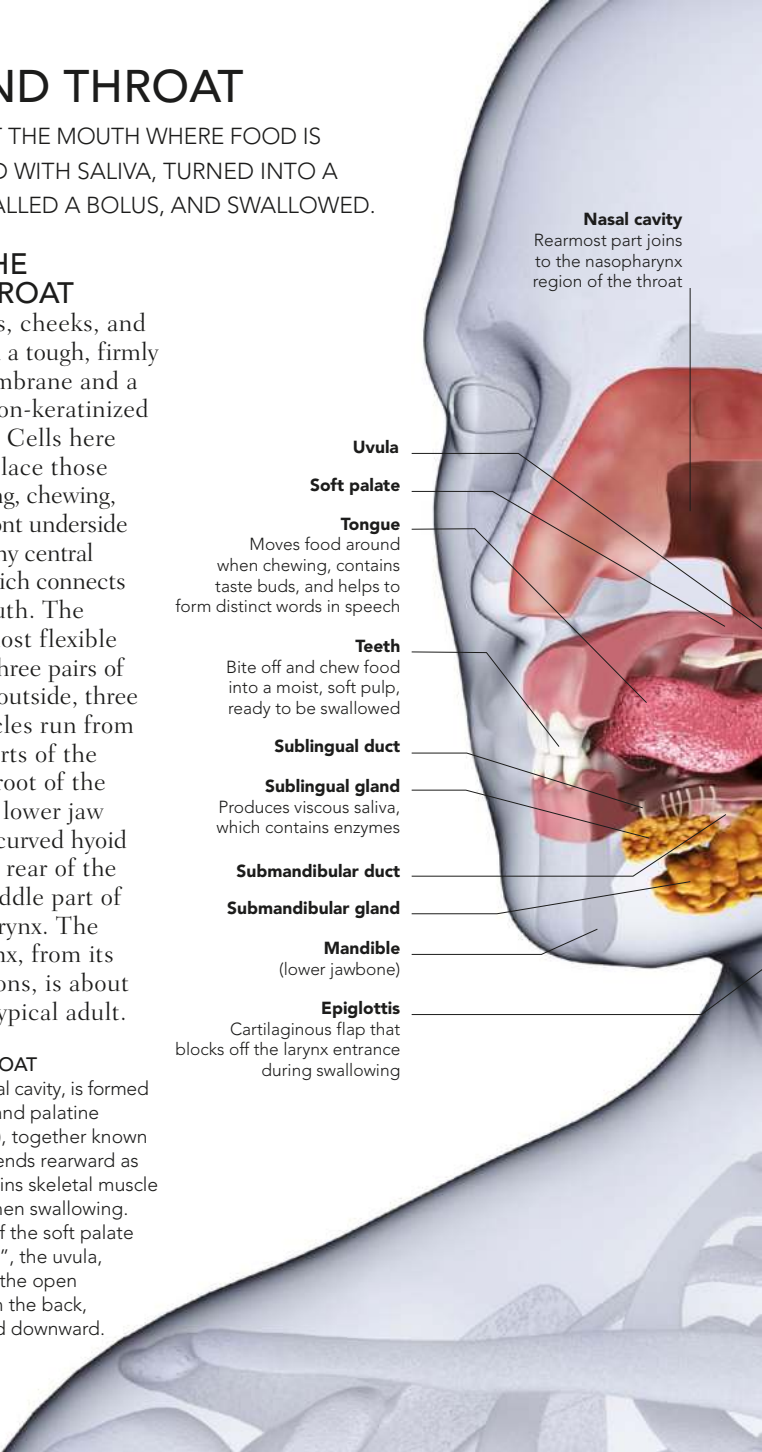
## ANATOMY OF THE MOUTH AND THROAT

The interior of the lips, cheeks, and oral cavity is lined with a tough, firmly anchored mucous membrane and a type of tissue called non-keratinized squamous epithelium. Cells here multiply rapidly to replace those rubbed away when biting, chewing, and swallowing. The front underside of the tongue has a fleshy central ridge, the frenulum, which connects to the floor of the mouth. The tongue is the body's most flexible muscle. Within it are three pairs of intrinsic muscles; and outside, three pairs of extrinsic muscles run from the tongue to other parts of the throat and neck. The root of the tongue anchors to the lower jaw (mandible) and to the curved hyoid bone in the neck. The rear of the mouth leads to the middle part of the throat, the oropharynx. The whole throat or pharynx, from its nasal to laryngeal regions, is about 13cm (5in) long in a typical adult.

### NOSE, MOUTH, AND THROAT

The roof of the mouth, or oral cavity, is formed by shelves of the maxillary and palatine bones of the skull (see p.49), together known as the hard palate. This extends rearward as the soft palate, which contains skeletal muscle fibres that allow it to flex when swallowing. The central posterior part of the soft palate extends into a small "finger", the uvula, which can be seen through the open mouth, dangling down from the back, where it helps to direct food downward.

**Nasal cavity**  
Rearmost part joins to the nasopharynx region of the throat

- 
- Uvula**
  - Soft palate**
  - Tongue**  
Moves food around when chewing, contains taste buds, and helps to form distinct words in speech
  - Teeth**  
Bite off and chew food into a moist, soft pulp, ready to be swallowed
  - Sublingual duct**
  - Sublingual gland**  
Produces viscous saliva, which contains enzymes
  - Submandibular duct**
  - Submandibular gland**
  - Mandible**  
(lower jawbone)
  - Epiglottis**  
Cartilaginous flap that blocks off the larynx entrance during swallowing



**Parotid (Stensen's) duct**

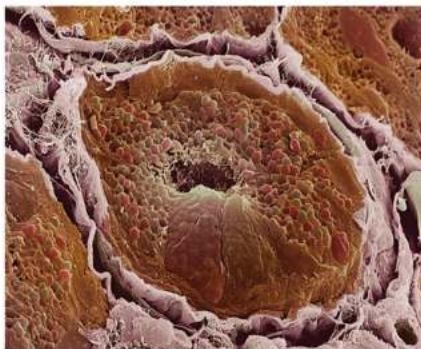
Opens into cheek lining, next to the upper second molar tooth

**Accessory parotid gland**

**Parotid gland**  
Largest of three paired salivary glands; produces watery saliva

**SALIVARY GLANDS**

Saliva is made by three pairs of salivary glands: the parotid glands, positioned in front of and just below each ear; the submandibulars, on the inner sides of the lower jawbone (mandible); and the sublinguals, in the floor of the mouth, below the tongue. In addition, many small accessory glands are found in the mucous membranes lining the mouth and tongue. Although it is composed of 99.5 per cent water, saliva also contains important solutes such as amylase, a digestive enzyme that begins the breakdown of starches, and salts. Saliva lubricates food to make chewing and swallowing easier, and it keeps the mouth moist between periods of eating.

**SALIVARY GLAND STRUCTURE**

Many small, rounded glandular units called acini (brown), separated by connective tissue (pink), discharge their saliva into tiny central ducts. Acinar ducts converge into the main saliva-carrying glandular ducts.

**Larynx (voicebox)**

**Oesophagus (gullet)**

**Trachea (windpipe)**

## TEETH

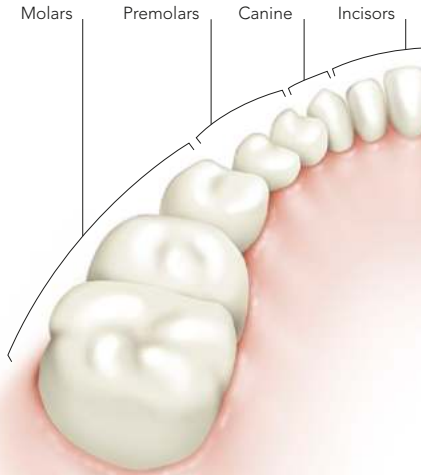
There are four types of tooth, each of which has a different role. The incisors, at the front, are chisel-shaped, with sharp edges for cutting food. The pointed canines, known as “eye teeth”, are designed for tearing food. The premolars, with their two ridges, and the flatter molars, which are the largest and strongest teeth, crush and grind food. The crown is the part of the tooth above the gum, while the root is embedded in the jawbone; and where these two meet, at the gum or gingival surface, is the neck of the tooth. The outer layer of the crown is made of a bone-like enamel, which is the hardest substance in the body. Beneath it is a layer of softer but still strong tissue called dentine, which is

shock-absorbing. At the centre of the tooth, the soft dental pulp contains blood vessels and nerves. Below the gum, bone-like cementum and periodontal ligament tissues secure the tooth in the jawbone.



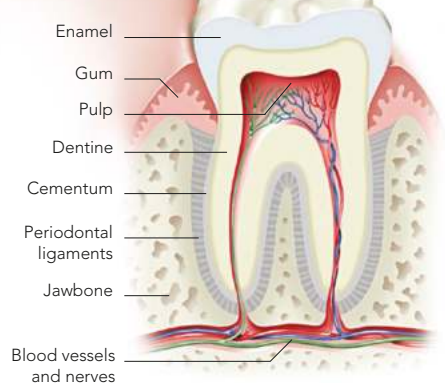
### ENAMEL SURFACE

This microscope image of enamel shows U-shaped enamel prisms packed with the crystalline mineral substance hydroxyapatite.



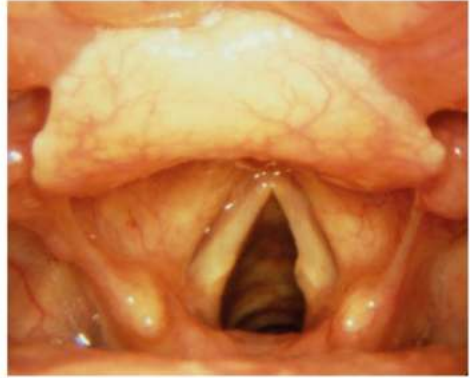### ADULT DENTITION

An adult typically has, in each side of each jaw, two incisors, one canine, two premolars, and three molars. This makes a total of 32 teeth. However, in some individuals certain teeth never grow or erupt out of the gum. This applies particularly to the four rearmost molars, known as “wisdom teeth”.



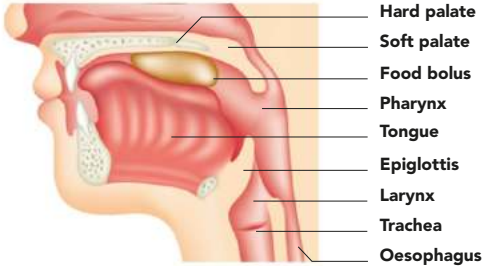
## SWALLOWING

The process of swallowing begins as a voluntary action, when the rear of the tongue pushes a bolus of food to the back of the mouth. To swallow a solid item such as a tablet without chewing demands concentration. It is easier to swallow a tablet with water, as drinks are usually gulped straight down after entering the mouth. Automatic reflexes control subsequent stages of swallowing, as the muscles of the throat contract and move the bolus rearward and down, and squeeze it into the top of the oesophagus. A flap of cartilage known as the epiglottis prevents food going down “the wrong way” into the larynx and the trachea, where it would cause choking.



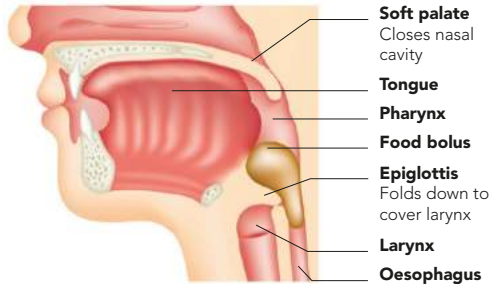
### VIEW INTO THE LARYNX

The pale, leaf-like flap of the epiglottis is visible at the top of this image. Immediately below it is the inverted “V” of the vocal cords.



### 1 PHARYNGEAL STAGE

Before the food bolus reaches the back of the mouth, the epiglottis is raised in its normal position.

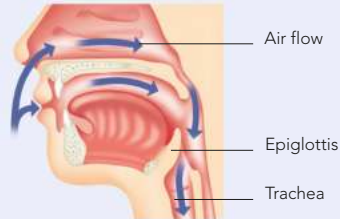


### 2 OESOPHAGEAL STAGE

The larynx rises to meet the tilted epiglottis, closing the trachea. The soft palate lifts to close the nasal cavity. The bolus is pushed down the oesophagus.

## BREATHE OR SWALLOW

The pharynx is a dual-purpose passageway: for air when breathing, and food, drink, and saliva when swallowing. Nerve signals from the brain operate the muscles of the mouth, tongue, pharynx, larynx, and upper oesophagus to prevent food from entering the trachea. If food is inhaled, irritation of the airway triggers the coughing reflex, which expels the inhaled particles and prevents choking. The complex muscle movements involved in swallowing are a voluntary reflex, and they also occur when solid matter contacts touch sensors at the back of the mouth.



### DUAL INTAKE

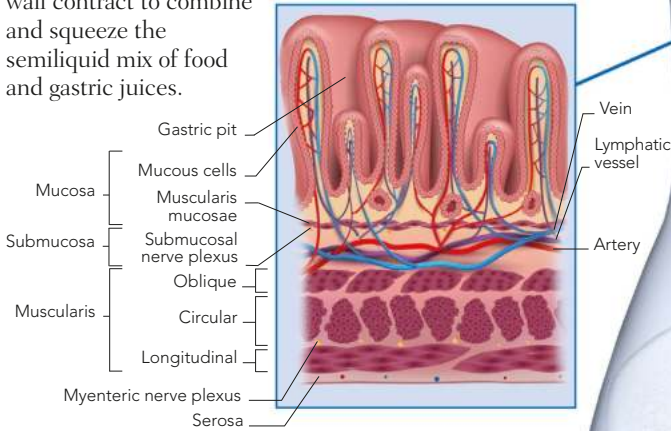
Breathing occurs through the nose or the mouth. The passageways of both meet at the throat, and air flows into the trachea.

# STOMACH AND SMALL INTESTINE

THE STOMACH DIGESTS FOOD CHEMICALLY AND PHYSICALLY. THE SMALL INTESTINE CONTINUES THE CHEMICAL BREAKDOWN AND ABSORBS NUTRIENTS.

## STOMACH STRUCTURE

The stomach is a muscular-walled, J-shaped sac in which food is stored, churned, and mixed with gastric juices secreted by its lining. The juices include digestive enzymes and hydrochloric acid, which breaks down food and kills potentially harmful microbes. The smooth muscles of the wall contract to combine and squeeze the semiliquid mix of food and gastric juices.



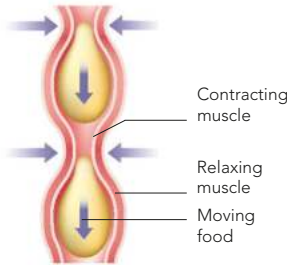
**Longitudinal**  
**Circular**  
**Oblique**  
The three muscle layers cause the stomach to twist and writhe into almost any shape

## LAYERS OF THE STOMACH WALL

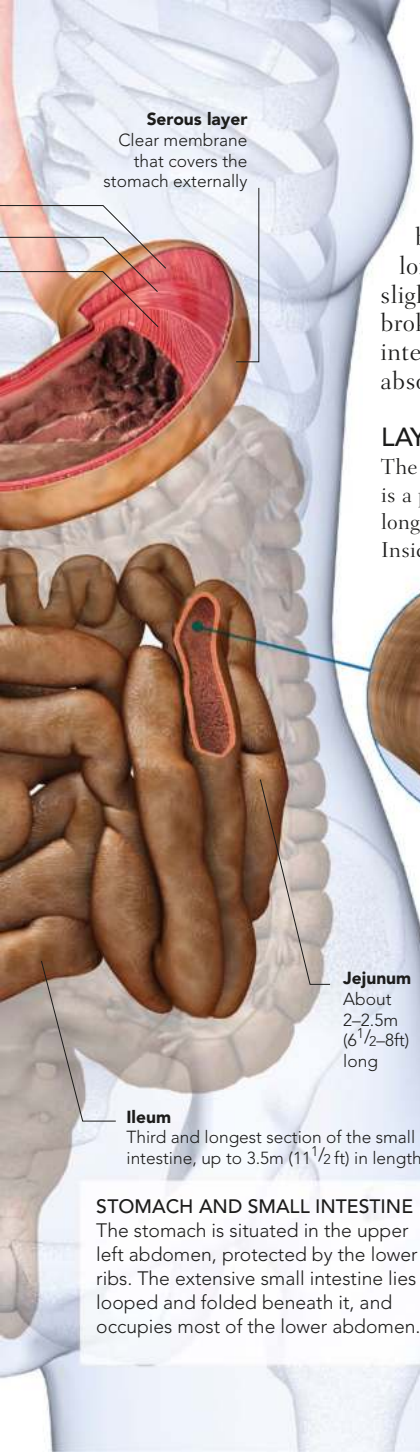
The stomach wall has four main layers; the mucosa, submucosa, muscularis, and serosa. The mucosa has deep infolds (gastric pits) that contain the gastric glands, and cells that produce acid (parietal cells), enzymes (zymogenic or chief cells), and hormones (neuroendocrine cells).

## PERISTALSIS

Waves of muscle contraction propel food through the digestive tract. The circular muscle contracts and relaxes in sequence, producing a "travelling wave" known as peristalsis.



**Duodenum**  
First and shortest section of the small intestine, about 25cm (10in) long

**Serous layer**

Clear membrane that covers the stomach externally

**ROLE OF THE SMALL INTESTINE**

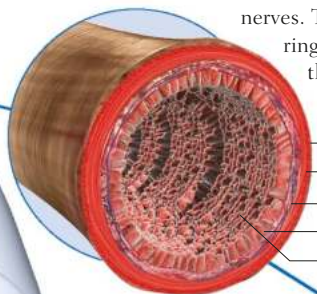
The duodenum, jejunum, and ileum make up the small intestine. The duodenum receives not only processed food, known as chyme, from the stomach but also digestive secretions from the liver (including bile) and the pancreas. The jejunum and ileum are both long and coiled, but the jejunum is thicker, redder, and slightly shorter. In the small intestine, the chyme is broken down further by pancreatic juices, bile, and the intestine's own secretions, so that nutrients can be absorbed into the blood and lymph circulations.

**LAYERS OF THE SMALL INTESTINE WALL**

The small intestine wall has four layers. The outermost serosa is a protective coat. Next is the muscularis, which has outer longitudinal muscle fibres and inner circular smooth fibres.

Inside this is the submucosa, a loose layer carrying vessels and nerves. The innermost mucosa forms

ring-like folds, called plicae circulares, that are covered by tiny, finger-like projections called villi.

**Serosa****Muscularis****Submucosa****Mucosa****Villus**

Fingerlike extension of mucosa up to 1mm ( $1/25$  in) long

**SECTION OF SMALL INTESTINE**

Lacteal (lymph capillary)

Blood capillary

Goblet cell

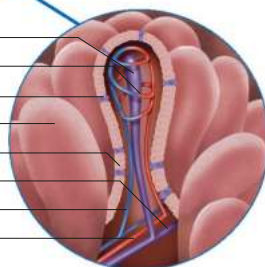
Villus

Epithelium

Lymph vessel

Vein

Artery

**Jejunum**

About 2–2.5m ( $6\frac{1}{2}$ –8ft) long

**Ileum**

Third and longest section of the small intestine, up to 3.5m ( $11\frac{1}{2}$ ft) in length

**STOMACH AND SMALL INTESTINE**

The stomach is situated in the upper left abdomen, protected by the lower ribs. The extensive small intestine lies looped and folded beneath it, and occupies most of the lower abdomen.

**INTESTINAL VILLI**

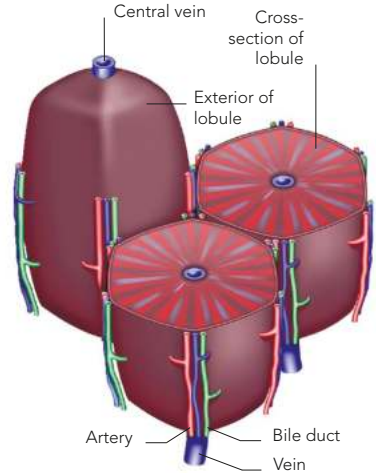
The epithelium of each villus lets digested nutrients pass into the interior, or lumen. Here, some pass into the lymph via a lacteal, and others enter the blood via a capillary and are carried to the liver. Epithelial cells have tiny microvilli, which increase the surface area of the small intestinal lining. Goblet cells scattered throughout the epithelium secrete mucus that helps the passage of food.

# LIVER, GALLBLADDER, AND PANCREAS

THE LIVER IS THE LARGEST INTERNAL ORGAN AND MAKES, PROCESSES, AND STORES MANY IMPORTANT CHEMICALS. THE GALLBLADDER STORES BILE, AND THE PANCREAS SECRETES VITAL DIGESTIVE ENZYMES.

## STRUCTURE AND FUNCTION OF THE LIVER

Weighing about 1.5kg (3 $\frac{1}{2}$ lb), the dark red liver is composed of lobules; these are made up of sheets of liver cells (hepatocytes), tiny branches of the hepatic artery and vein, and bile ducts. Nutrient-rich blood arrives from the intestines via the hepatic portal system (see p.222) and filters through the lobules. The liver has many functions, the most important of which are storing and releasing blood glucose for energy; sorting and processing vitamins and minerals; breaking down toxins into less harmful substances; and recycling old blood cells.



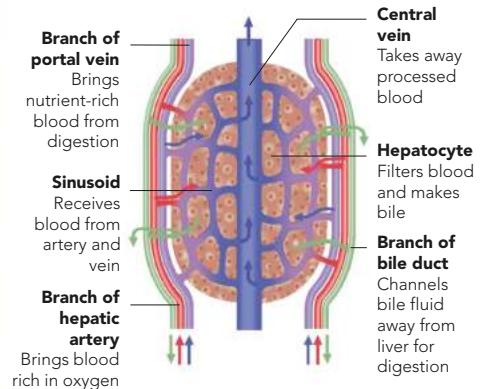
## LIVER FUNCTIONS

Most of the liver's tasks are concerned with the process of metabolism. They include breaking down, storing, and circulating vital substances, and constructing complex molecules, such as enzymes.

<b>BILE PRODUCTION</b>	Secretes bile into ducts that lead to the gallbladder.
<b>NUTRIENT PROCESSING</b>	Converts sugars into glycogen and makes amino acids.
<b>GLUCOSE REGULATION</b>	Maintains the level of glucose in the blood.
<b>DETOXIFICATION</b>	Removes harmful substances such as alcohol from the blood.
<b>PROTEIN SYNTHESIS</b>	Makes blood-clotting proteins and proteins for blood plasma.
<b>MINERAL AND VITAMIN STORAGE</b>	Stores iron, copper, and vitamins.
<b>BLOOD WASTE DISPOSAL</b>	Eliminates bacteria and general foreign particles.
<b>RECYCLING BLOOD CELLS</b>	Breaks down red blood cells and reuses their constituents.

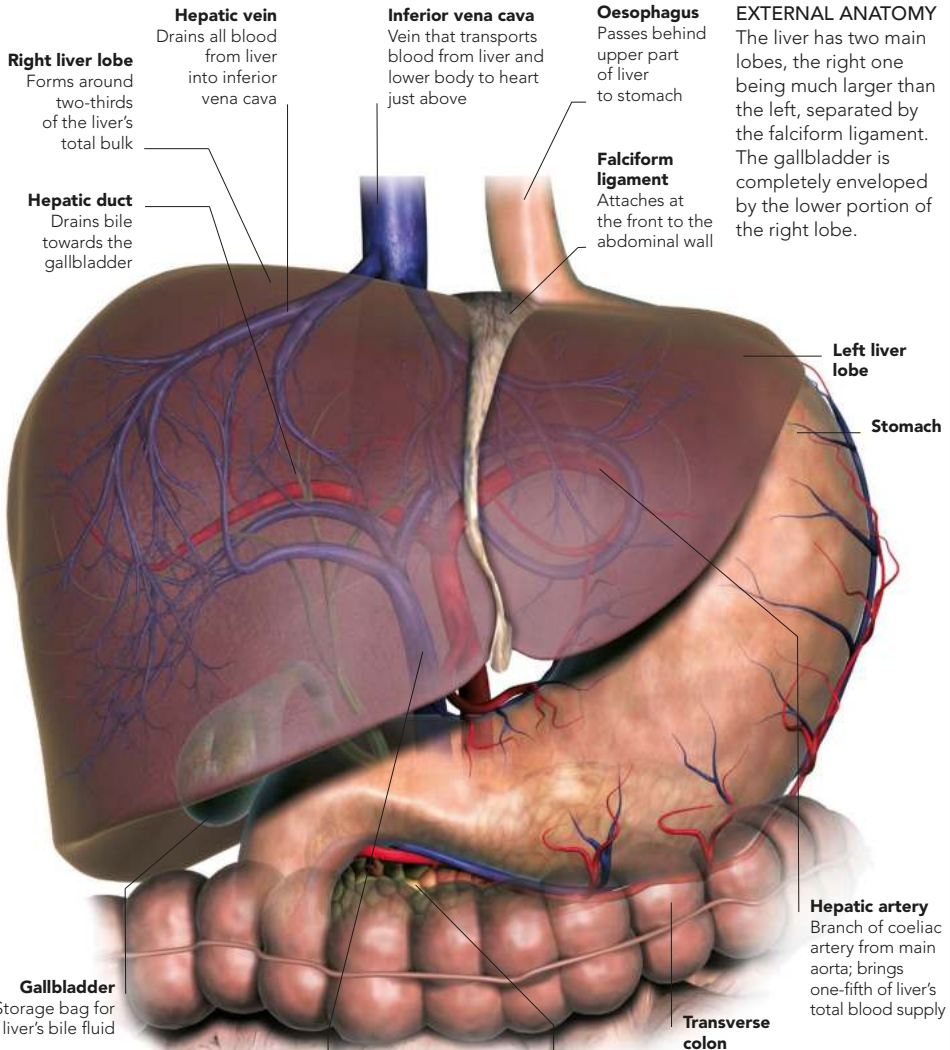
## LIVER LOBULES

The six-sided lobules of the liver nestle together, each supplied with a central vein and blood vessels and bile-collecting vessels around them.



## INSIDE A LOBULE

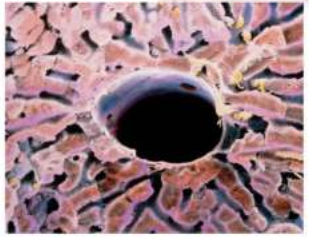
Hepatocytes filter the incoming, nutrient-rich blood into constituents that are destined for the bile ducts, storage, or waste disposal.



**Hepatic portal vein**  
Supplies blood from intestinal tract to liver

**Pancreas**  
Hidden behind lower stomach and transverse colon

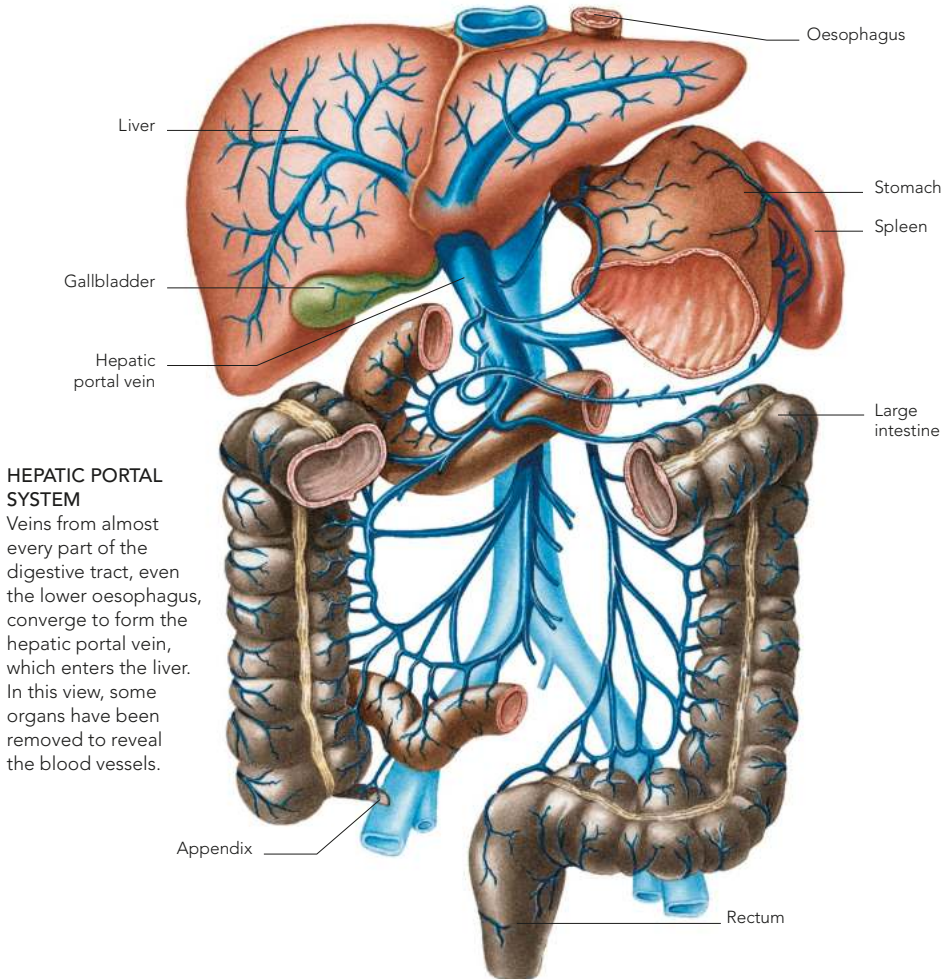
**LIVER ARCHITECTURE**  
In this electron micrograph at a magnification of around 300 times, sheets of hepatocytes can be seen radiating from the central canal. This canal contains the central vein.



## THE HEPATIC PORTAL CIRCULATION

The liver receives two blood supplies. The hepatic artery delivers oxygen-rich blood to the liver. In addition, the hepatic portal vein supplies the liver with the oxygen-poor, nutrient-rich blood that comes from the digestive tract, before this blood returns to the heart and is pumped throughout the body. This hepatic portal circulation enables the liver to stop toxins absorbed in the intestines from reaching the rest of the body. It also

helps to regulate the levels of many other substances in the bloodstream. Veins from several organs, including the intestines, pancreas, stomach, and spleen, drain into the hepatic portal vein. It is around 8cm (3in) long and supplies up to four-fifths of the blood into the liver. The flow-rate increases after a meal, but falls during physical activity as blood is diverted from the abdominal organs to skeletal muscles.



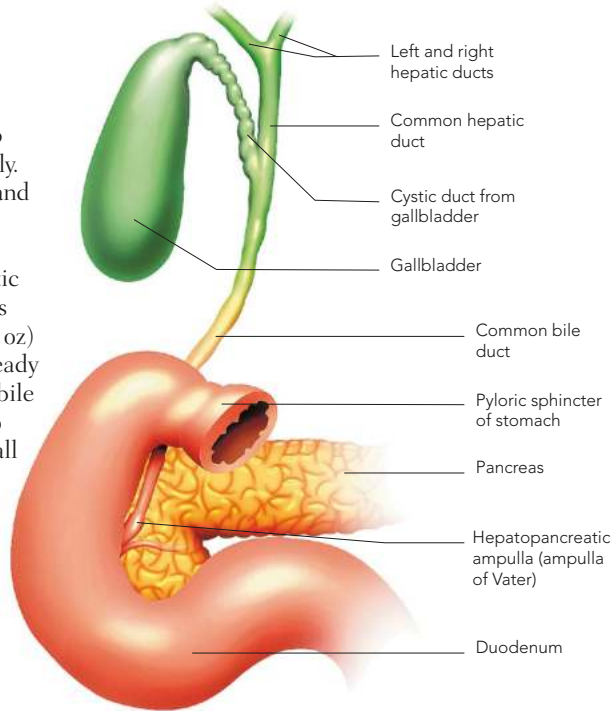
### HEPATIC PORTAL SYSTEM

Veins from almost every part of the digestive tract, even the lower oesophagus, converge to form the hepatic portal vein, which enters the liver. In this view, some organs have been removed to reveal the blood vessels.



## BILE TRANSPORT

Bile assists the breakdown of fats (lipids) in the small intestine. The liver secretes up to 1 litre ( $1\frac{2}{3}$  pints) of bile daily. The bile passes along the left and right hepatic ducts from the liver's two lobes, then along the common hepatic and cystic ducts to the gallbladder. This sac holds around 50ml ( $1\frac{2}{3}$  fl oz) of bile and concentrates it, ready for release after a meal. The bile flows along the cystic duct to enter the first part of the small intestine, the duodenum.



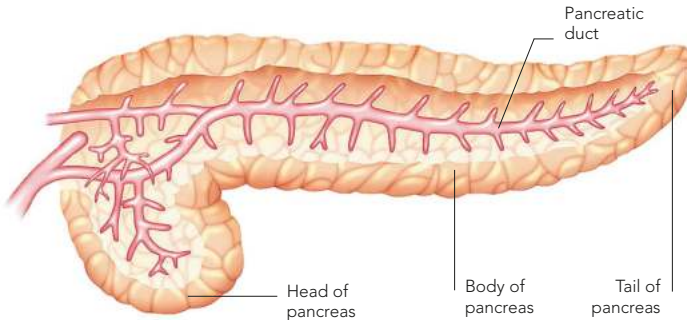
## DUAL DUCTS

The common bile duct joins the pancreatic duct at the hepatopancreatic ampulla, which empties into the duodenum.

## THE PANCREAS

The head end of this gland nestles in a loop of the duodenum, its main body lies behind the stomach, and its tapering tail sits above the left kidney, below the spleen. Each day, the pancreas produces around 1.5 litres ( $2\frac{2}{3}$  pints)

of digestive juice containing various enzymes that break down proteins, carbohydrates, and lipids. The fluid flows into the main and accessory pancreatic ducts, which empty the juices into the duodenum.



## PANCREATIC STRUCTURE

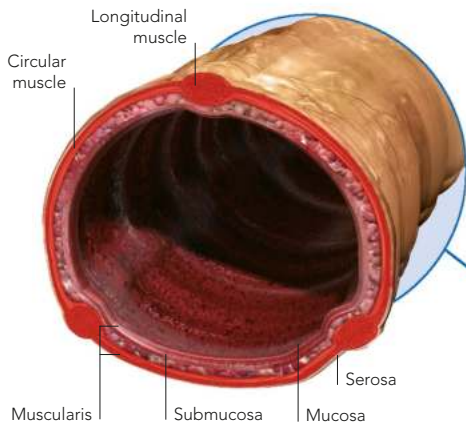
The pancreas is up to 15cm (6in) long, soft and flexible, and grey-pink in colour.

# LARGE INTESTINE

THE LARGE INTESTINE HAS THREE MAIN REGIONS – THE CAECUM, COLON, AND RECTUM. THE 1.5M (5FT)-LONG COLON CHANGES LIQUID DIGESTIVE WASTE PRODUCTS INTO A MORE SOLID FORM THAT IS EXCRETED AS FAECES.

## ROLE OF THE COLON

Once the chemical breakdown of food in the small intestine (see pp.218–19) is complete, almost all the nutrients vital for bodily functions will have been absorbed. The waste product from this process is partially digested, liquefied food (chyme). This passes from the small intestine, through the ileocaecal valve, into the caecum. From there, it reaches the first part of the colon, the ascending colon. The colon's main function is to convert the liquid chyme into semi-solid faeces for storage and disposal. Sodium, chloride, and water are absorbed through the lining of the colon into blood and lymph, and the faeces become less watery. The colon secretes bicarbonate and potassium in exchange for sodium and chloride. There are also billions of symbiotic or “friendly” microorganisms within the colon.



## LAYERS OF THE COLON WALL

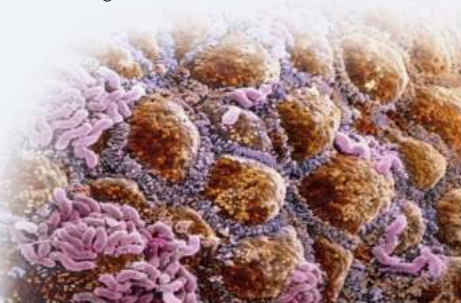
Inside the outer coating (serosa), smooth muscle fibres are responsible for colonic movements. The submucosa has many lymphoid nodules, and the mucosa produces lubricating mucus.

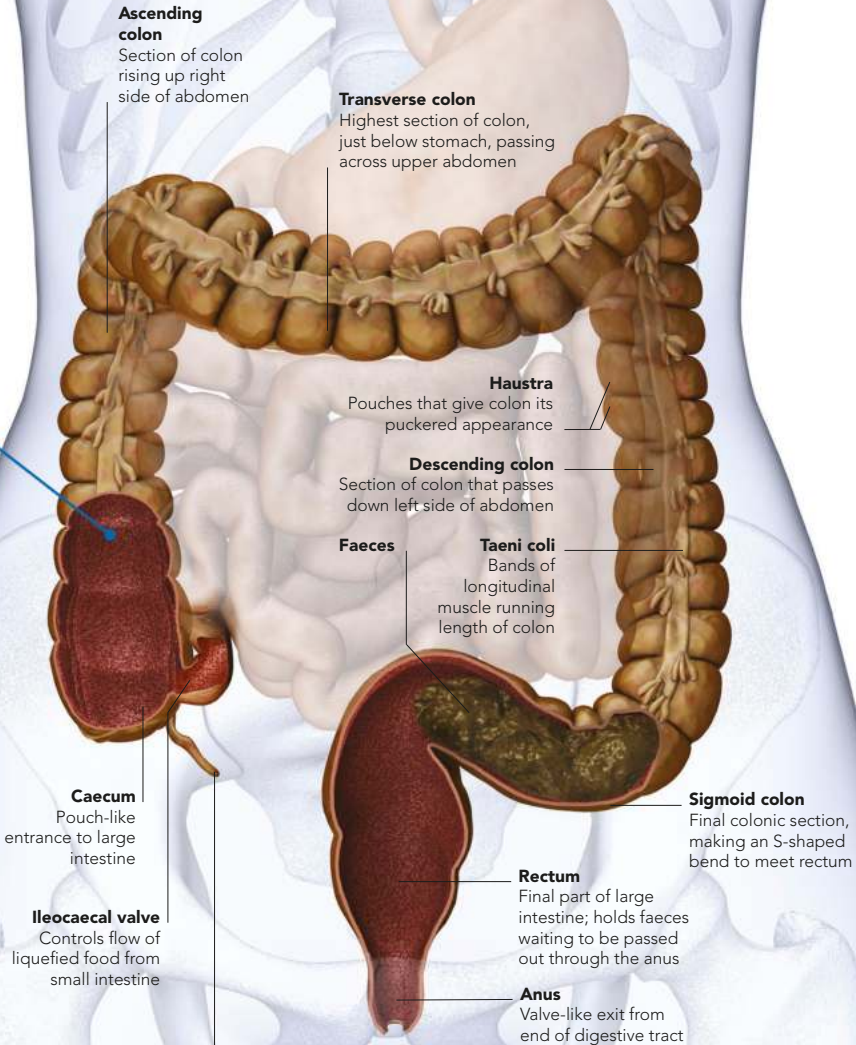
## GUT FLORA

Trillions of microorganisms, mainly bacteria, live in the intestinal tract – chiefly in the large intestine. They are known as the gut flora (or gut microbiota) and have a vital role in human health and disease. They produce enzymes that break down certain food components, such as cellulose, which human enzymes cannot digest. The gut flora also produce vitamins K and B, and hydrogen, carbon dioxide, hydrogen sulphide, and methane. They help to control harmful microbes in the digestive system and promote the formation of antibodies and the activity of lymphoid tissue in the colonic lining. Overall, the gut flora and the body exist in a mutually beneficial partnership (symbiosis). At least one-third of the weight of excreted faeces is composed of these bacteria.

## BACTERIA IN THE COLON

This electron microscope image (magnified over 2,000 times) shows clusters of rod-like bacteria (purple) on the lining of the colon.





#### PARTS OF THE COLON

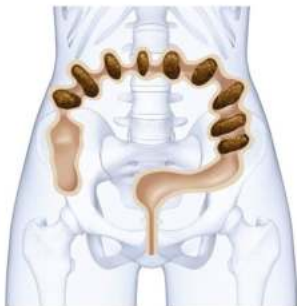The three sections of the colon form an almost rectangular “frame”, with the small intestine inside, the stomach and liver above, and the rectum below.

## COLONIC MOVEMENT

The colon has three bands of muscle called taenia coli, which form pouches called haustra (see p.225). Muscular movements mix and propel faeces towards the rectum. The motion of faeces varies in rate, intensity, and nature, depending mainly on the stage of digestion of the contents. The three main types of motion are known as segmentation, peristaltic contractions, and mass movements. Faecal material passes more slowly through the colon than through the small intestine, enabling the reabsorption into the blood of up to 2 litres ( $4\frac{1}{4}$  pints) of water every day.

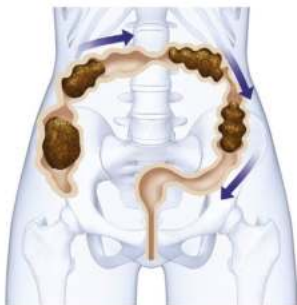
### SEGMENTATION

A series of ring-like contractions occurs at regular intervals. These churn and mix faeces but do not propel them along the colon.



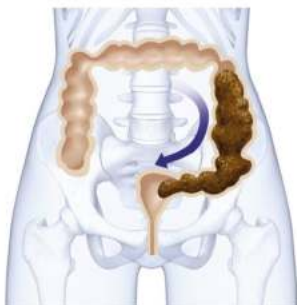### PERISTALTIC CONTRACTIONS

Small waves of movement called peristaltic contractions (see p.218) propel faeces toward the rectum. The muscles behind the contents contract, while those in front relax.



### MASS MOVEMENTS

These extra-strong peristaltic waves move from the middle of the transverse colon. They happen two or three times a day and drive faeces into the rectum.



Ascending  
colon

Caecum

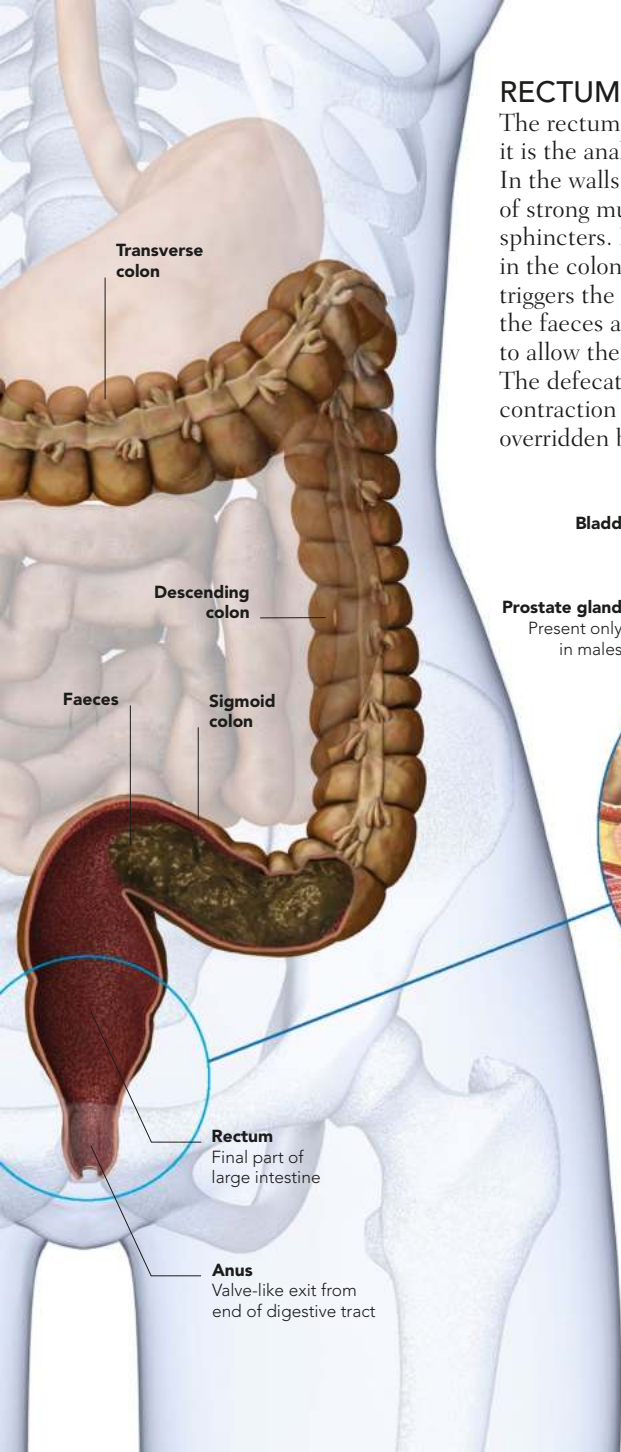
Appendix

### THE RECTUM

The rectum is a passageway for faeces and is normally empty, except just before and during defecation.

## RECTUM, ANUS, AND DEFECTION

The rectum is around 12cm (5in) long. Below it is the anal canal, about 4cm (1½in) long. In the walls of the anal canal, there are two sets of strong muscles – the internal and external sphincters. During defecation, peristaltic waves in the colon push faeces into the rectum, which triggers the defecation reflex. Contractions push the faeces along, and the anal sphincters relax to allow them out of the body through the anus. The defecation reflex may be aided by voluntary contraction of the abdominal muscles, or overridden by conscious control.



**Transverse colon**

**Descending colon**

**Faeces**

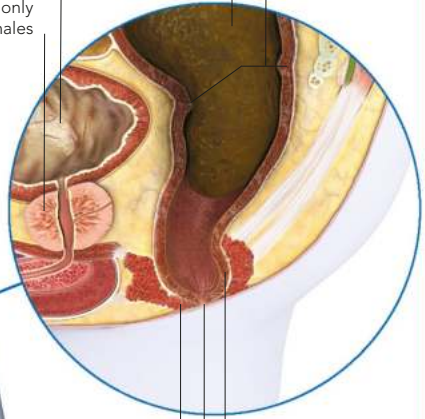
**Sigmoid colon**

**Rectum**  
Final part of large intestine

**Anus**  
Valve-like exit from end of digestive tract

**Bladder**

**Prostate gland**  
Present only in males



**External anal sphincter**  
Composed of skeletal (striped) muscle; mainly voluntary

**Internal anal sphincter**  
Composed of smooth muscle; mainly involuntary

**Anal canal**  
Lined by 5–10 longitudinal inner ridges (anal columns)

**Rectum**  
Wide passageway at the end of the colon

**Plicae transversales**  
Shelves of tissue in wall of rectum

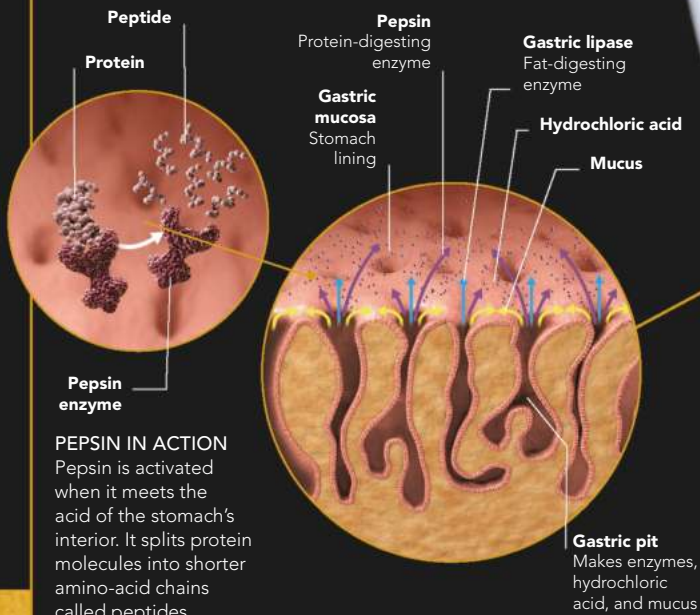
# DIGESTION

THE DIGESTIVE PROCESS INVOLVES A SERIES OF PHYSICAL AND CHEMICAL ACTIONS THAT BREAK DOWN FOOD INTO NUTRIENT PARTICLES SMALL ENOUGH FOR ABSORPTION.

Vigorous physical digestion of food – mashing and churning – starts in the mouth and continues in the stomach using muscular movement. The stomach and the mouth secrete digestive chemicals (enzymes), too. By the time the pulverized food and enzymes (chyme) reach the duodenum, many food particles are already microscopically small, yet not small enough to pass across cell membranes into the body tissues. Chemical digestion in the small intestine splits large molecules into even smaller, absorbable particles that can enter the blood.

## 1 IN THE STOMACH

The stomach lining has gastric pits that make various substances: hydrochloric acid to kill microbes in swallowed food; the enzyme gastric lipase to begin breaking down fat; mucus to protect the stomach from digestive enzymes and acid; and pepsin to digest proteins. Pepsin on its own could digest the stomach wall, so it is first released in an inactive form (pepsinogen), then activated by the stomach's acid.

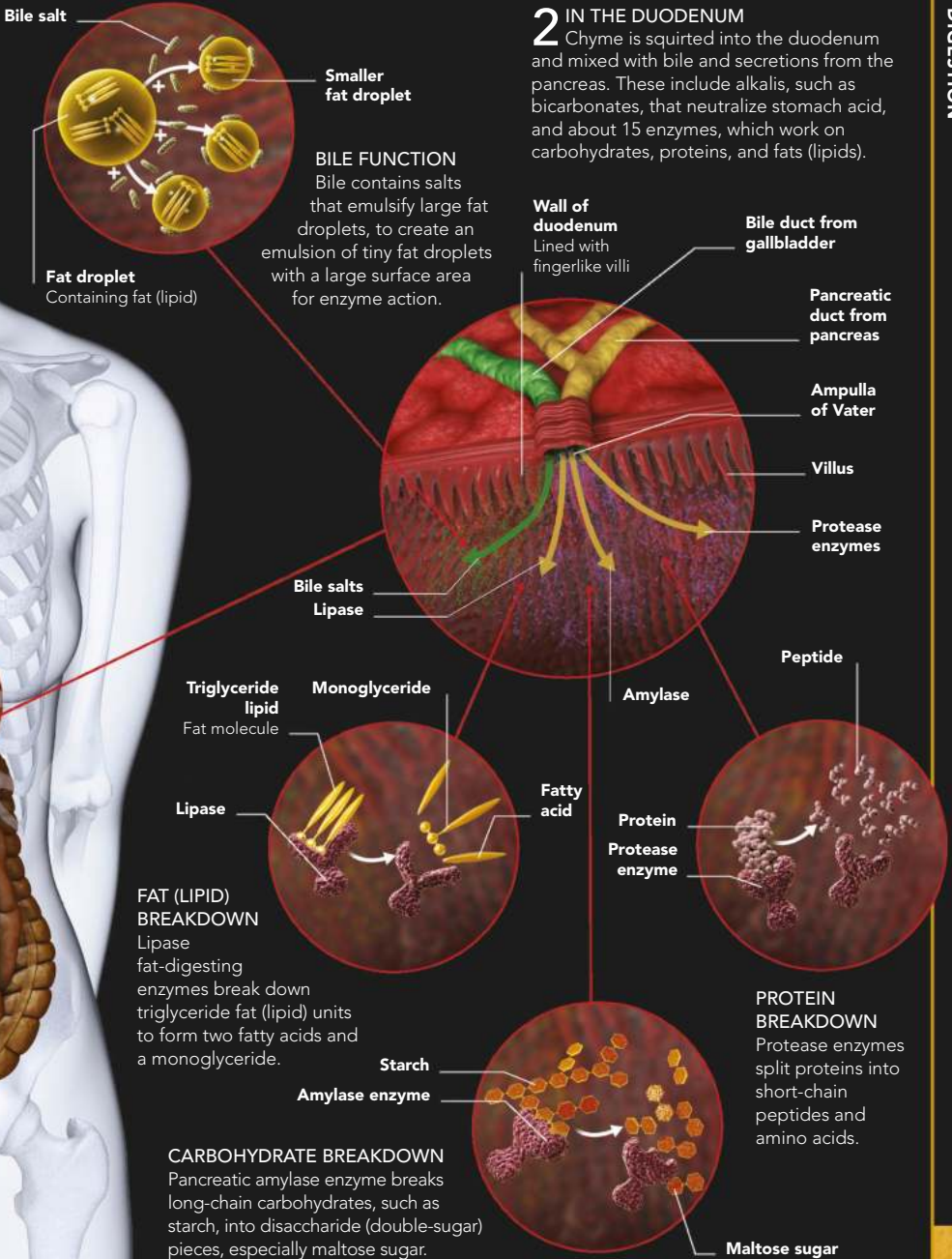


## DIGESTIVE JOURNEY

As it travels from the mouth to the small intestine, food is broken down into smaller and smaller particles.

## 2 IN THE DUODENUM

Chyme is squirted into the duodenum and mixed with bile and secretions from the pancreas. These include alkalis, such as bicarbonates, that neutralize stomach acid, and about 15 enzymes, which work on carbohydrates, proteins, and fats (lipids).



### 3 IN THE SMALL INTESTINE

After the duodenum, the remainder of the small intestine is the site for the final breakdown of food substances and their absorption into the blood and lymphatic fluids. The pancreatic juices and bile fluids continue to work, but the small intestine releases few further enzymes into its inner passage, the lumen. Instead, its enzymes act within the lining cells, and on their surfaces. These enzymes include lactase and maltase, which break down the double (disaccharide) sugars, lactose and maltose, into single-unit glucose and galactose. Intestinal peptidases convert short peptide chains (originally from proteins) into their subunits, amino acids. The fingerlike villi of the intestine lining have surface cells bearing smaller projections of their own (microvilli), where some of these final changes occur.

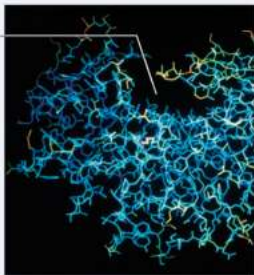
#### HOW ENZYMES WORK

An enzyme is a biological catalyst – a substance that boosts the rate of a biochemical reaction, but remains unchanged itself. Most enzymes are proteins. They affect the reactions of digestive breakdown, and also the chemical changes that release energy and build new materials for cells and tissues. Each enzyme has a specific shape due to the way its long chains of subunits (amino acids) fold and loop. The substance to be altered (the substrate) fits into a part of the enzyme known as the active site. In the case of digestion, the enzyme may undergo a slight change in 3-D configuration that encourages the substrate to break apart at specific bonds between its atoms.

Active site

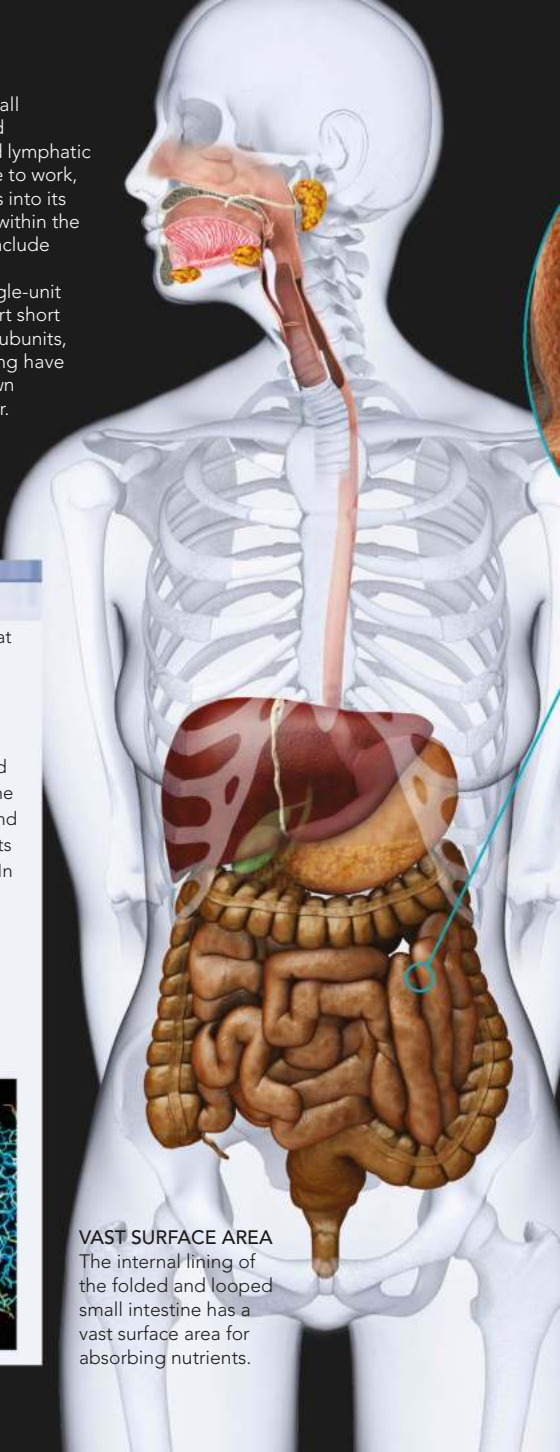
#### PEPSIN

A computer model of this digestive enzyme shows the active site as the gap at the top. A protein molecule will slot in here and break apart.

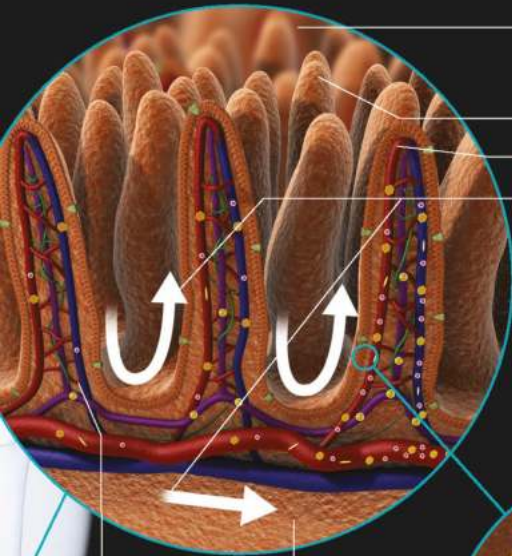


#### VAST SURFACE AREA

The internal lining of the folded and looped small intestine has a vast surface area for absorbing nutrients.







**Lumen**  
Fluid-filled space inside small intestine

**Villus**

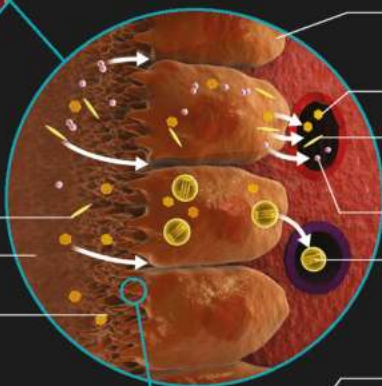
**Capillary of villus**

**Direction of blood flow**

**ABSORPTION ACROSS VILLI**  
The fingerlike villi (left) of the small intestine lining provide a large area for the absorption of the products of digestion. These substances are shown here accumulating in the bloodstream from left to right.

**Lacteal**  
Lymph capillary of villus

**Wall of small intestine**



**Epithelial (lining) cell of small intestine wall**

**Glucose**

**Short-chain fatty acid**

**Amino acid**

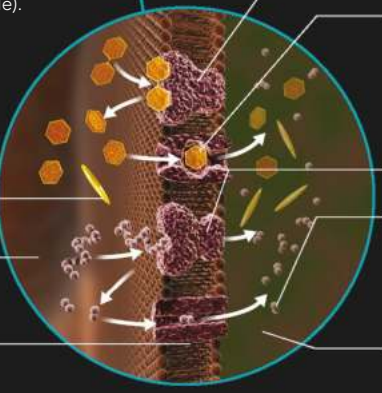
**Lipid package**

**Fatty acid**

**Small intestine lumen**

**Epithelial cell membrane**  
Formed into "brush" of microvilli

**CLOSE-UP OF VILLUS SURFACE**  
Short-chain fatty acids, glucose, and amino acids pass through the epithelial cells into a capillary (red). Larger fatty acids are packaged and passed into a lymph lacteal (purple).



**Maltase enzyme**  
Splits maltose into glucose

**Glucose**  
Passes through protein channel

**Peptidase enzyme**  
Splits peptides into amino acids

**Amino acids**  
Pass through protein channel in twos and threes

**Epithelial cell interior**

**EXTREME CLOSE-UP OF CELL MEMBRANE**  
Enzymes that complete digestion are embedded in the membrane of the epithelial cells (right). The resulting sugars and amino acids pass through dedicated protein channels, while fatty acids diffuse across.

**Short-chain fatty acid**  
Simply diffuses across cell membrane

**Small intestine lumen**

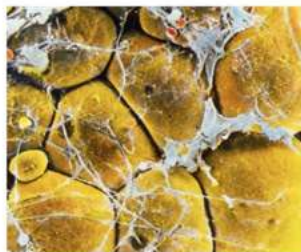**Epithelial cell membrane**

# NUTRIENTS AND METABOLISM

THE BODY'S INTERNAL BIOCHEMICAL REACTIONS, CHANGES, AND PROCESSES ARE TERMED METABOLISM. DIGESTION PROVIDES THE NUTRIENTS AS RAW MATERIALS, WHICH ENTER METABOLIC PATHWAYS IN ALL CELLS AND TISSUES.

## TAKING IN NUTRIENTS

Carbohydrates, fats, proteins, vitamins, minerals, and other nutrients are absorbed at different stages along the digestive tract. Blood from the major absorption sites of the intestines flows along the hepatic portal vein (see p.222) to the liver. Here, nutrients are broken down, stored, and released according to the body's needs.

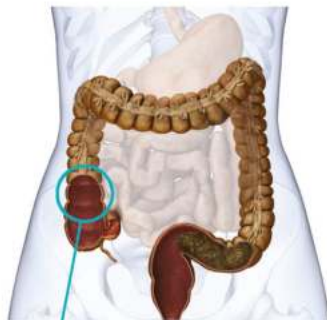

### FAT TISSUE

Adipose tissue consists of cells replete with fat droplets that can be used as a concentrated energy store in times of need.

## FINAL STAGES OF DIGESTION

The colon absorbs minerals, salts, and some vitamins, and reabsorbs a large amount of water, too. Fibre, such as pectin and cellulose, bulks up the digestive remnants as they are made into faeces. Fibre helps to delay the absorption of some molecules, including sugars, and so spreads their uptake through time rather than in one short "rush". In addition, fibre binds with some fatty substances, such as cholesterol, and helps to prevent their overabsorption.



### CAECUM

Each day about 100–500ml (3½–17fl oz) of digestive fluids, undigested leftovers, rubbed-off intestinal linings, and other matter enters the first chamber of the large intestine, the caecum.

#### Bicarbonate and potassium

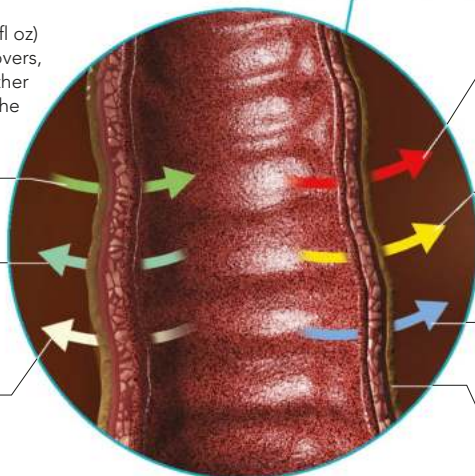
Secreted into lumen to replace recovered sodium

#### Chloride

Recovered from faeces; with sodium, it maintains acid-alkali balance in tissues

#### Sodium

Also recovered from faeces



#### Vitamin K

Manufactured by symbiotic bacteria

#### B vitamins

Some types released by bacterial fermentation

#### Water

Large intestine reabsorbs 2/3 of water in faeces

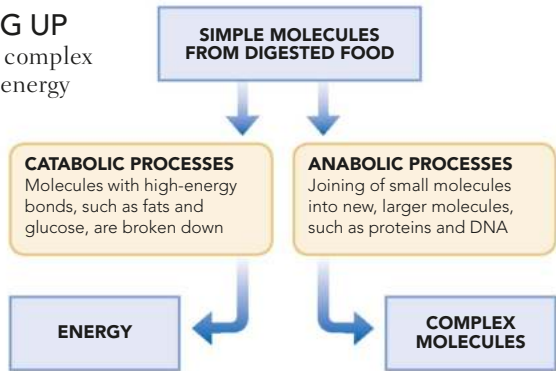
#### Colon

## BREAKDOWN AND BUILDING UP

Catabolism is the breaking down of complex molecules into simpler ones during energy production. Anabolism is the building up of complex molecules from simpler ones – for example, amino acids make peptide chains, which combine to form proteins.

### INTERPLAY

Metabolism is a complex interplay of construction and destruction, with many molecules being recycled as they pass between the two processes.



## HOW THE BODY USES FOOD

The three major food components yield different breakdown products.

Carbohydrates (starches and sugars) can be reduced to glucose; proteins to single amino acids; and fats (lipids) to fatty acids and glycerol. Glucose is the body's most adaptable and readiest source of energy.

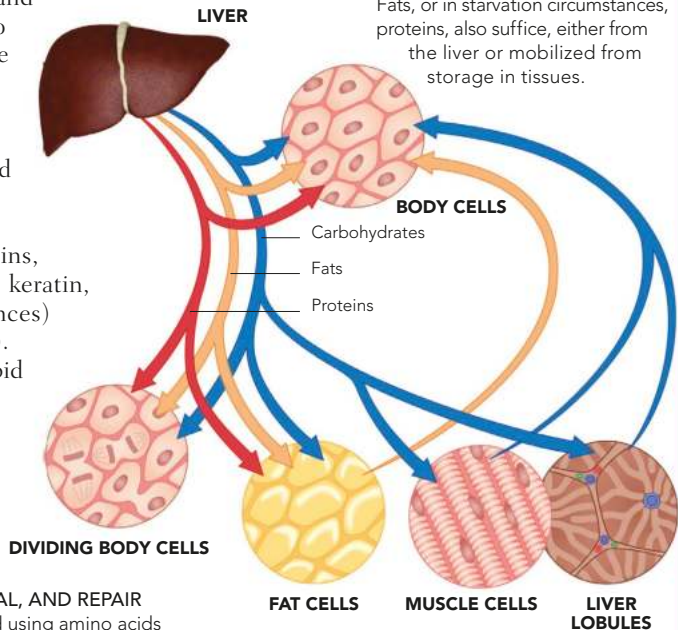
Amino acids are remade into the body's own proteins, both structural (collagen, keratin, and similar tough substances) and functional (enzymes).

Fatty acids form the bi-lipid membranes around and inside cells (see p.28).

However, the body can divert nutrients to different uses as conditions dictate.

### ENERGY PRODUCTION

The simple sugar glucose is the energy source used by all cells to power their life processes. Fats, or in starvation circumstances, proteins, also suffice, either from the liver or mobilized from storage in tissues.



### GROWTH, RENEWAL, AND REPAIR

Cells are maintained using amino acids to build up different protein structures, fats to form membranes, and glucose to provide the energy. Cells that are dividing for growth or repair require increased supplies of these nutrients.

### ENERGY STORAGE

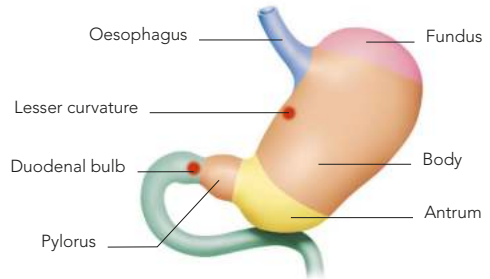
Surplus glucose is converted into glycogen, which is stockpiled in the liver and muscle cells. Fatty acids are a concentrated energy store, and they can be derived from dietary fats, excess amino acids, or glucose.

# DIGESTIVE TRACT DISORDERS

LIFESTYLE FACTORS, SUCH AS EXCESSIVE ALCOHOL CONSUMPTION, A POOR OR LOW-FIBRE DIET, AND FOOD SENSITIVITIES, CONTRIBUTE TO MANY DIGESTIVE TRACT DISORDERS, ALTHOUGH SOME PROBLEMS ARE RELATED TO BACTERIA OR TO A COMPROMISED IMMUNE SYSTEM.

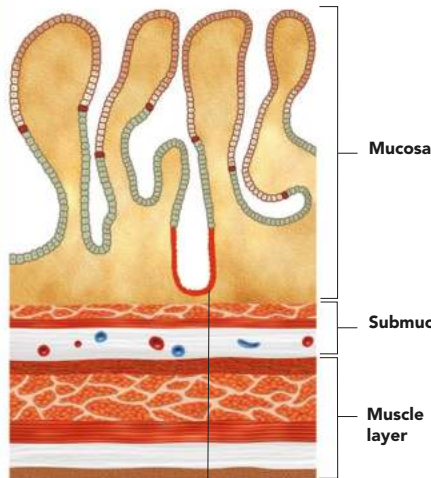
## PEPTIC ULCERS

Most peptic ulcers are associated with *Helicobacter pylori* bacteria. These damage the mucous lining that normally protects against the powerful acidic juices in the stomach and first part of the duodenum. Other contributory factors include alcohol consumption, smoking, certain medications, family history, and diet. Upper abdominal pain is a common symptom. With a duodenal ulcer, this is often worse before a meal and relieved by eating; in a gastric ulcer, eating tends to aggravate the pain.



### SITES OF PEPTIC ULCERS

A common site for ulcers is in the first part of the duodenum (duodenal bulb). In the stomach, most ulcers develop in the lesser curvature.

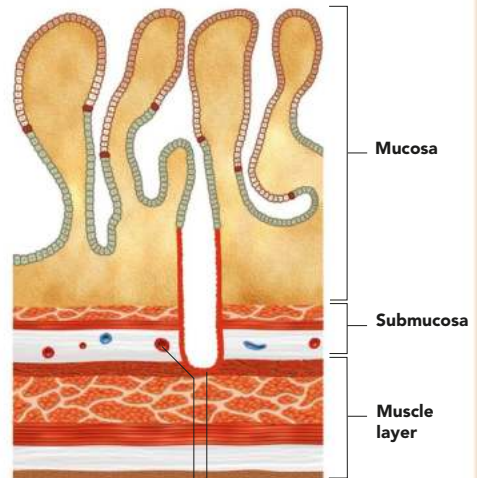


#### Erosion

In the early stages the lining is only partly destroyed, producing a shallow area of damage

#### EARLY ULCER

If the protective mucous barrier coating the stomach lining breaks down, gastric juices containing strong acid and enzymes come into contact with mucosal cells.



#### Blood vessel

Bleeding (haemorrhage) can result if a vessel is breached by a deepening ulcer

#### Deepening ulcer penetrates muscle layer

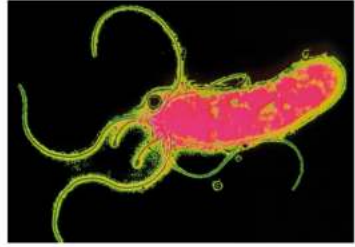
#### PROGRESSIVE ULCERATION

A true ulcer penetrates the entire lining (mucosal layer) as well as the submucosa and muscle layers. In severe cases, it can perforate the stomach or duodenal wall.

## GASTRITIS

Inflammation of the stomach lining, called gastritis, causes discomfort or pain, as well as nausea and vomiting. Gastritis that comes on suddenly, known as sudden onset (acute) gastritis, may be caused by over-indulging, especially in alcohol consumption, or by taking medications known for their effect on the stomach lining, such as aspirin. Chronic gastritis develops over the longer term and may be due to repeated insult to the lining by alcohol, tobacco, or drugs.

Another common cause is the bacterium *Helicobacter pylori*. Gastritis usually gets better with medication and by removing the underlying cause.



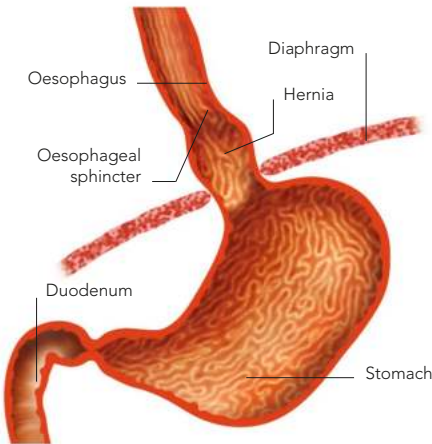
### COMMON CULPRIT

At least 50 per cent of people have *H. pylori* in their stomach lining. If the bacteria cause symptoms, antibiotics can eradicate them.

## HIATUS HERNIA

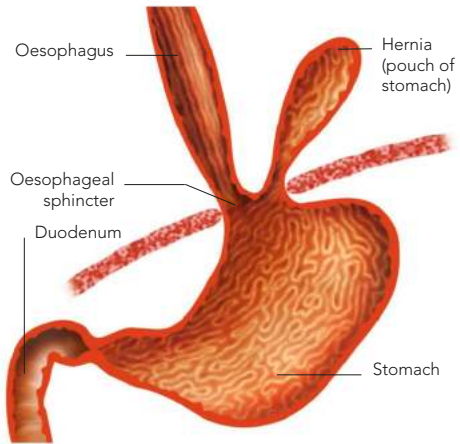
The oesophagus passes through a taut gap (hiatus) in the muscular sheet of the diaphragm, which lies between the abdomen and the chest cavity. The hiatus helps the oesophageal sphincter (ring of muscle at the lower end of the oesophagus) to prevent acidic stomach contents from passing up into the lower oesophagus. In a hiatus hernia, the upper section of the stomach protrudes up

through this gap. Any symptoms of a hiatus hernia are those of heartburn (gastric reflux). There are two types of hiatus hernia: sliding and para-oesophageal. Sliding hernias usually have no symptoms, and it is estimated that they are present in around a third of all people over 50. In rare cases, however, para-oesophageal hernias can cause severe pain and require surgery.



### SLIDING HIATUS HERNIA

This is the most common type of hiatus hernia, and occurs when the junction between the oesophagus and the stomach slides up through the diaphragm.



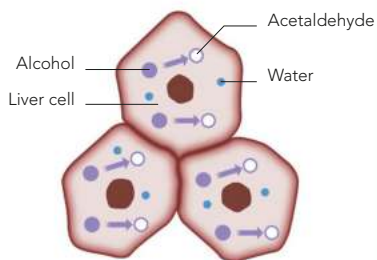
### PARA-OESOPHAGEAL HIATUS HERNIA

In about 1 in 10 hernias, a pouch-like part of the stomach is pushed upward through the diaphragm and lies adjacent to the lower oesophagus.

## ALCOHOLIC LIVER DISEASE

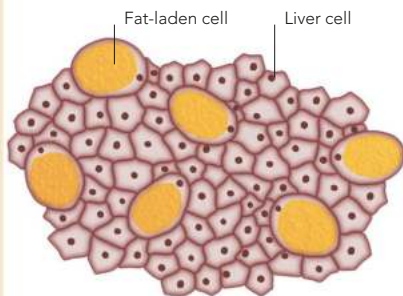
Regular, excessive alcohol consumption over many years can lead to serious liver damage. Women do not metabolize alcohol as efficiently as men and are more vulnerable to its side effects. The toxic effects of chemicals in alcohol can damage the liver in different ways and may, in some people, increase the risk of liver cancer. Almost all long-term, heavy drinkers develop a “fatty liver” because alcohol produces fat when it is broken down. If a person stops drinking, the fat disappears and the liver may eventually return to normal. However, continued heavy drinking can lead to alcoholic hepatitis, or inflammation of the liver. Symptoms vary from none at all to acute illness and jaundice. The final stage of

alcoholic liver damage is cirrhosis, which can be fatal. Often, the only treatment option at this stage is a liver transplant.



### 1 HOW DAMAGE OCCURS

Alcohol (ethanol) breaks down into acetaldehyde, which is thought to bind with proteins in liver cells and so may cause damage, inflammation, and fibrosis.

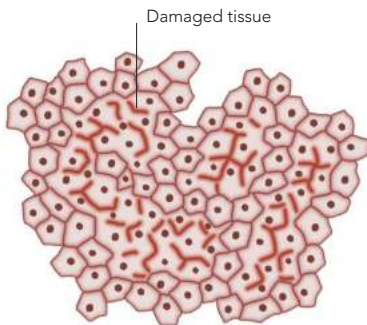
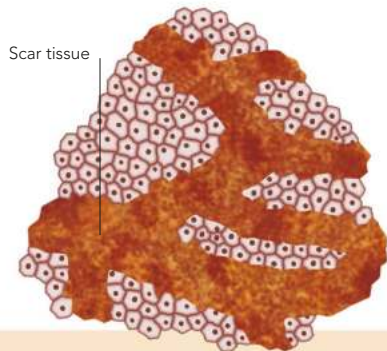


### 2 FATTY LIVER

One by-product of alcohol metabolism is fat. Liver cells in excessive drinkers swell with globules of fat that are clearly visible as yellow or white patches if the liver is cut open. The condition is reversible if drinking stops.

### 3 ALCOHOLIC HEPATITIS

Continued heavy drinking may cause fatty liver to develop into hepatitis. The liver becomes inflamed with many leucocytes. Liver cells may be severely damaged and die.



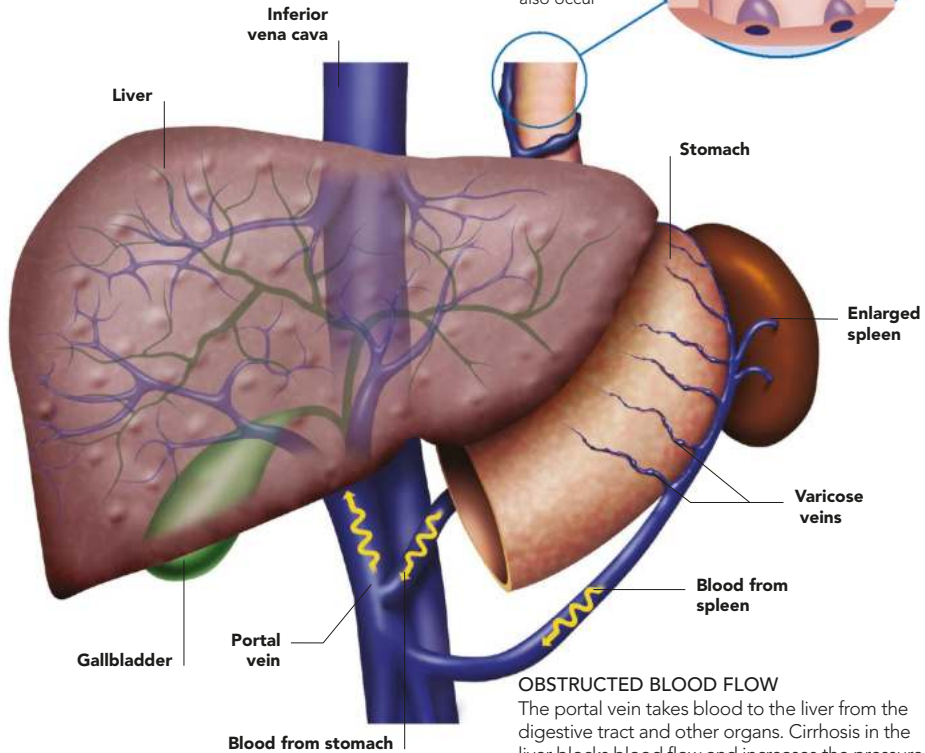
### 4 CIRRHOSIS

In this final stage of alcoholic liver disease, the permanent fibrosis and scarring of the liver tissue becomes life-threatening. As the cells are permanently damaged, the liver is unable to carry out its normal functions.

## PORTAL HYPERTENSION

One of the complications of liver cirrhosis is portal hypertension. As the tissue becomes progressively scarred and fibrosed, it obstructs the flow of blood into the liver from the portal vein, a large vessel carrying blood from the digestive tract. Pressure builds up in the vein, and can cause other vessels “upstream” to become distended. Among these are veins in the abdomen and rectum, and those that supply the oesophagus with blood. The swollen veins, or varices, protrude into the oesophagus and may bleed. In some cases, only slight oozing occurs. In others, a major haemorrhage causes massive vomiting of blood. Not everyone who has liver cirrhosis develops portal hypertension and

oesophageal varices. In those who do develop the condition, the varices can be treated with drugs to reduce the blood pressure or injected with a sclerosing (hardening) agent, much like that used to treat varicose veins.

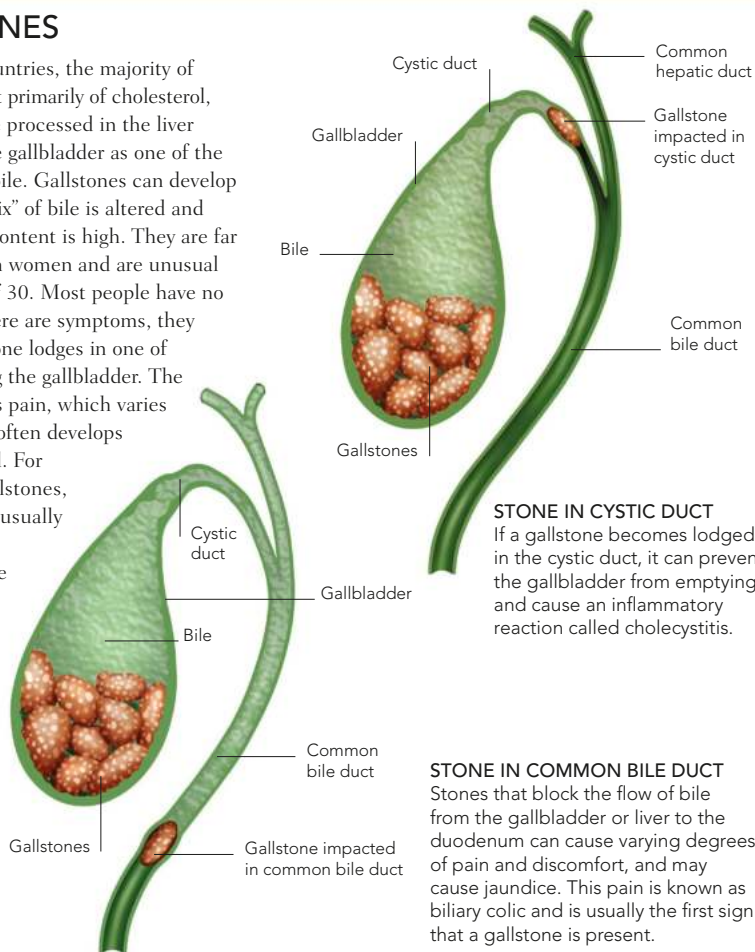


### OBSTRUCTED BLOOD FLOW

The portal vein takes blood to the liver from the digestive tract and other organs. Cirrhosis in the liver blocks blood flow and increases the pressure in the portal vein. Back pressure causes veins “upstream”, and in the oesophagus, to distend.

## GALLSTONES

In developed countries, the majority of gallstones consist primarily of cholesterol, a fatty substance processed in the liver and stored in the gallbladder as one of the constituents of bile. Gallstones can develop if the normal “mix” of bile is altered and the cholesterol content is high. They are far more common in women and are unusual before the age of 30. Most people have no symptoms. If there are symptoms, they begin when a stone lodges in one of the ducts leaving the gallbladder. The main symptom is pain, which varies in intensity and often develops after a fatty meal. For symptomatic gallstones, the treatment is usually cholecystectomy (often by keyhole surgery) to remove the gallbladder.



### STONE IN CYSTIC DUCT

If a gallstone becomes lodged in the cystic duct, it can prevent the gallbladder from emptying and cause an inflammatory reaction called cholecystitis.

### STONE IN COMMON BILE DUCT

Stones that block the flow of bile from the gallbladder or liver to the duodenum can cause varying degrees of pain and discomfort, and may cause jaundice. This pain is known as biliary colic and is usually the first sign that a gallstone is present.

## PANCREATITIS

Pancreatitis is a serious inflammation of the pancreas, and can be either acute or chronic. In both types, the inflammation is triggered by the enzymes that the pancreas itself normally manufactures to aid the digestion of food when it enters the duodenum. In pancreatitis, these enzymes become activated while they are still inside the pancreas, and begin to digest the tissue.

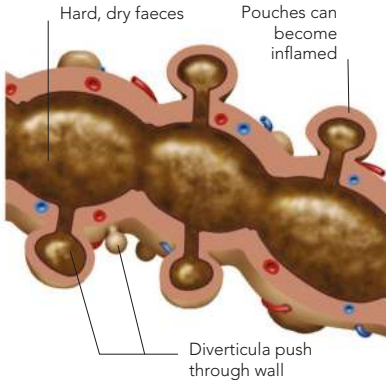
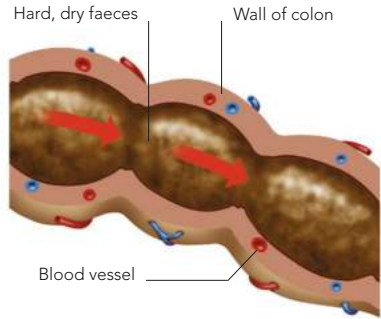
There are many causes of acute pancreatitis, the most common of which are gallstones (see above), excessive intake of alcohol, some drugs, and certain infections, such as mumps. Chronic pancreatitis is usually associated with long-term alcoholism. In both types, the main feature is pain. In acute pancreatitis, this is particularly severe and may be accompanied by nausea and vomiting.



## DIVERTICULAR DISEASE

In diverticular disease, patches of the colon wall bulge outward into pouches called diverticula. Most people with diverticular disease are aged over 50 and have eaten a low-fibre diet for many years, with consequent straining as they pass hard stools. The problem becomes more common with increasing age. The lowest part of the colon, known as the sigmoid colon (see p.227), is most commonly affected, but the whole of the colon can be involved. About 95 per cent of people with diverticular disease do not show symptoms, but some people have abdominal pain and irregular bowel habits. In diverticulitis, the pouches become inflamed, causing severe pain, fever, and constipation. The pain is often in the lower left abdomen, and may fade after passing gas or stools.

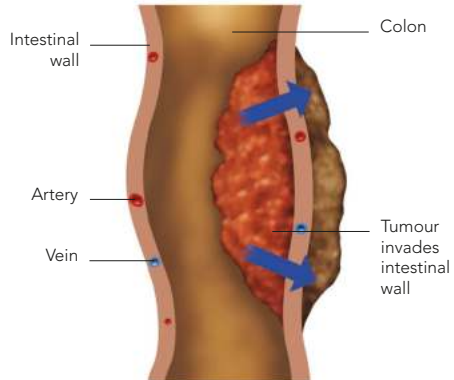
**1 HARD FAECES**  
Soft, bulky faeces are able to pass easily along the colon. If faeces are hard and dry, usually due to lack of fibre or "roughage" in the diet, the contractions of the smooth muscle layers of the colon must increase in force, putting pressure on the walls of the colon.



**2 POUCHES FORM**  
Eventually, the increased pressure pushes small areas of colon lining through points of weakness in the muscle of the wall, often near a blood vessel. The pea- to grape-sized pouches that form easily trap bacteria and may become inflamed.

## COLORECTAL CANCER

Cancer of the colon, rectum, or both, is one of the most common cancers in the industrialized world. Risk factors include family history and ageing. A malignant tumour in the intestinal wall can start as a polyp in the lining. A high-fat, low-fibre diet, excess alcohol, lack of exercise, and obesity can make this cancer more likely to develop. Symptoms are a change in bowel habits and stool consistency, abdominal pain, loss of appetite, faecal blood, and a sensation of not fully emptying the bowels. Colorectal cancer can be detected by screening programmes, such as faecal tests for blood and endoscopic examination (sigmoidoscopy). If it is detected and treated early, the chances of survival for five years or longer are high.



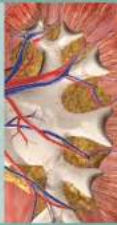### COLONIC TUMOUR

Over time, malignant tumours grow and invade the intestinal wall, from where the cancer can spread to other parts of the body via the bloodstream.



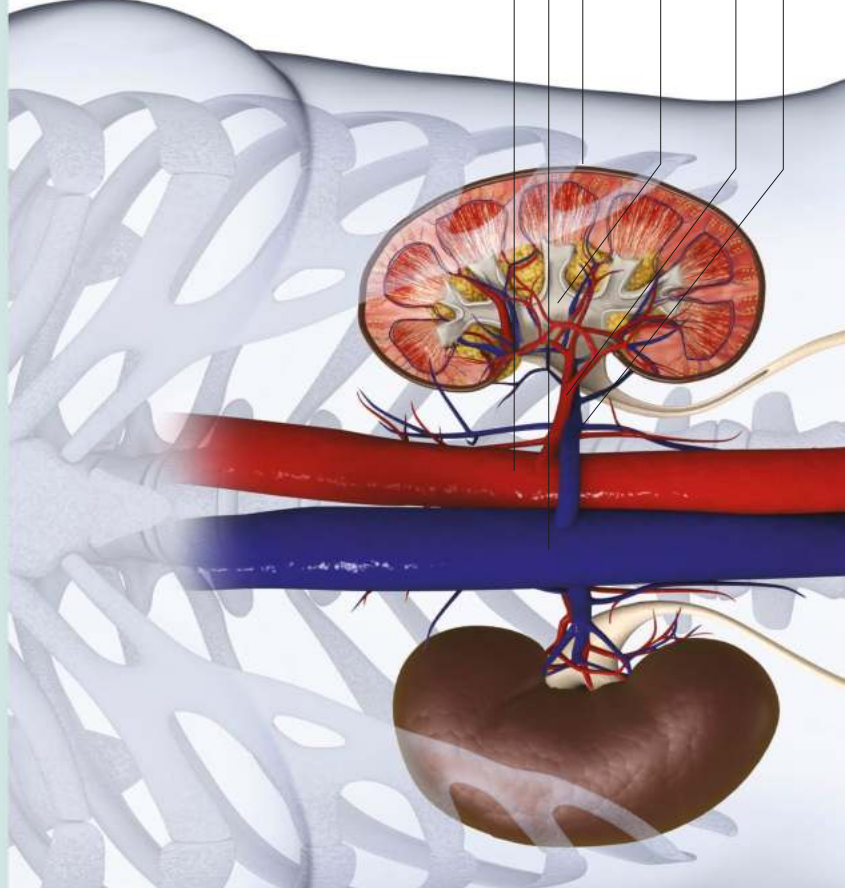
THOUSANDS OF METABOLIC PROCESSES IN MYRIAD BODY CELLS PRODUCE HUNDREDS OF WASTE PRODUCTS. THE URINARY SYSTEM REMOVES THEM BY FILTERING AND CLEANSING THE BLOOD AS IT PASSES THROUGH THE KIDNEYS. ANOTHER VITAL FUNCTION IS THE REGULATION OF THE VOLUME, ACIDITY, SALINITY, CONCENTRATION, AND CHEMICAL COMPOSITION OF BLOOD, LYMPH, AND OTHER BODY FLUIDS. UNDER HORMONAL CONTROL, THE KIDNEYS MONITOR WHAT THEY RELEASE INTO THE URINE TO MAINTAIN A HEALTHY CHEMICAL BALANCE.

# URINARY SYSTEM



## URINARY ANATOMY

THE URINARY SYSTEM IS COMPOSED OF TWO KIDNEYS, TWO URETERS, A BLADDER, AND A URETHRA. IT REGULATES THE VOLUME AND COMPOSITION OF BODY FLUIDS AND EXPELS WASTE AND EXCESS WATER FROM THE BODY.



The two kidneys are reddish organs resembling beans in shape. They are situated on either side of the abdomen, just above the waist and towards the back of the body. Each kidney contains many microscopic filtering units that remove unwanted waste, minerals, and excess water from the blood as urine. A ureter transports the urine to the bladder, which gradually becomes spherical, then pear-shaped, as it fills up. Eventually, stretch receptors in the bladder wall initiate a conscious desire to urinate. The urethra then conducts urine from the bladder to the outside.

**Aorta**

**Inferior vena cava**

**Kidney**

Each is about 10–12.5cm (4–5in) long, and contains about 1 million filtering units

**Renal pelvis**

Funnel-shaped chamber in which urine collects before passing down the ureter

**Renal artery**

**Renal vein**

**Ureters**

Vessels conveying urine from kidneys to bladder; a muscular layer in their walls contracts to propel urine to the bladder, and a mucosal layer secretes mucus to prevent its cells from coming into contact with urine

**Opening of ureter**

**Bladder lining**

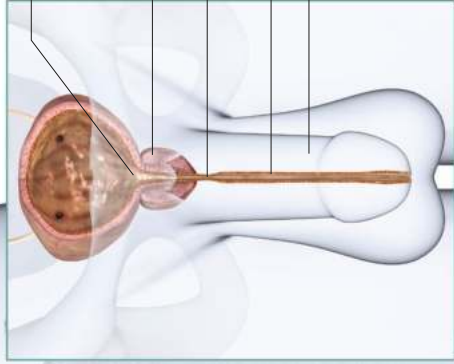
Secretes mucus to isolate body tissues from urine; contains many folds when bladder is empty; these smooth out as bladder fills

**Bladder wall**

Contains three indistinct layers of muscle fibre, jointly called the detrusor muscle

**Femoral artery**

**Urethra**



**Bladder outlet**

**Prostate gland**

Involved in semen production as part of the reproductive system; encircles the urethra

**Membranous part of urethra**

**Spongy part of urethra**

**Penis**

**MALE URETHRA**

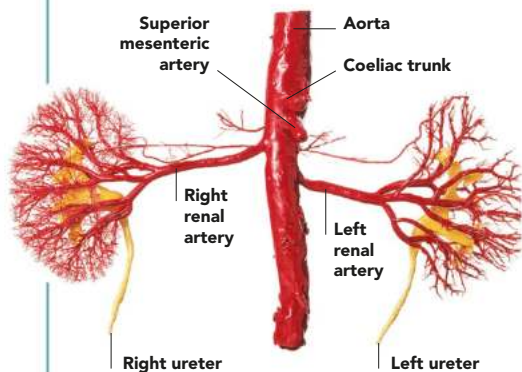
A male's urethra conveys both semen and urine along the length of the penis.

# KIDNEY STRUCTURE

THE KIDNEYS ARE A PAIR OF ORGANS SITUATED EITHER SIDE OF THE SPINAL COLUMN AND AT THE UPPER REAR OF THE ABDOMINAL CAVITY. THEY FILTER WASTE PRODUCTS FROM THE BLOOD AND EXCRETE THEM, ALONG WITH EXCESS WATER, AS URINE.

## INSIDE THE KIDNEY

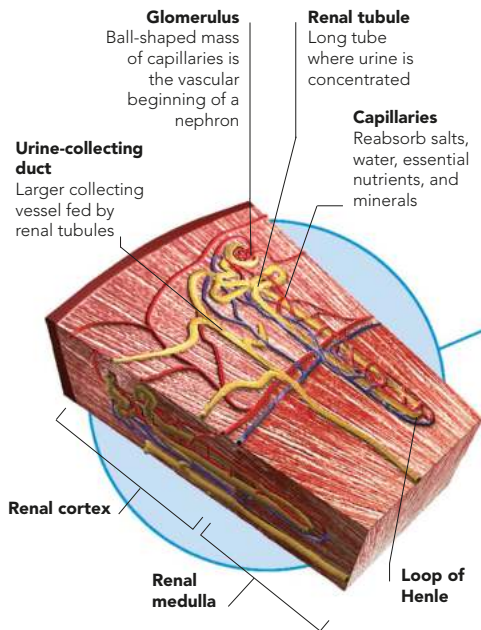
Each kidney is protected by three outer layers: a tough external coat of fibrous connective tissue, the renal fascia; a layer of fatty tissue, the adipose capsule; and inside this, another fibrous layer, the renal capsule. The main body of the kidney also has three layers: the renal cortex, which is packed full of knots of capillaries known as glomeruli and their capsules; next, the renal medulla, which contains capillaries and urine-forming tubules; and a central space where the urine collects, known as the renal pelvis. The glomeruli, capsules, and tubules are the constituent parts of the kidney's million-plus microfiltering units, called nephrons.



### BLOOD SUPPLY TO THE KIDNEYS

The left and right renal arteries are branches of the aorta, which carries blood directly from the heart. The arteries leave the coeliac trunk of the

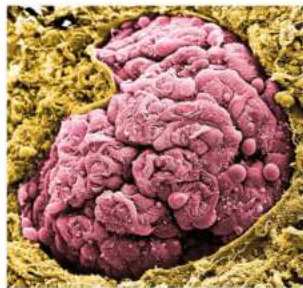
aorta just below the superior mesenteric artery. The renal arteries form a branching network that supplies blood to the kidneys.



### NEPHRON

Each microfiltering unit, or nephron, spans the cortex and medulla. The glomerulus, capsule, proximal and distal tubules, and the smaller

urine-collecting ducts are in the cortex. The medulla contains mainly the long tubule loops of Henle and the larger urine-collecting ducts.

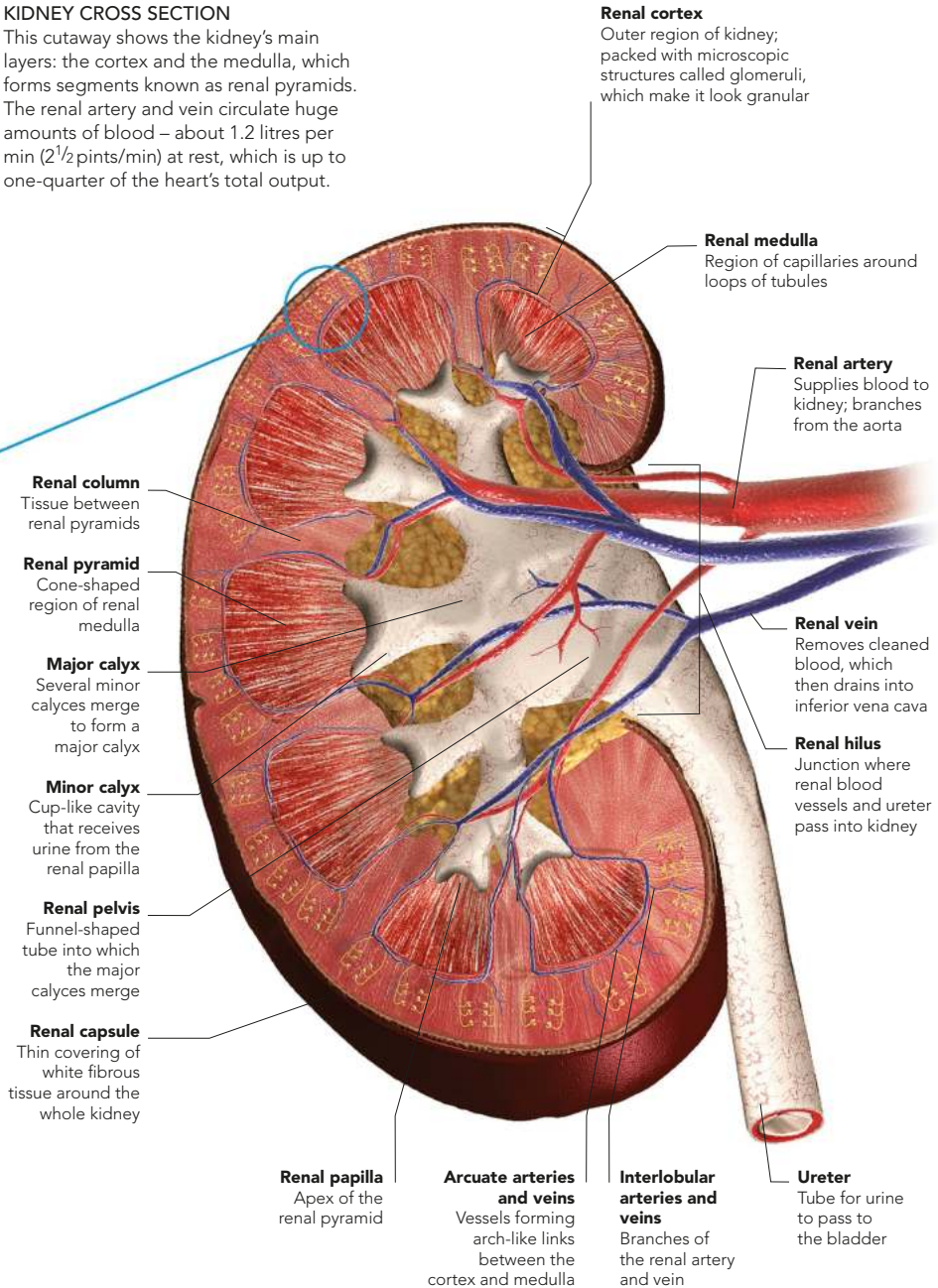


### GLOMERULUS

This microscope image shows the tangled system of a glomerulus (pink). A filtrate fluid oozes from the glomerulus and is collected by the cup-like Bowman's capsule (brown).

## KIDNEY CROSS SECTION

This cutaway shows the kidney's main layers: the cortex and the medulla, which forms segments known as renal pyramids. The renal artery and vein circulate huge amounts of blood – about 1.2 litres per min (2½ pints/min) at rest, which is up to one-quarter of the heart's total output.



### Renal cortex

Outer region of kidney; packed with microscopic structures called glomeruli, which make it look granular

### Renal medulla

Region of capillaries around loops of tubules

### Renal artery

Supplies blood to kidney; branches from the aorta

### Renal vein

Removes cleaned blood, which then drains into inferior vena cava

### Renal hilum

Junction where renal blood vessels and ureter pass into kidney

### Renal column

Tissue between renal pyramids

### Renal pyramid

Cone-shaped region of renal medulla

### Major calyx

Several minor calyces merge to form a major calyx

### Minor calyx

Cup-like cavity that receives urine from the renal papilla

### Renal pelvis

Funnel-shaped tube into which the major calyces merge

### Renal capsule

Thin covering of white fibrous tissue around the whole kidney

### Renal papilla

Apex of the renal pyramid

### Arcuate arteries and veins

Vessels forming arch-like links between the cortex and medulla

### Interlobular arteries and veins

Branches of the renal artery and vein

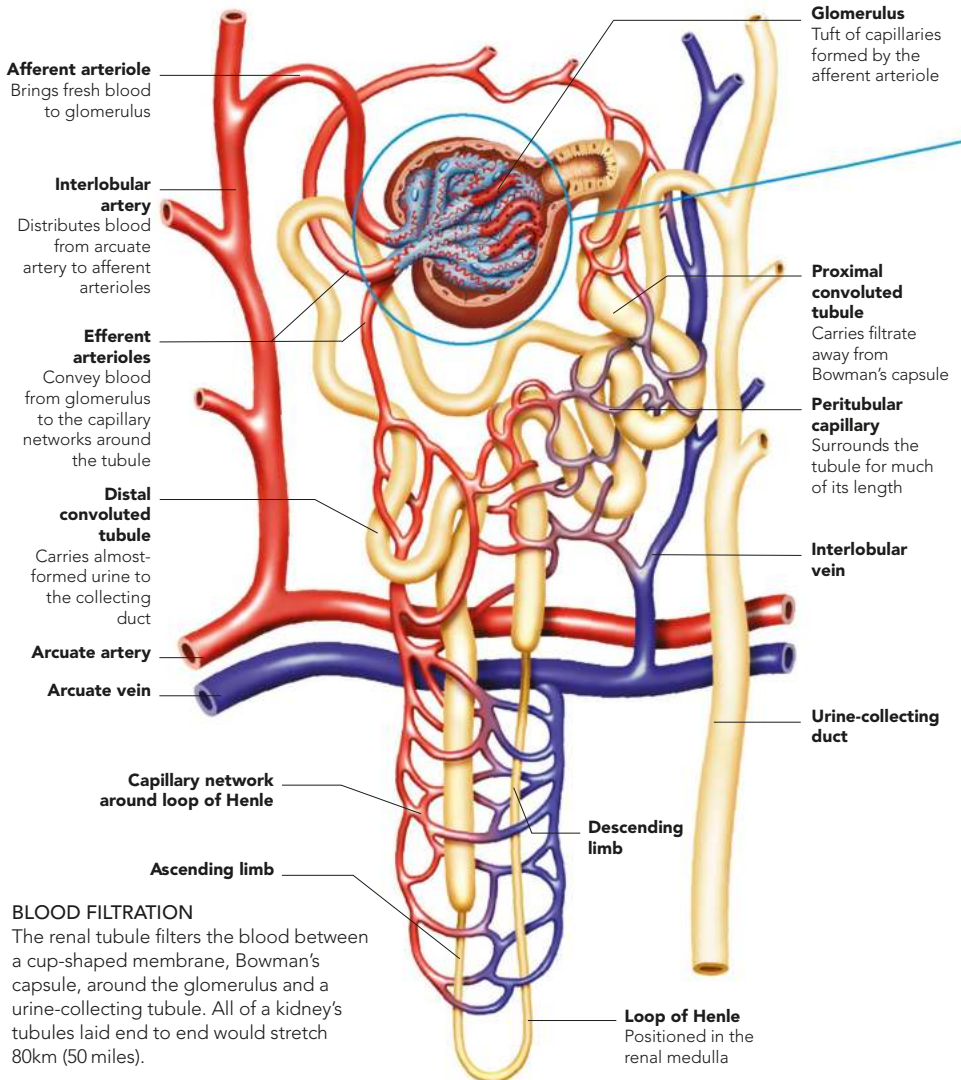
### Ureter

Tube for urine to pass to the bladder

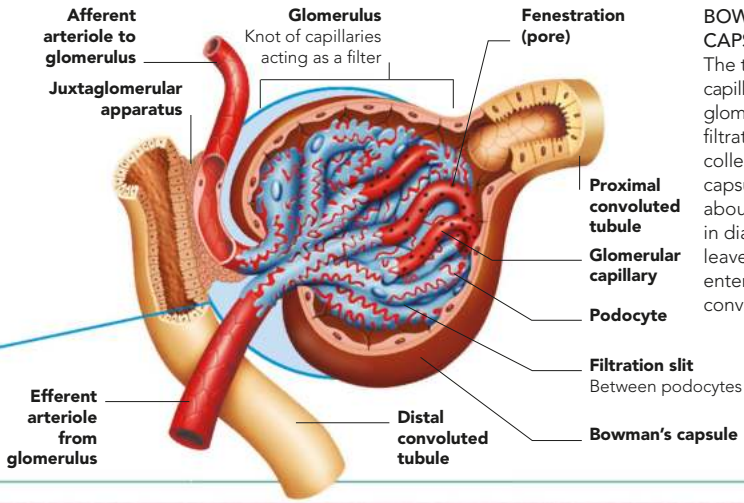
## STRUCTURE OF A NEPHRON

Each nephron consists of two tubes: one for carrying blood and one for forming urine. Both have convoluted routes between the renal cortex and medulla. The blood vessel starts as the afferent arteriole and finishes as a venule that carries the blood away. The

renal tube starts at Bowman's capsule around the glomerulus, and leads into the proximal convoluted tubule, which dips into and out of the medulla as the loop of Henle. Eventually, it feeds urine into a large urine-collecting duct.





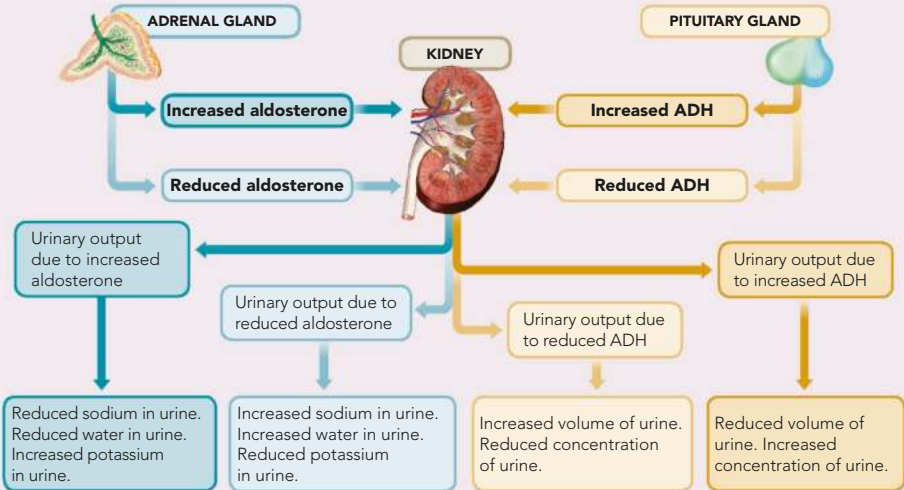


**BOWMAN'S CAPSULE**  
 The tangled system of capillaries forming the glomerulus oozes a filtrate fluid that is collected by Bowman's capsule. The capsule is about 0.2mm ( $1/125$  in) in diameter. The filtrate leaves the capsule and enters the proximal convoluted tubule.

## REGULATION OF URINE PRODUCTION

The amount, composition, and concentration of urine is determined principally by two hormones: ADH (antidiuretic hormone, or vasopressin) and aldosterone. ADH, released by the pituitary gland, acts on the kidneys to reduce urine volume and increase its concentration. Aldosterone, released by the adrenal glands, acts on the kidneys to reduce sodium and water in the urine and increase potassium.

**HORMONAL CONTROL**  
 Levels of the hormones ADH and aldosterone are altered so that the amounts of water, solutes, and wastes in urine are increased or decreased as needed to maintain a constant environment.



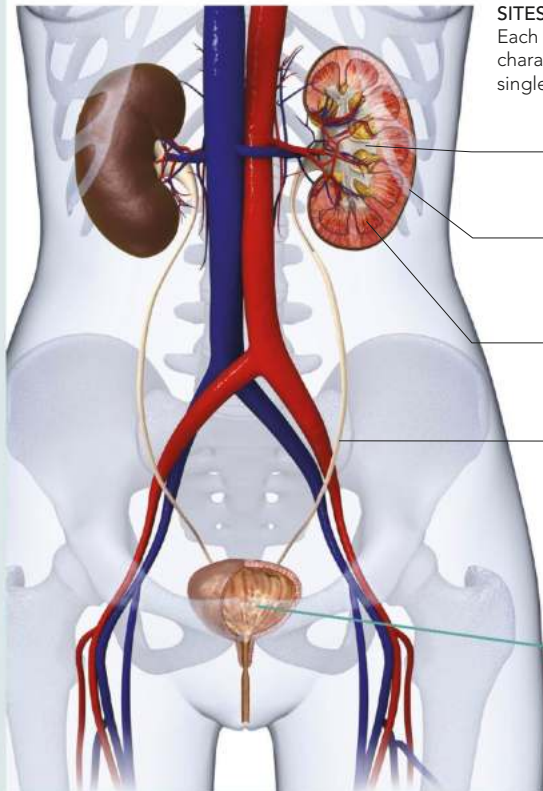
# URINARY DISORDERS

PARTS OF THE URINARY TRACT ARE SUSCEPTIBLE TO INFECTIONS, RESULTING IN CONDITIONS SUCH AS CYSTITIS. SOME CHRONIC KIDNEY DISEASES ARE ALSO CAUSED BY INFECTION. COMMON SYMPTOMS, SUCH AS INCONTINENCE, CAN BE VERY TROUBLESOME.

## URINARY TRACT INFECTIONS

The urine flowing through the urinary tract moves in one direction – from the kidneys through the ureters to the bladder, and then through the urethra to leave the body. During urination, the flow from the bladder is rapid and copious, but for long periods urine remains stagnant in the bladder. Infections can enter the body through the urethra and spread to the bladder, and sometimes up the ureters to the kidneys. The adult female urethra is 4cm (1½in)

long, compared to the male's at 20cm (8in). This short length and the proximity of its outlet to the anus (which means that bacteria from the anal area may enter the urethra) together account for females' greater susceptibility to urinary infection. One of the most common urinary infections is inflammation of the bladder, known as cystitis. The main symptoms of cystitis are burning pain and a frequent need to urinate, but often with little urine passed on each occasion.



### SITES OF DISORDERS

Each of the urinary organs is affected by its own characteristic diseases. However, a disorder of any single organ can affect other parts of the system.

#### Pyelonephritis

An acute infection of the urine-collecting system of the kidney

#### Diabetic nephropathy

Changes to capillaries in the kidneys, which may lead to kidney failure; caused by long-term diabetes mellitus

#### Glomerulonephritis

Inflammation of the filtering units of the kidney (glomeruli); often related to an autoimmune process

#### Reflux

Forcing of urine up the ureters by back pressure; can be caused by a blockage of the urethra

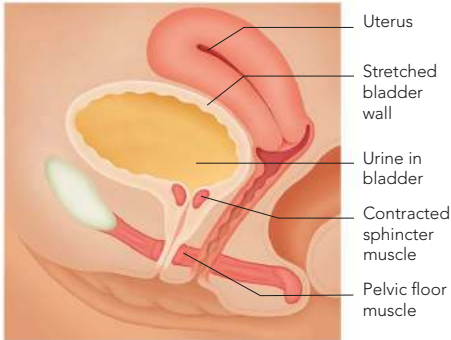
### CYSTITIS

This micrograph shows cystitis affecting a bladder lining. Bacteria (yellow rods) colonize the lining's inner surface (blue), causing inflammation.

## INCONTINENCE

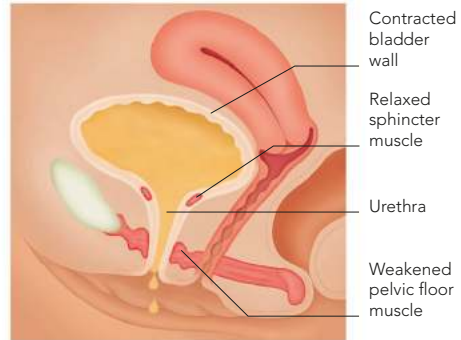
A tendency to leak urine, incontinence most commonly occurs in women, elderly people, and those with brain or spinal cord damage. Women after childbirth may be susceptible because their pelvic floor muscles may be weak. There are

different types, such as stress incontinence (see below). In urge incontinence, irritable bladder muscle causes the bladder to contract and expel all its urine. In total incontinence, a nervous system disorder such as multiple sclerosis causes total loss of bladder function.



### NORMAL BLADDER

A healthy bladder expands like a balloon as it fills with urine. The sphincter muscles and surrounding pelvic floor muscles keep the exit closed. Nerve signals from stretch sensors in the bladder wall travel to the brain, signalling the need for emptying.



### STRESS INCONTINENCE

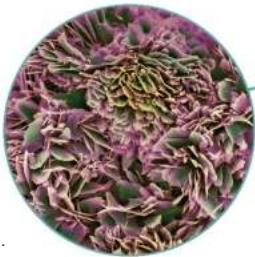To empty the bladder, the sphincter and pelvic floor muscles relax, and the detrusor muscle in the bladder wall contracts, forcing urine along the urethra. In incontinence, weak muscles may allow this to happen without proper control, so urine leaks out.

## KIDNEY STONES

Kidney stones are solid, mineral-rich objects formed from chemicals, such as calcium salts, in urine. They can take years to form, and grow in various shapes and sizes. A stone may stay in the kidney and cause few problems, but it can increase the risk of urinary tract infection.

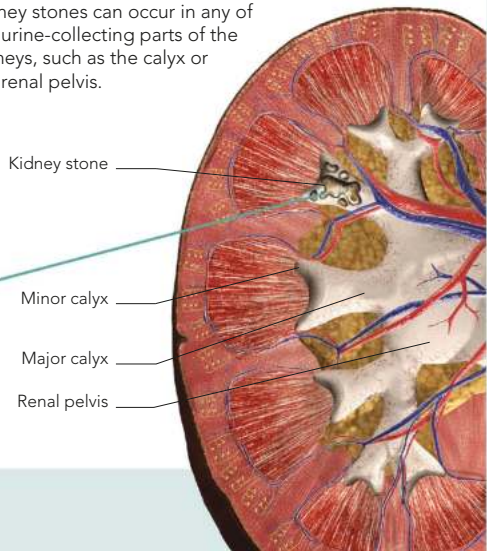
### CRYSTALS

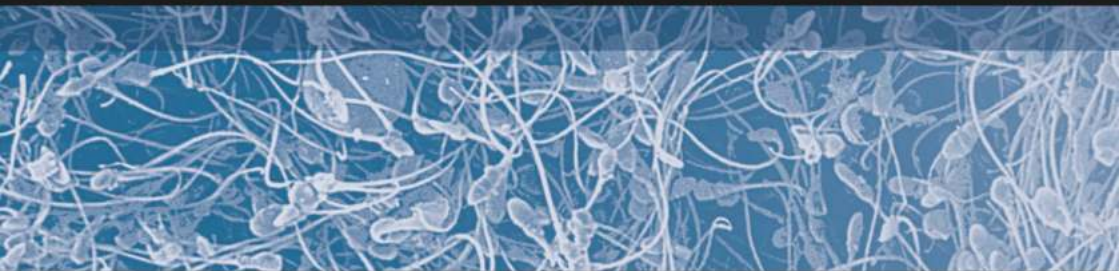Kidney stones are usually formed from the mineral salt calcium oxalate, when it crystallizes from the urine. Crystals of this salt are shown here.



### WHERE KIDNEY STONES FORM

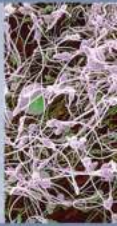
Kidney stones can occur in any of the urine-collecting parts of the kidneys, such as the calyx or the renal pelvis.





IN BIOLOGICAL TERMS, THE PRIMARY FUNCTION OF THE HUMAN BODY IS TO REPLICATE ITSELF, AND THE SEXUAL AND PARENTING INSTINCTS ARE AMONG THE STRONGEST OF OUR BASIC DRIVES. AS SCIENCE WIDENS THE GAP BETWEEN SEX AND REPRODUCTION, WE CAN NOW CHOOSE TO HAVE ONE WITHOUT THE OTHER. SEXUAL REPRODUCTION MEANS THAT WE INHERIT GENES FROM OUR PARENTS, WHICH INFLUENCE NOT ONLY OUR PHYSICAL CHARACTERISTICS BUT ALSO OUR SUSCEPTIBILITY TO PARTICULAR DISEASES.

# REPRODUCTION AND LIFE CYCLE

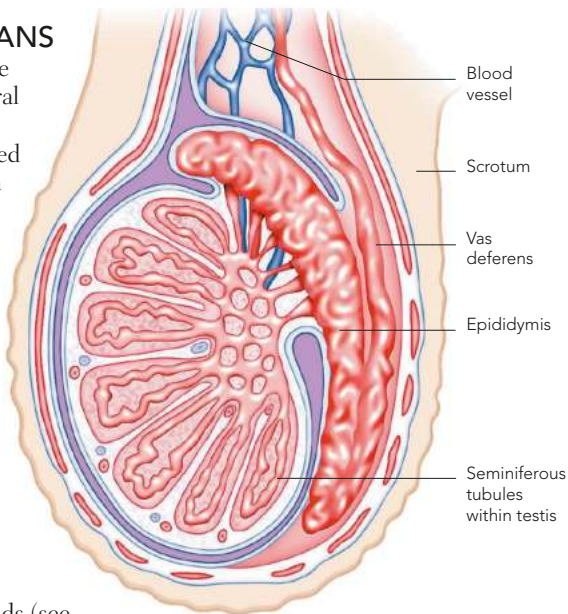


# MALE REPRODUCTIVE SYSTEM

THE MALE SYSTEM PRODUCES SEX CELLS (GAMETES) CALLED SPERM. UNLIKE FEMALE EGG MATURATION, WHICH OCCURS IN CYCLES AND CEASES AT MENOPAUSE, SPERM PRODUCTION IS CONTINUOUS, REDUCING GRADUALLY WITH AGE.

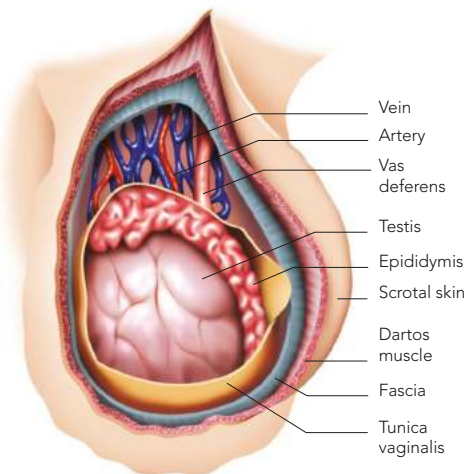
## THE REPRODUCTIVE ORGANS

The male reproductive organs include the penis, two testes (testicles), several storage and transport ducts, and supporting structures. The oval-shaped testes lie outside the body in a pouch of skin called the scrotum, where they maintain the optimum temperature for making sperm – approximately 3°C (5°F) lower than body temperature. Testes are glands responsible for making sperm and the sex hormone testosterone. From each testis, sperm pass into a coiled tube – the epididymis – for the final stages of maturation. They are stored in the epididymides until they are either broken down and reabsorbed, or ejaculated – forced by movement of seminal fluid from the accessory glands (see p.254) down a duct called the vas deferens.



### INSIDE THE SCROTUM

The scrotum contains two testes, where sperm are manufactured within tubes called seminiferous tubules, and the two epididymides, where sperm are stored. Each epididymis is a tube about 6m (20ft) long, which is tightly coiled and bunched into a length of just 4cm (2in).



### SCROTAL LAYERS

Each testis is covered by a thin tissue layer, the tunica vaginalis, and a layer of connective tissue called fascia. An outer layer called the dartos muscle relaxes in hot weather, dropping the testes to keep them cool, and draws them up in cold weather so they do not become too chilled. The spermatic cord suspends each testis within the scrotum: it contains the testicular artery and vein, lymph vessels, nerves, and the vas deferens.

**MALE REPRODUCTIVE ORGANS**

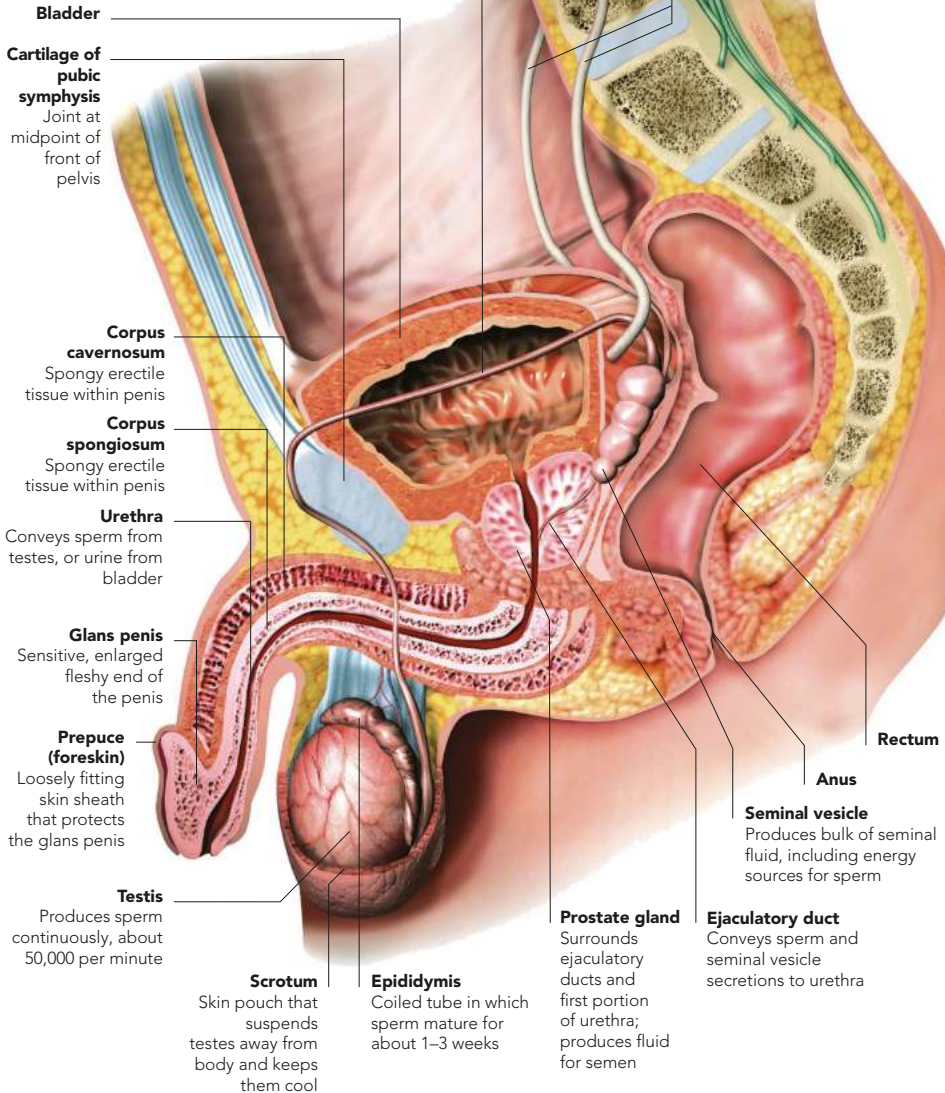
A midline section through the male lower body shows how the penis and scrotum hang outside the abdomen. Inside is a complex system of ducts, tubes, and glands where sperm mature and are stored before being ejaculated in semen.

**Vas deferens**

Thick-walled duct, with narrow central space (lumen) that carries sperm

**Ureters**

Carry urine from kidneys to bladder; part of the urinary system



**Bladder**

**Cartilage of pubic symphysis**

Joint at midpoint of front of pelvis

**Corpus cavernosum**

Spongy erectile tissue within penis

**Corpus spongiosum**

Spongy erectile tissue within penis

**Urethra**

Conveys sperm from testes, or urine from bladder

**Glans penis**

Sensitive, enlarged fleshy end of the penis

**Prepuce (foreskin)**

Loosely fitting skin sheath that protects the glans penis

**Testis**

Produces sperm continuously, about 50,000 per minute

**Scrotum**

Skin pouch that suspends testes away from body and keeps them cool

**Epididymis**

Coiled tube in which sperm mature for about 1-3 weeks

**Prostate gland**

Surrounds ejaculatory ducts and first portion of urethra; produces fluid for semen

**Ejaculatory duct**

Conveys sperm and seminal vesicle secretions to urethra

**Seminal vesicle**

Produces bulk of seminal fluid, including energy sources for sperm

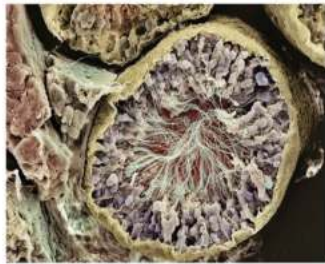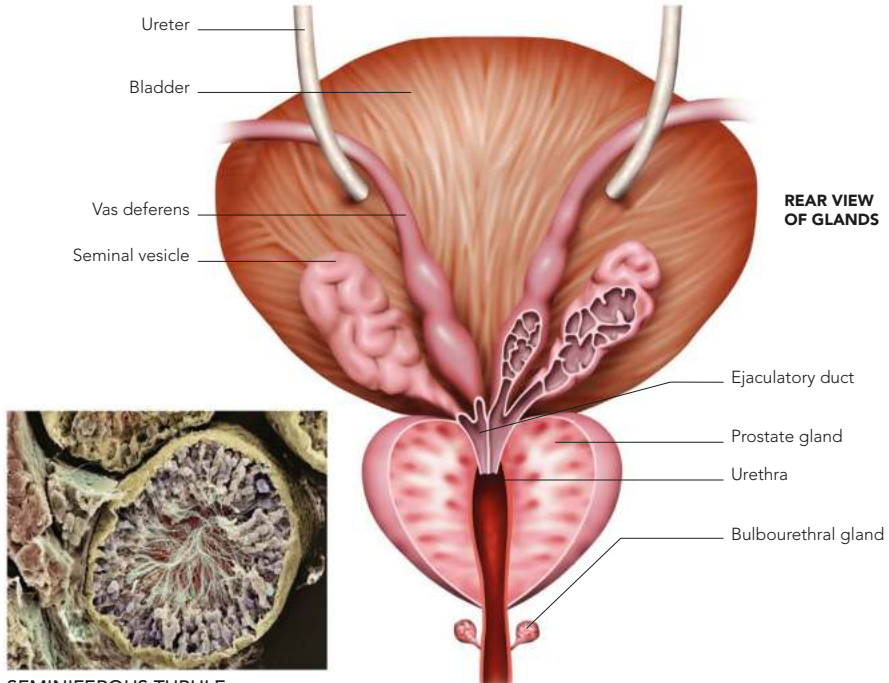
**Anus**

**Rectum**

## ACCESSORY GLANDS

The seminal vesicles and the prostate and bulbourethral glands are together termed the accessory glands. Their secretions are added to sperm during ejaculation. Fluids from the seminal vesicles makes up about 60 per cent of semen by volume, and contain sugar (fructose), vitamin C, and prostaglandins.

Prostate secretions account for about 30 per cent of semen, and include enzymes, fatty acids, cholesterol, and salts to adjust the semen's acid-alkali balance. Secretions from the bulbourethral glands make up 5 per cent of semen, and neutralize the acidity of urine traces in the urethra.

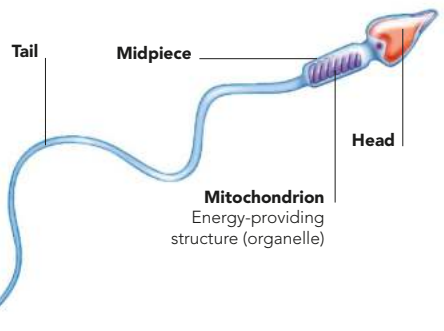


### SEMINIFEROUS TUBULE

This cross-section of a seminiferous tubule shows sperm and their long tails as they move towards the centre.

## MAKING SPERM

Each testis is a mass of more than 800 tightly looped and folded seminiferous tubules. Here, sperm begin as blob-like cells called spermatogonia lining the inner wall. As they mature, they develop tails and move steadily towards the middle of the tubule. Thousands of sperm are produced every second, each taking about two months to mature.

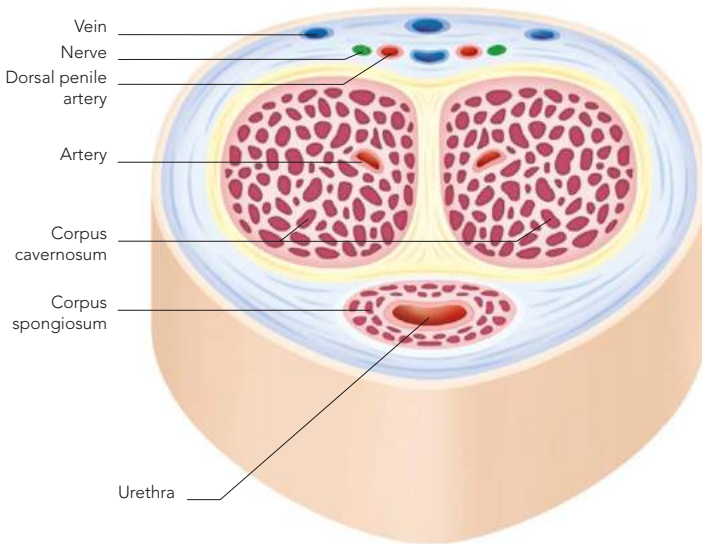




## PATHWAY FOR SPERM

During ejaculation, waves of muscle contraction squeeze the sperm in their fluid from the epididymis along the vas deferens. This tube is joined by a duct from the seminal vesicle to form the ejaculatory duct. The left and right ejaculatory ducts join the urethra within the prostate gland.

In the male, the urethra is a dual-purpose tube that carries urine from the bladder during urination and sperm from the testes. During ejaculation, however, the sphincter at the base of the bladder is closed because of high pressure in the urethra, preventing the passage of urine.



## PENILE ERECTION

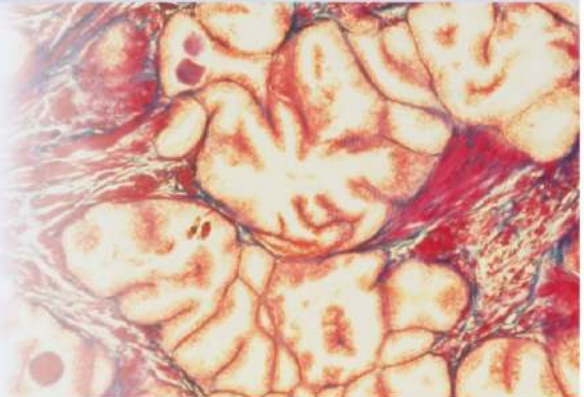
During arousal, large quantities of arterial blood enter the corpus spongiosum and corpus cavernosum, compressing the veins. As a result, blood cannot drain from the penis and it becomes hard and erect.

## SEMEN

Seminal fluid, or semen, is sperm mixed with fluid added by the accessory glands (see opposite), including the prostate gland. The prostate secretes fluid through tiny ducts to mix with sperm as they are ejaculated down the urethra. The final mix has around 300–500 million sperm in 2–5ml ( $\frac{1}{15}$ – $\frac{1}{6}$  fl oz) of fluid.

## PROSTATE GLAND

This microscopic view of a section of prostate gland tissue shows a number of secretory ducts (orange and white).



# FEMALE REPRODUCTIVE SYSTEM

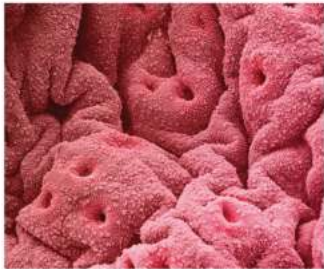THE FEMALE REPRODUCTIVE ORGANS RELEASE AN EGG AT REGULAR INTERVALS AND, IF IT IS FERTILIZED, PROTECT AND NOURISH THE EMBRYO AND FETUS.

## REPRODUCTIVE TRACT

The female reproductive glands (ovaries) lie within the abdomen. From puberty, they mature and release the female sex cells (gametes), known as egg cells or ova. This release occurs roughly once a month as part of the menstrual cycle (see p.283). The ripe egg travels along the fallopian tube to the uterus, the muscular sac in which, if fertilized, it develops into an embryo and then a fetus. Unfertilized eggs, and the uterine lining, are shed via the vagina. The ovaries also make the female sex hormone oestrogen.

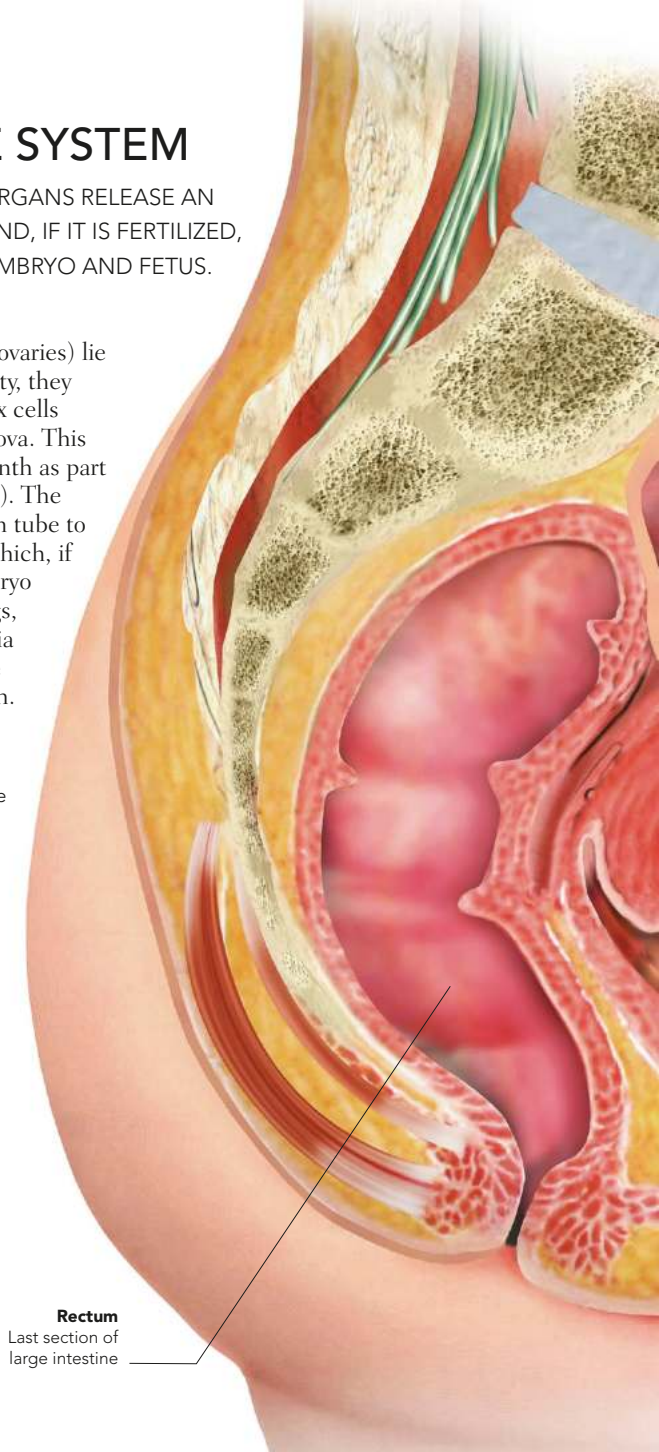
## REPRODUCTIVE ORGANS

A cross-section through the female lower abdomen reveals the reproductive structures and organs. The ovaries sit against the abdominal wall. The fallopian tubes arch from them, opening into the muscular, thick-walled womb (uterus).



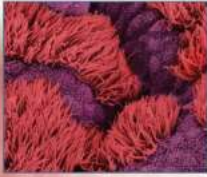## ENDOMETRIUM

This electron micrograph shows the thick, folded, glandular endometrium (the lining of the uterus). The tissue shown is very rich in blood and ready to receive a fertilized egg.



## Rectum

Last section of large intestine



**FALLOPIAN TUBE LINING**

This electron micrograph shows cilia (dark pink) on the fallopian tube lining. They waft a current of fluid to help move an egg to the uterus.

**Fallopian tube**

Also called the oviduct, or egg tube; carries ripe eggs from ovary to uterus

**Fimbriae**

Fingerlike flaps that embrace ovary; they oscillate to guide the ovulated egg into the fallopian tube

**Ovary**

Produces a ripe egg with each menstrual cycle

**Uterus**

Also called the womb; protects and nourishes the developing baby before birth

**Bladder**

Pushes uterus up slightly as it fills with urine

**Pubic symphysis**

Cartilage forming the junction of the two pubic bones

**Cervix**

Narrow, protruding, collar-like neck of the uterus

**Pelvic floor muscles**

Hold and support the organs above

**Clitoris**

**Urethra**

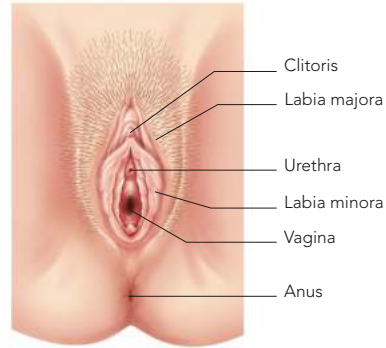
Carries urine from bladder to outside; opens into front part of vulva

**Vagina**

Receptacle for sperm, exit for menstrual blood, and passageway for the baby

## VULVA

The external genital parts of the female are together known as the vulva. They are sited under the mons pubis, a mound of fatty tissue that covers the junction of the two pubic bones, the pubic symphysis. On the outside are the flap-like labia majora, and the smaller, fold-like labia minora lie within them. The labia majora contain sebaceous glands, smooth muscle, and sensory nerve endings. At puberty, their exposed surfaces begin to grow hairs. Within the vulva are the openings to the vagina and the urethra. At the front end of the labia minora is the clitoris. Like the male penis, it is sensitive and engorges with blood when aroused.



### EXTERNAL GENITALS

The external genitals have a protective role, preventing infection from reaching the urethra or vagina, but allowing urine to exit.

## OVULATION

An ovary contains thousands of immature egg cells. During a menstrual cycle, follicle-stimulating hormone (FSH) causes one egg to develop inside a primary follicle. As the follicle enlarges, it moves to the ovary's surface and produces more oestrogen. At ovulation, a surge of luteinizing hormone (LH) causes this secondary follicle to rupture and release the ripe egg. The lining of the empty follicle thickens into a corpus luteum – a temporary source of hormones.

### EGG RELEASE

This coloured electron micrograph shows an egg (red) as it is being released from its follicle into the abdominal cavity. Tendrils (fimbriae) at the end of each fallopian tube guide the egg into the tube.



### INSIDE AN OVARY

The ovary contains eggs that are undeveloped, eggs inside follicles at various stages of maturation, and empty follicles forming corpora lutea. The glandular tissue around these follicles is known as the stroma.

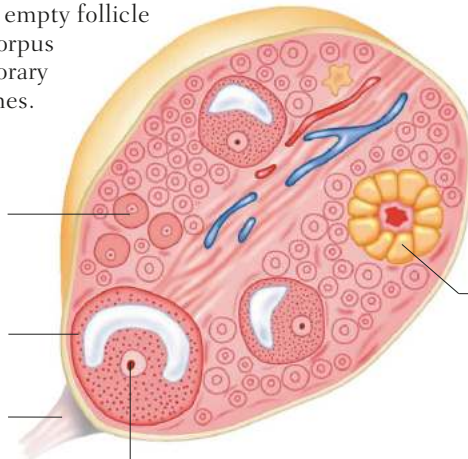
**Primary follicle**  
Early development; contains primary oocyte (unripe egg cell)

**Secondary follicle**  
Mature stage of development, containing secondary oocyte (ripened egg)

**Ovarian ligament**  
Stabilizes position of ovary within abdomen

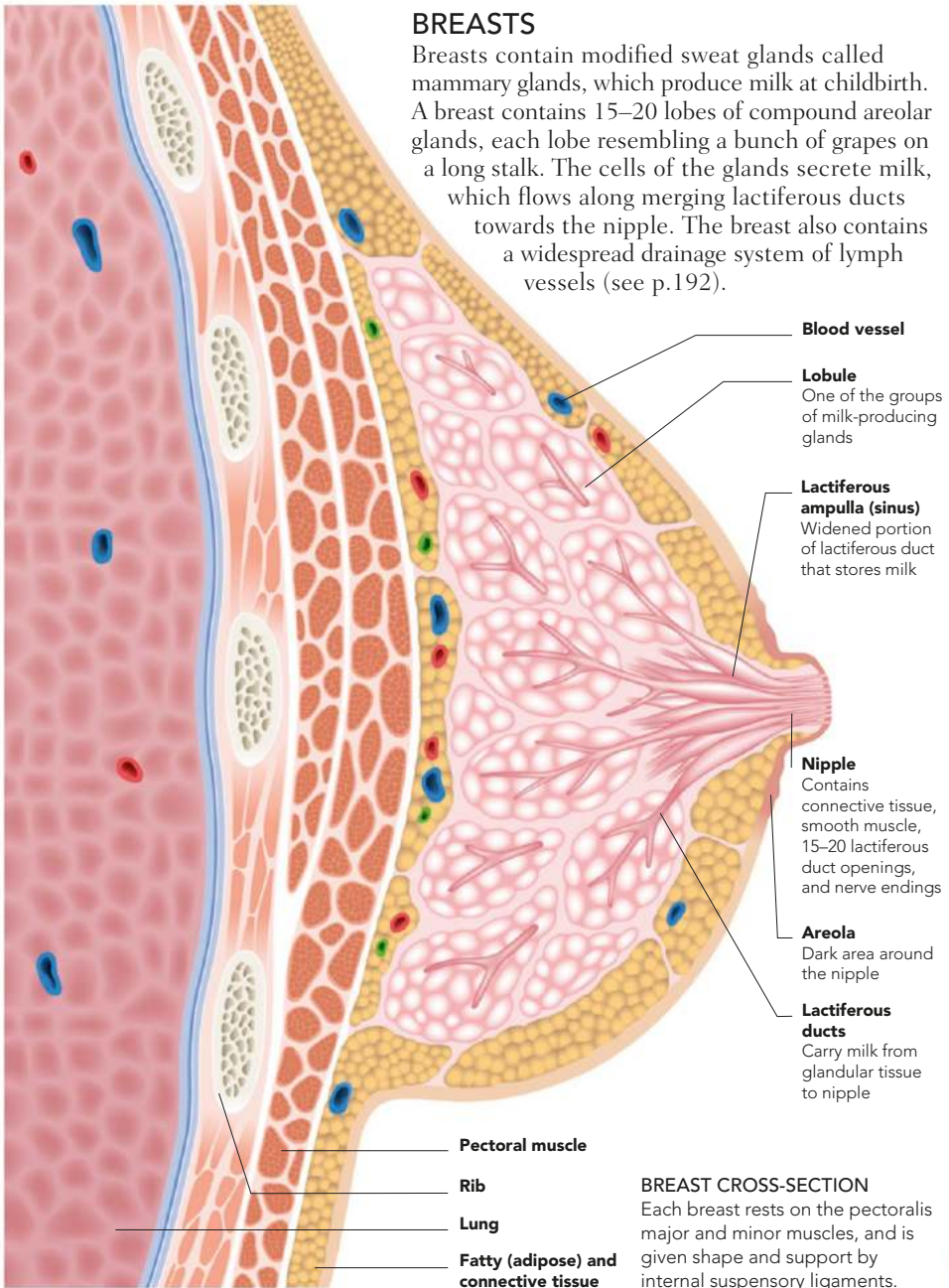
**Egg**

**Corpus luteum**  
An empty follicle, filled with hormone-producing cells



## BREASTS

Breasts contain modified sweat glands called mammary glands, which produce milk at childbirth. A breast contains 15–20 lobes of compound areolar glands, each lobe resembling a bunch of grapes on a long stalk. The cells of the glands secrete milk, which flows along merging lactiferous ducts towards the nipple. The breast also contains a widespread drainage system of lymph vessels (see p.192).



**Blood vessel**

**Lobule**

One of the groups of milk-producing glands

**Lactiferous ampulla (sinus)**

Widened portion of lactiferous duct that stores milk

**Nipple**

Contains connective tissue, smooth muscle, 15–20 lactiferous duct openings, and nerve endings

**Areola**

Dark area around the nipple

**Lactiferous ducts**

Carry milk from glandular tissue to nipple

**Pectoral muscle**

**Rib**

**Lung**

**Fatty (adipose) and connective tissue**

### BREAST CROSS-SECTION

Each breast rests on the pectoralis major and minor muscles, and is given shape and support by internal suspensory ligaments.

# CONCEPTION TO EMBRYO

THE EMBRYONIC CELLS REPEATEDLY DIVIDE, AND BECOME IMPLANTED INTO THE UTERUS LINING.

The first eight weeks in the uterus are known as the embryo stage, in which the fertilized egg becomes a tiny human body, no larger than a thumb. The fertilized egg develops into an enlarging cluster of cells, the blastocyst. Some cells will form the baby's body; while others become the protective membranes or the placenta, which nourishes the embryo and removes waste products.

**Fallopian tube**  
Conveys zygote towards uterus

**First cleavage**  
Large zygote splits itself into two cells

**Cilia**  
Microhairs waft the zygote along

**Goblet cells**  
Secrete fluid into tube

## 2 ZYGOTE

The fertilized egg passes along the fallopian tube. Within 24–36 hours it has divided into two cells, then 12 hours later into four cells, and so on. This process is known as cleavage. At each stage the resulting cells become smaller, gradually approaching normal body cell size.

## 1 FERTILIZATION

Fertilization takes place in the fallopian tube, when the head of the sperm cell, or spermatozoon, penetrates the much larger ripe egg cell, or mature ovum. This forms a single cell – the fertilized egg, or zygote, which contains 23 pairs of chromosomes (see p.286).

**Morula**  
**Fallopian tube lining**

**Cilia**

## 3 MORULA

A cluster of 16–32 cells, the morula leaves the fallopian tube and enters the uterus at around 3–4 days after fertilization.

**Fallopian tube**

**Fimbriae**

**Ovary**

**Ovarian ligament**

## Ovum (egg cell)

Up to 0.1mm ( $\frac{1}{250}$  in) across (huge compared to other cells); contains 23 maternal chromosomes

## Corona cell

Secretes chemicals to aid egg development

## Tail of sperm

Lashes to propel sperm towards egg

## Sperm head

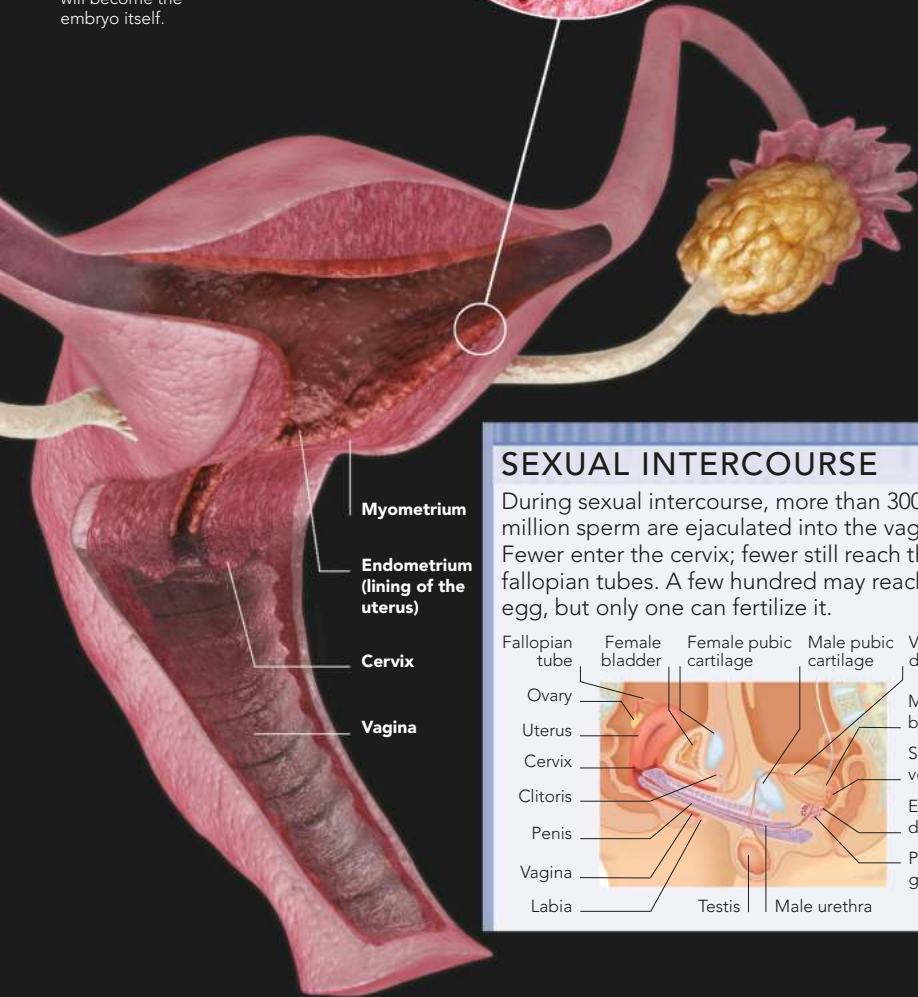
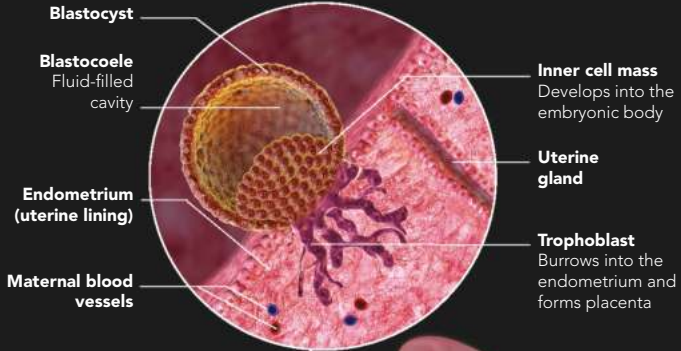
Contains 23 paternal chromosomes

## Acrosome

"Cap" of sperm head, which penetrates egg cell membrane

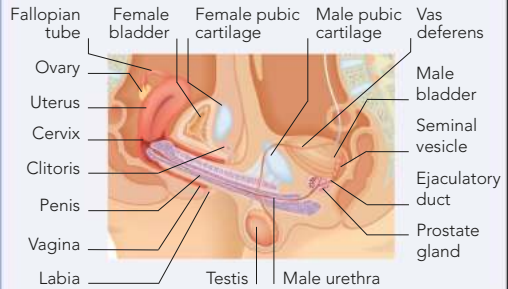
#### 4 BLASTOCYST

About six days after fertilization, the cell cluster forms a hollow cavity and is known as a blastocyst. It floats within the uterus for around 48 hours before landing on the thick uterus lining (endometrium), which softens to aid implantation (burrowing of the blastocyst into the endometrium). The inner group of cells will become the embryo itself.



### SEXUAL INTERCOURSE

During sexual intercourse, more than 300 million sperm are ejaculated into the vagina. Fewer enter the cervix; fewer still reach the fallopian tubes. A few hundred may reach the egg, but only one can fertilize it.

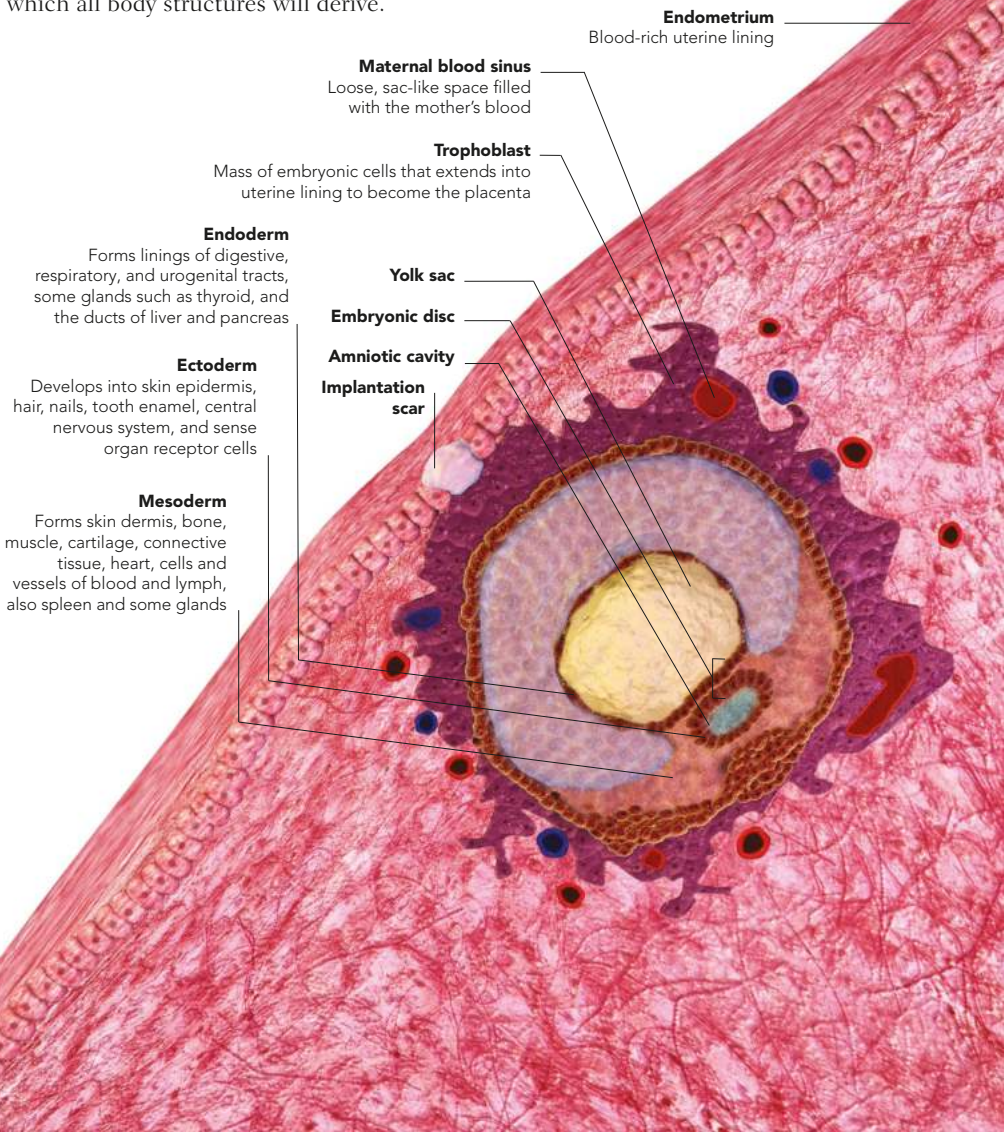


## EMBRYONIC DISC

Within the inner cell mass, an embryonic disc forms. This separates the cell cluster into the amniotic cavity, which develops into a sac that will fill with fluid and fold around to cover the embryo, and the yolk sac, which helps to transport nutrients to the embryo during the second and third weeks. The disc develops three circular sheets called the primary germ layers – ectoderm, mesoderm, and endoderm – from which all body structures will derive.

## EARLY DEVELOPMENT

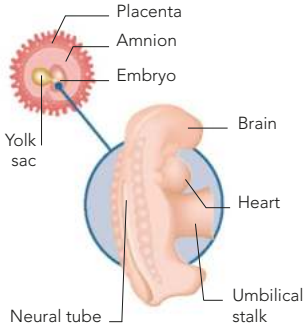
As soon as implantation has taken place in the lining of the uterus, development begins. The embryonic disc forms the three germ layers, and the placenta starts to form from the trophoblast.





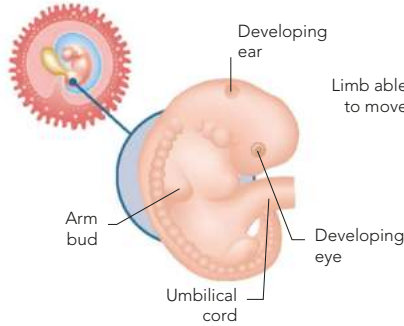
## GROWING EMBRYO

In general, development is head-down: the brain and head take shape early, then the body, the arms, and lastly the legs. Eight weeks after fertilization, all major organs and body parts have formed. From this time on, the baby is known as a fetus.



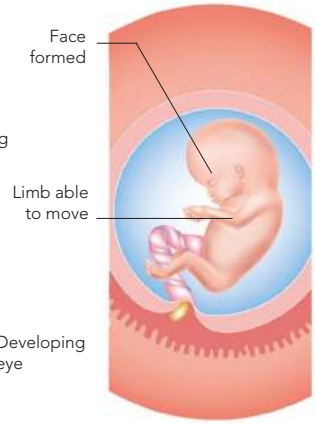
### THREE WEEKS

The embryo is 2–3mm ( $\frac{1}{50}$ – $\frac{5}{50}$  in) long. The neural tube forms. It will become the spinal cord, with a brain at one end. A tube-like heart pulsates.



### FOUR WEEKS

The embryo is about 4–5mm ( $\frac{1}{5}$  in) long. A four-chambered heart beats, sending blood through simple vessels. Intestines, liver, lungs, and limb buds can be seen.

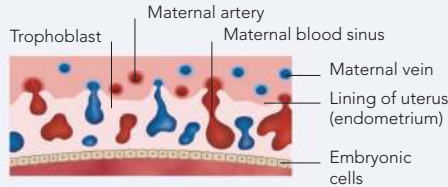


### EIGHT WEEKS

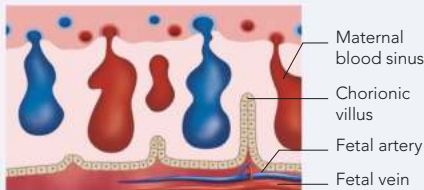
The embryo is around 25–30mm (1–1  $\frac{1}{5}$  in) long. The face, neck, fingers, and toes can be seen.

## DEVELOPMENT OF THE PLACENTA

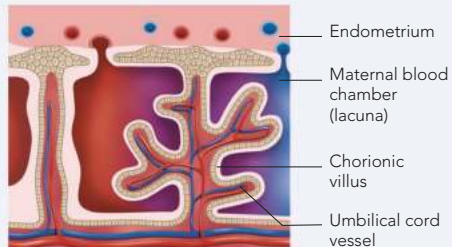
The placenta derives from the trophoblast – the outer layer of the blastocyst (the mass of cells that results from the fusion of egg and sperm). It begins to form soon after the fertilized egg implants in the uterine lining (see opposite), and becomes almost fully developed by the fifth month of pregnancy.



**1** Embryonic cells extend into uterine blood vessels, so that maternal blood flows into spaces (sinuses) within the trophoblast.



**2** Fingerlike projections, called chorionic villi, grow and are surrounded by maternal blood sinuses. Later, fetal blood vessels grow into the villi.



**3** The villi branch further and the maternal blood sinuses enlarge into lacunae (“lakes”), supplying the placenta with oxygen and nutrients.

# FETAL DEVELOPMENT

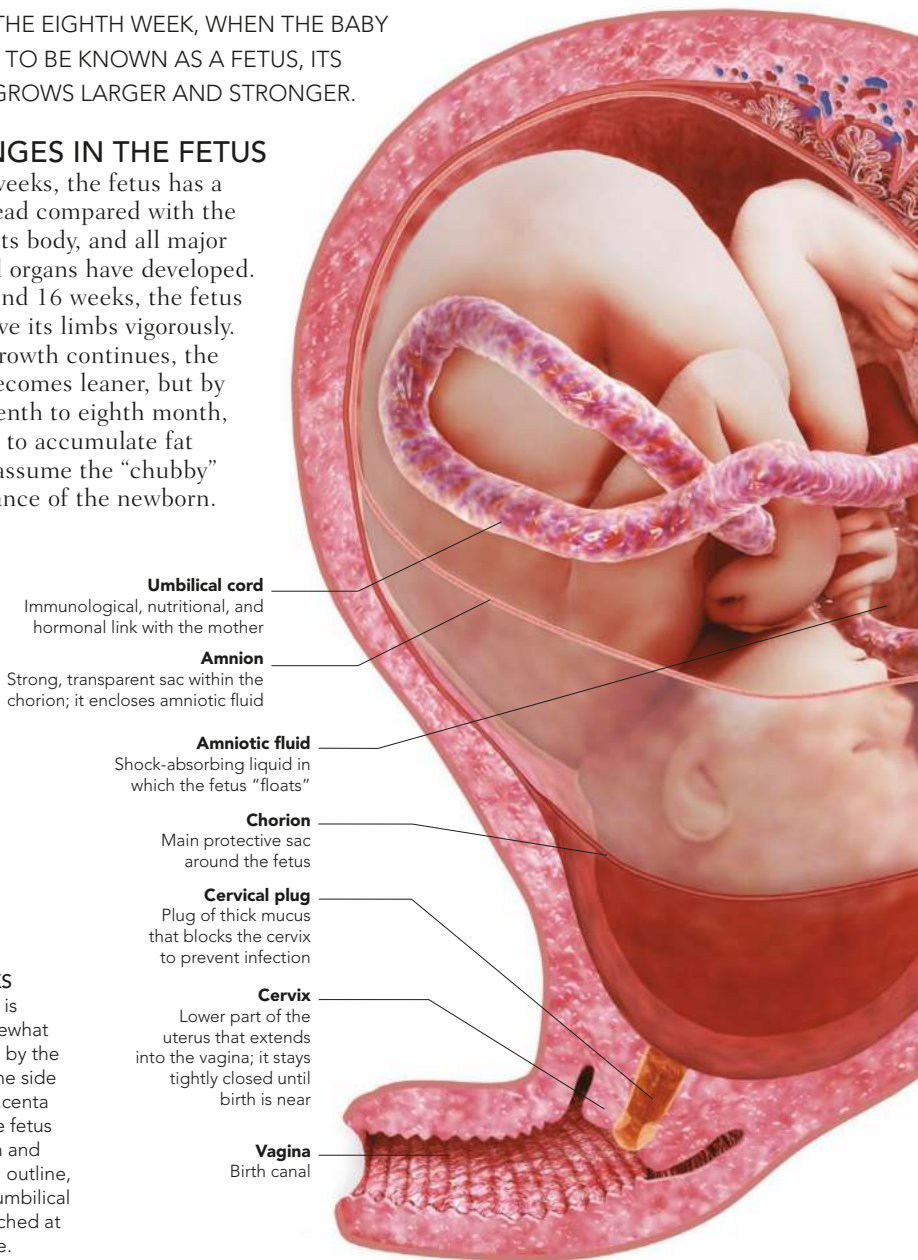
FROM THE EIGHTH WEEK, WHEN THE BABY STARTS TO BE KNOWN AS A FETUS, ITS BODY GROWS LARGER AND STRONGER.

## CHANGES IN THE FETUS

By 12 weeks, the fetus has a large head compared with the rest of its body, and all major internal organs have developed. By around 16 weeks, the fetus can move its limbs vigorously. As its growth continues, the fetus becomes leaner, but by the seventh to eighth month, it starts to accumulate fat and to assume the “chubby” appearance of the newborn.

### 36 WEEKS

The fetus is now somewhat restricted by the uterus. The side of the placenta facing the fetus is smooth and circular in outline, with the umbilical cord attached at the centre.



#### Umbilical cord

Immunological, nutritional, and hormonal link with the mother

#### Amnion

Strong, transparent sac within the chorion; it encloses amniotic fluid

#### Amniotic fluid

Shock-absorbing liquid in which the fetus “floats”

#### Chorion

Main protective sac around the fetus

#### Cervical plug

Plug of thick mucus that blocks the cervix to prevent infection

#### Cervix

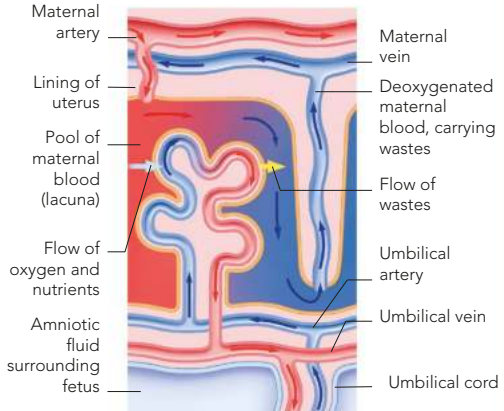
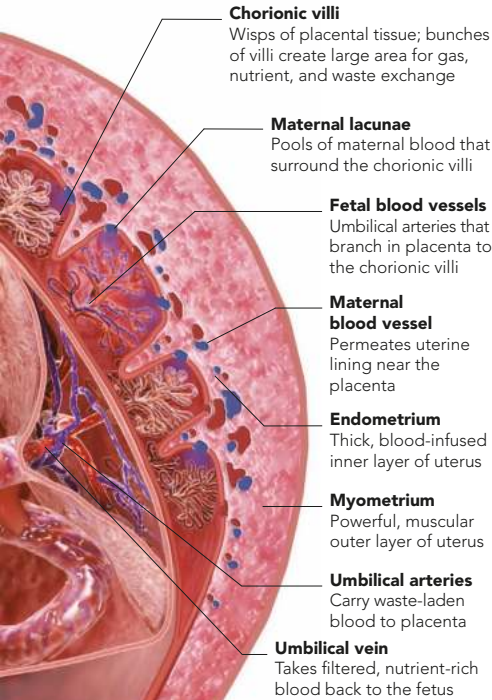
Lower part of the uterus that extends into the vagina; it stays tightly closed until birth is near

#### Vagina

Birth canal

## HOW THE PLACENTA WORKS

Oxygen, nutrients, and antibodies pass from the mother to the fetus in the umbilical veins; fetal waste passes to the mother in the umbilical arteries.

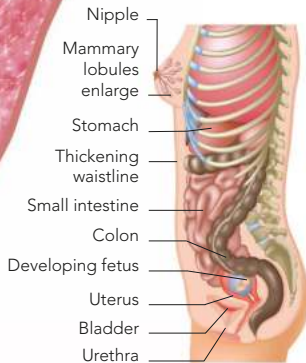


### EXCHANGE OF OXYGEN AND NUTRIENTS

A thin barrier of cells in the chorion allows the exchange of gases, nutrients, and waste between mother and fetus.

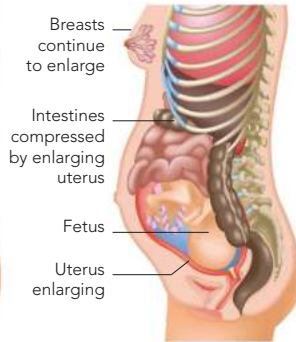
## CHANGES IN THE MOTHER

Pregnancy is divided into trimesters, each lasting about three calendar months. During this time, the mother's body changes to support the fetus and to prepare itself for childbirth and breast-feeding.



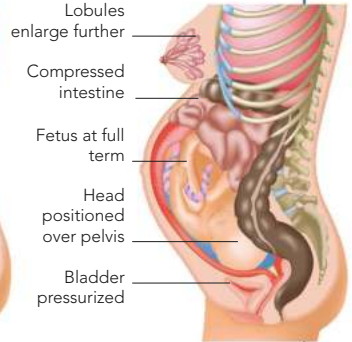
### FIRST TRIMESTER

Breasts become tender and larger, with darkened areolas; nausea and vomiting are common.



### SECOND TRIMESTER

Enlarging uterus shows; heart rate increases; forehead and cheek skin may temporarily darken.



### THIRD TRIMESTER

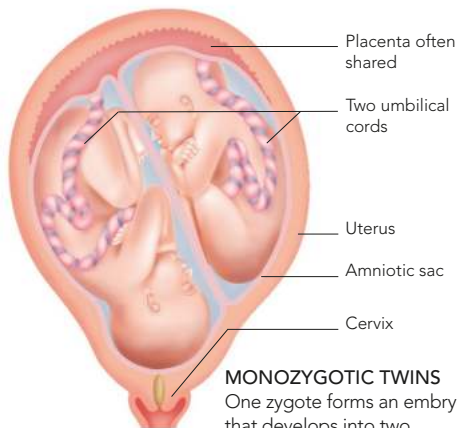
Abdominal skin stretches; fatigue, back pain, heartburn, and some breathlessness may occur.

# PREPARING FOR BIRTH

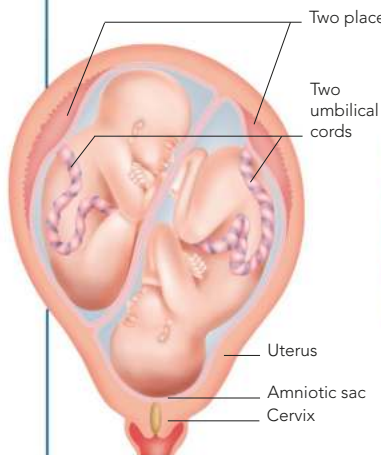
CHANGES DURING LATE PREGNANCY SIGNAL THE APPROACH OF CHILDBIRTH. THE HEAD OF THE FETUS DROPS LOWER INTO THE PELVIS; THE EXPECTANT MOTHER MAY EXPERIENCE WEIGHT LOSS; AND THERE MAY BE EARLY UTERINE CONTRACTIONS.

## MULTIPLE PREGNANCY AND FETAL POSITIONS

The presence of more than one fetus in the uterus is called a multiple pregnancy. Twins occur in approximately one in 80 pregnancies, and triplets in about one in 8,000. After about 30 weeks, the most common fetal position is head down, facing the mother's back, with the neck flexed forward. Such a position eases the baby's passage through the birth canal. However, about 1 in 30 full-term deliveries is breech, in which the baby's buttocks emerge before the head.

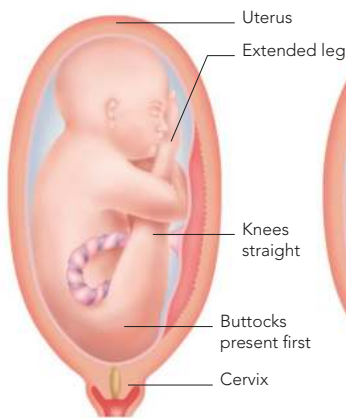


**MONOZYGOTIC TWINS**  
One zygote forms an embryo that develops into two fetuses that have the same genes and sex and often share one placenta. They are "identical" twins.



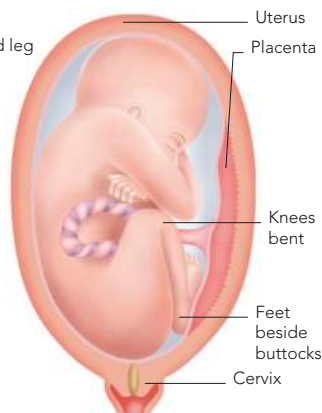
### DIZYGOTIC TWINS

Two zygotes develop separately, each with its own placenta. They may be different or the same sex. They are "fraternal twins" and are like any brothers and sisters.



### FRANK BREECH

The baby fails to turn head-down in the uterus. The hips are flexed and the legs are straight, extending alongside the body so that the feet are positioned beside the head.



### COMPLETE BREECH

The legs are flexed at the hips and knees, so the feet are next to the buttocks. The incidence of breech delivery is much higher among premature babies.

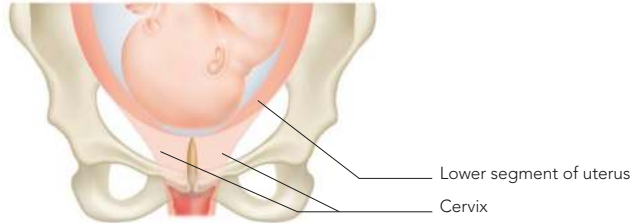
## CHANGES IN THE CERVIX

The cervix is the firm band of muscle and connective tissue that forms the neck-like structure at the bottom of the uterus. In late pregnancy, it softens in readiness for childbirth. Sporadic uterine tightenings,

known as Braxton–Hicks contractions, help to thin the cervix so that it merges with the uterus’s lower segment. These are usually painless and become noticeable only after the middle of pregnancy.

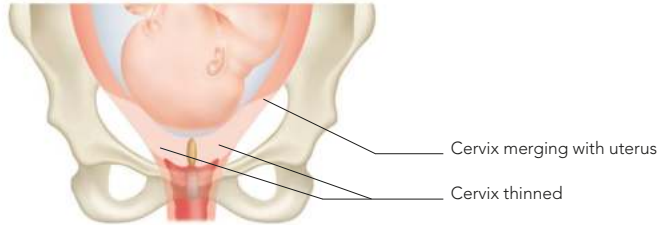
### CERVIX SOFTENING

As labour nears, the cervix tissues lose their firm consistency. They become softer and more spongy, affected by natural substances in the blood called prostaglandins.



### CERVIX THINNING

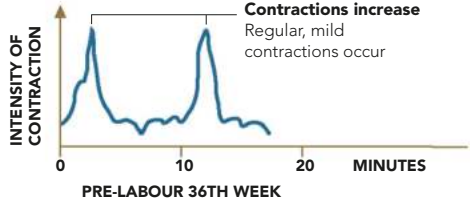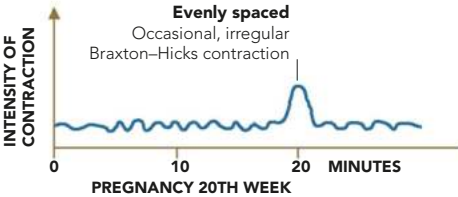
The cervix becomes wider and thinner, and merges smoothly into the uterus wall above. The process of softening and thinning is known as effacement.



## CONTRACTIONS

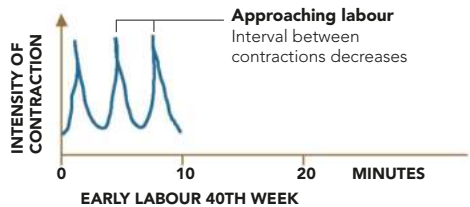
The shortening of uterine muscles, with the eventual aim of expelling the fetus, are called contractions, which are regular and become steadily more frequent, more

painful, and longer-lasting. The main area of contraction is in the muscles of the uterine fundus (upper uterus), which stretches, causing the lower uterus and cervix to thin.



### PROGRESS OF CONTRACTIONS

Gentle, partial contractions occur through much of pregnancy. True contractions begin late in pregnancy. At first, they are occasional and relatively weak. As labour intensifies, they are more frequent and last longer, putting more downward pressure on the baby.



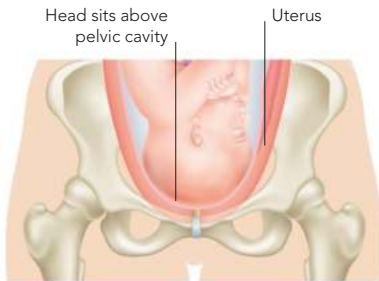
# LABOUR

LABOUR USUALLY MEANS THE FULL PROCESS OF GIVING BIRTH. IT CAN BE DIVIDED INTO THREE PHASES OR STAGES: ONSET OF CONTRACTIONS TO FULL DILATION OF THE CERVIX; DELIVERY OF THE BABY; AND DELIVERY OF THE PLACENTA (AFTERBIRTH).

## ENGAGEMENT

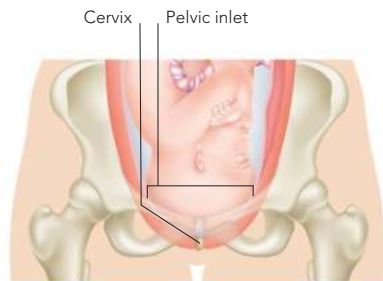
Towards the end of pregnancy, the part of the baby that will emerge first – usually the head – descends into the pelvic cavity. This is called engagement. Many women feel a sensation of dropping and “lightening” as it happens because the movement of the

baby lowers the upper uterus, relieving the pressure on the diaphragm and making it easier for the mother to breathe. Engagement usually takes place at about 36 weeks during a first pregnancy and at the onset of labour during subsequent pregnancies.



### BEFORE THE HEAD ENGAGES

Before engagement, the top of the uterus reaches the breastbone. The baby's head has yet to pass through the inlet of the pelvis into the cavity.



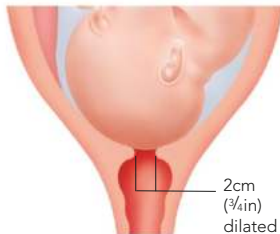### AFTER ENGAGEMENT

The baby's head descends into the pelvic cavity. The overall position of the uterus drops, and the baby's head rests against the uterine cervix.

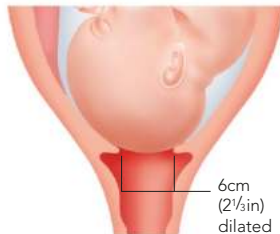## CERVICAL DILATION

Labour begins with the onset of regular, painful contractions, which dilate the cervix. These occur mainly in the upper uterus, which shortens and tightens, pulling and stretching the lower uterus

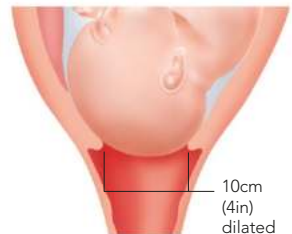and cervix. For a first baby, the cervix dilates at about 1cm ( $\frac{1}{2}$ in) per hour on average; progress is usually quicker for subsequent babies. In most women, the cervix is fully dilated when it opens to around 10cm (4in).



INITIAL DILATION



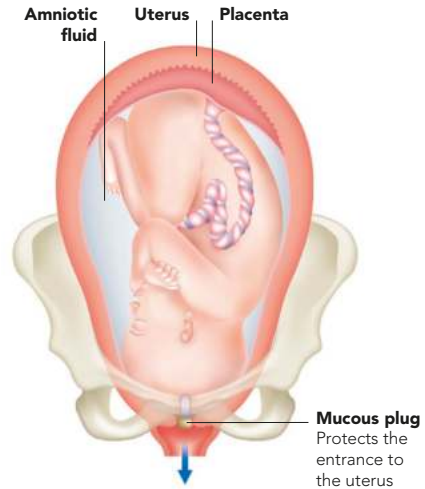
CERVIX WIDENS



FULLY DILATED

## SIGNS OF EARLY LABOUR

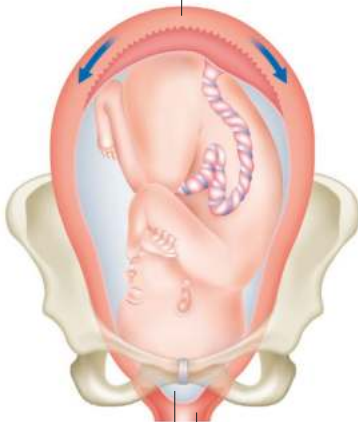
Every woman's personal experience of childbirth is different, but generally there are three particular signs that labour is starting. First there is a "show", followed by contractions, and finally the waters break. Before labour begins (usually less than 3 days), the mucous plug in the cervix, which has been acting as a seal during pregnancy, is passed as a blood-stained or brownish discharge (the "show"). As the contractions of the uterus become stronger and more regular, the membranes that retain the amniotic fluid rupture (break), allowing the fluid (water) to leak out via the birth canal.



### 1 THE "SHOW"

For most of the time during a pregnancy, the mucous plug in the cervix prevents microbes from entering the uterus. As the cervix widens slightly, the plug loosens and falls out.

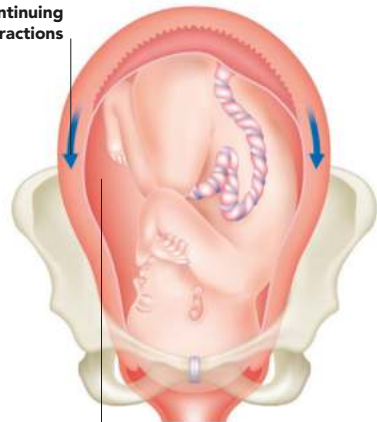
**Fundus**  
Muscular wall contracts most forcefully here



**Bulging sac**  
Pressure causes the membranes to bulge at the cervical opening

**Dilating cervix**  
The cervix thins and its passageway widens (dilates)

**Continuing contractions**



**Waters broken**  
Amniotic fluid drains away

### 2 CONTRACTIONS

Coordinated muscular contractions are generated in the upper part of the uterus, called the fundus. This helps to gradually open, or dilate, the cervix.

### 3 WATER BREAKS

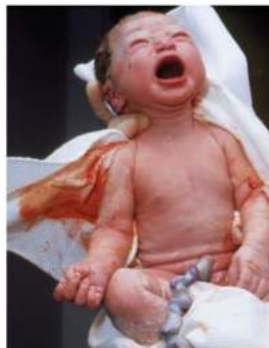The amniotic sac (membrane) around the baby ruptures, or breaks, allowing colourless amniotic fluid to pass out through the birth canal.

# DELIVERY

THE CULMINATION OF PREGNANCY AND LABOUR, DELIVERY OF THE BABY AND THE PLACENTA INVOLVES A COMPLEX SEQUENCE OF EVENTS THAT ULTIMATELY SEPARATES CHILD FROM MOTHER, ALLOWING THE START OF THEIR INDEPENDENT RELATIONSHIP.

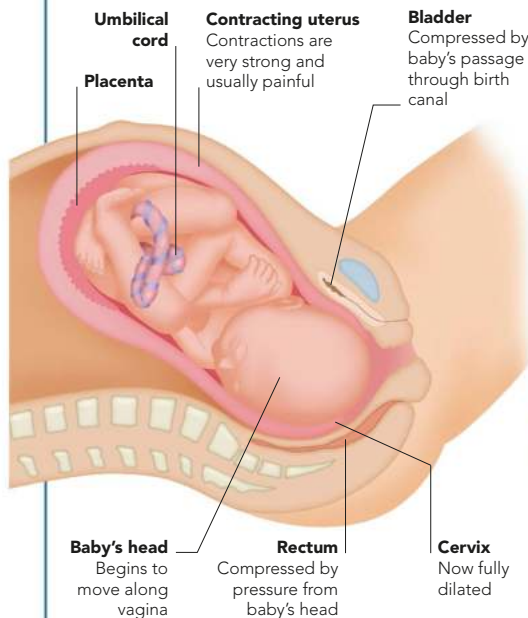
## THREE STAGES OF CHILDBIRTH

During the first stage, the cervix dilates and the waters break (see p.269). The second stage, delivery, sees uterine contractions synchronize with shifts in the baby's position as it fits its large head into the birth canal and then travels along it to the outside world. In the third stage, the placenta, or "afterbirth", is delivered, often with the help of a midwife or obstetrician gently pulling on the cord.



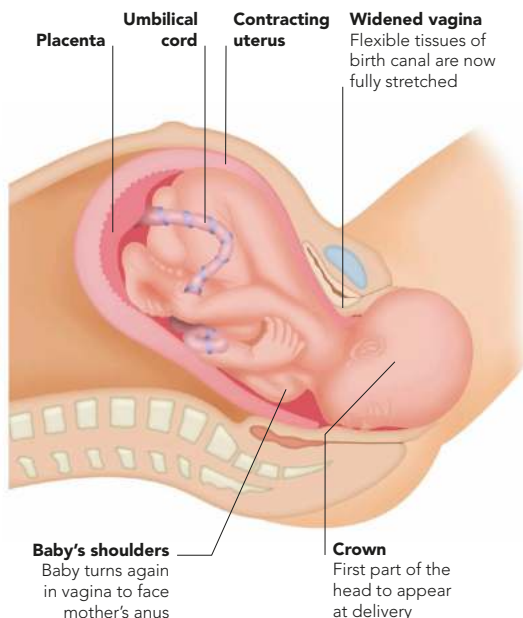
### NORMAL DELIVERY

Newborn babies are usually covered with a combination of blood, mucus, and vernix (the greasy covering that protected the fetus in the uterus). This baby's umbilical cord has not yet been clamped and cut.



### 1 DILATION OF THE CERVIX

When the cervix is fully dilated, the baby turns so that the widest part of its skull aligns with the widest part of the mother's pelvis. As the baby tucks in its chin, it starts moving out of the uterus.



### 2 DESCENT THROUGH THE BIRTH CANAL

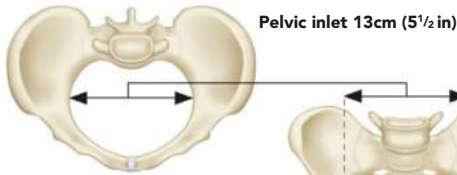
The top of the baby's head appears ("crowning"). Usually, the baby faces the mother's anus, allowing the emerging head to negotiate the bend in the fully stretched vagina. Birth is usually imminent at this point.



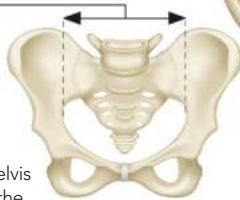
## PELVIC SHAPES

A female's pelvis is adapted to child-bearing and delivery, but it varies greatly in shape. Some shapes make childbirth easier than others. The classic "female pelvis" (gynecoid)

has a generous capacity, and usually results in few problems. A pelvis that is more like a man's (android) is less spacious and can cause difficulties with childbirth.

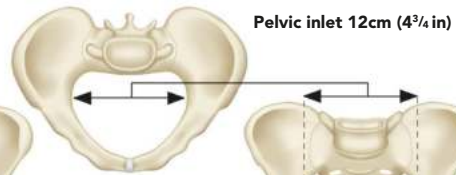


VIEW FROM ABOVE

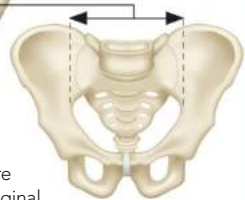


### GYNECOID PELVIS

The round, shallow gynecoid pelvis allows the uterus to expand as the fetus grows. The wider pelvic inlet provides more room for the head of a fetus to pass through.

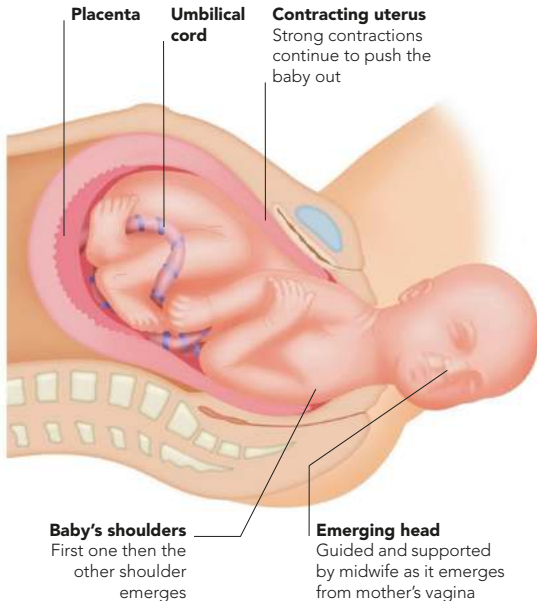


VIEW FROM ABOVE



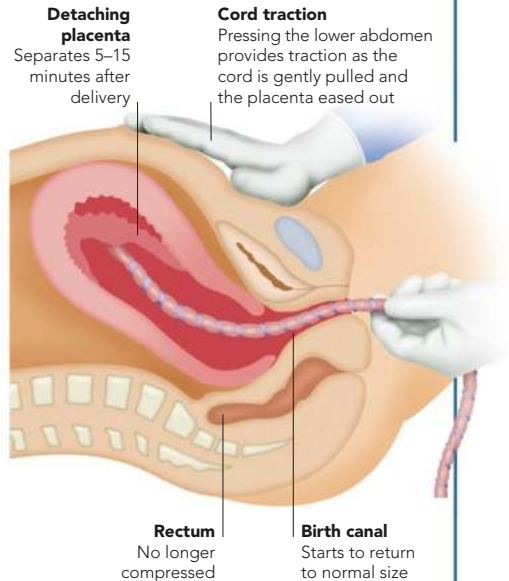
### ANDROID PELVIS

An android pelvis is more triangular in shape. A vaginal delivery can be difficult for a woman with an android pelvis unless her baby is small.



### 3 DELIVERY OF THE BABY

The midwife checks the cord is not around the baby's neck, and clears mucus from its nose and mouth. The baby rotates again so the shoulders can slip out easily, one shoulder quickly followed by the other.



### 4 DELIVERY OF THE PLACENTA

The uterus mildly contracts soon after the baby is born, sealing any bleeding blood vessels. The placenta separates from the uterus and is eased out by gently pulling the cord while pressing on the lower abdomen.

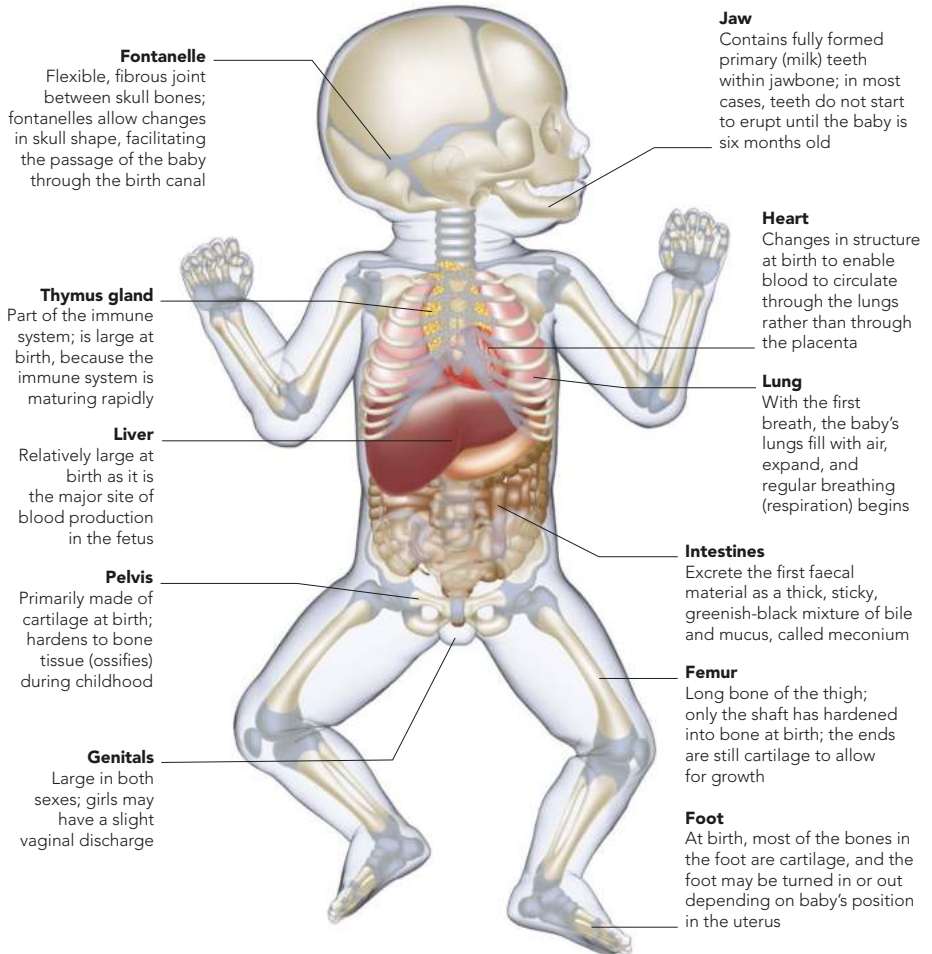
# AFTER THE BIRTH

OVER 40 WEEKS, THE FERTILIZED EGG HAS CHANGED FROM FETUS TO NEWBORN BABY. ALL ORGAN SYSTEMS ARE IN PLACE – SOME QUICKLY ADAPT TO LIFE WITHOUT AN UMBILICAL CORD, WHILE OTHERS ONLY DEVELOP FULLY IN ADOLESCENCE.

## NEWBORN ANATOMY

Special features in a baby's anatomy help it to grow and develop outside the uterus. Fontanelles allow the skull to expand as the brain grows; they become bone by the time the child is about six years old. Cartilage

in the joints and at the end of long bones allows the skeleton to grow rapidly. In the fetus, the liver produced all the red blood cells, and this task is now taken over by the bone marrow.



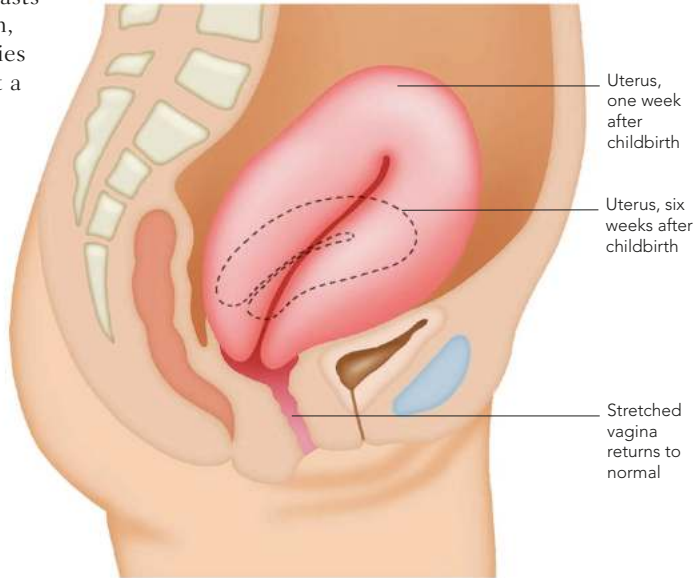
## CHANGES IN THE MOTHER

Many physiological changes take place in the mother after birth, for which her body has prepared during pregnancy. The process of enhancing breast tissue in anticipation of breast-feeding begins early in pregnancy: the breasts enlarge visibly, and the alveoli in each of the milk-producing glands (lobules) swell and multiply. From three months into the pregnancy, the breasts can produce colostrum, a fluid rich in antibodies (which help to protect a

newborn from allergies and respiratory and gastrointestinal infections), water, protein, and minerals. After the birth, colostrum supplies a breast-fed baby with nutrition until the mother's milk begins to flow several days later. Soon after birth, the uterus begins to shrink to its pre-pregnancy size – a process that is helped by breast-feeding.

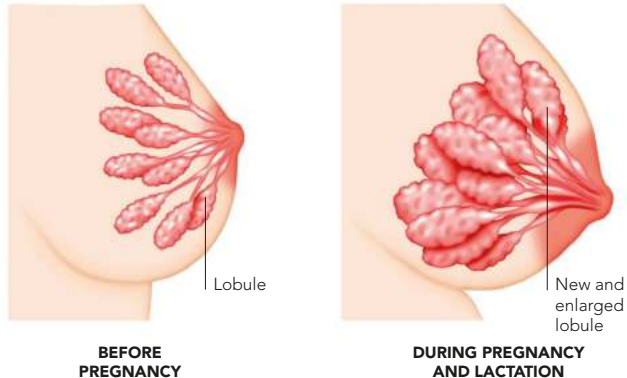
### UTERUS SHRINKS

After delivery of the baby and the placenta in the second and third stages of labour, hormones in the mother's body cause her uterus and vagina to shrink back to their normal size and position in her body.



### LACTATION

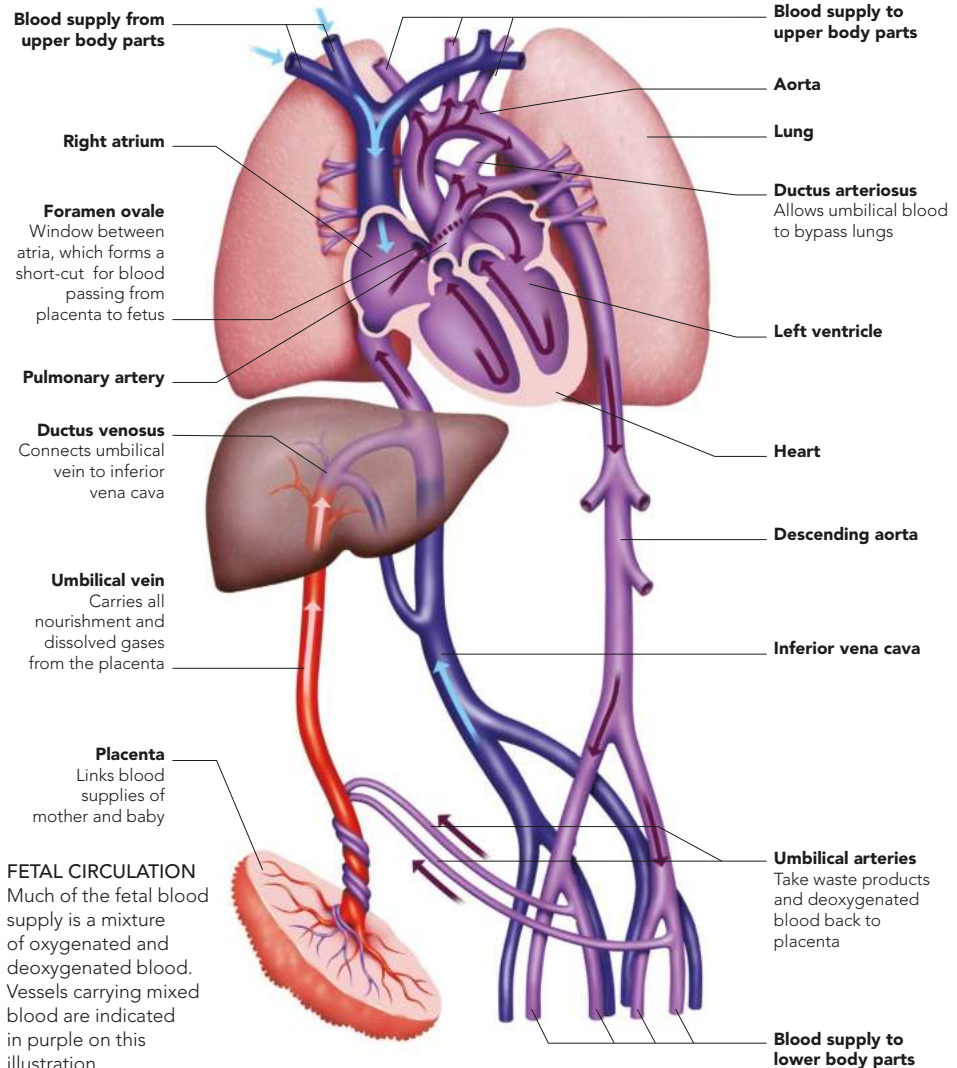
During pregnancy, lobules (milk-producing glands) increase in size and number in preparation for breast-feeding the baby. By the end of the first trimester, they can produce colostrum, the yellow fluid that provides antibodies to protect against allergies and gastrointestinal and respiratory infections in the newborn.



## CIRCULATION IN THE UTERUS

As the placenta provides oxygen and nutrients, the fetal circulation has anatomical variations (“shunts”) that bypass the not-yet-functioning liver and lungs. The ductus venosus shunts incoming blood through the liver to the right atrium, which shunts it through a gap, the

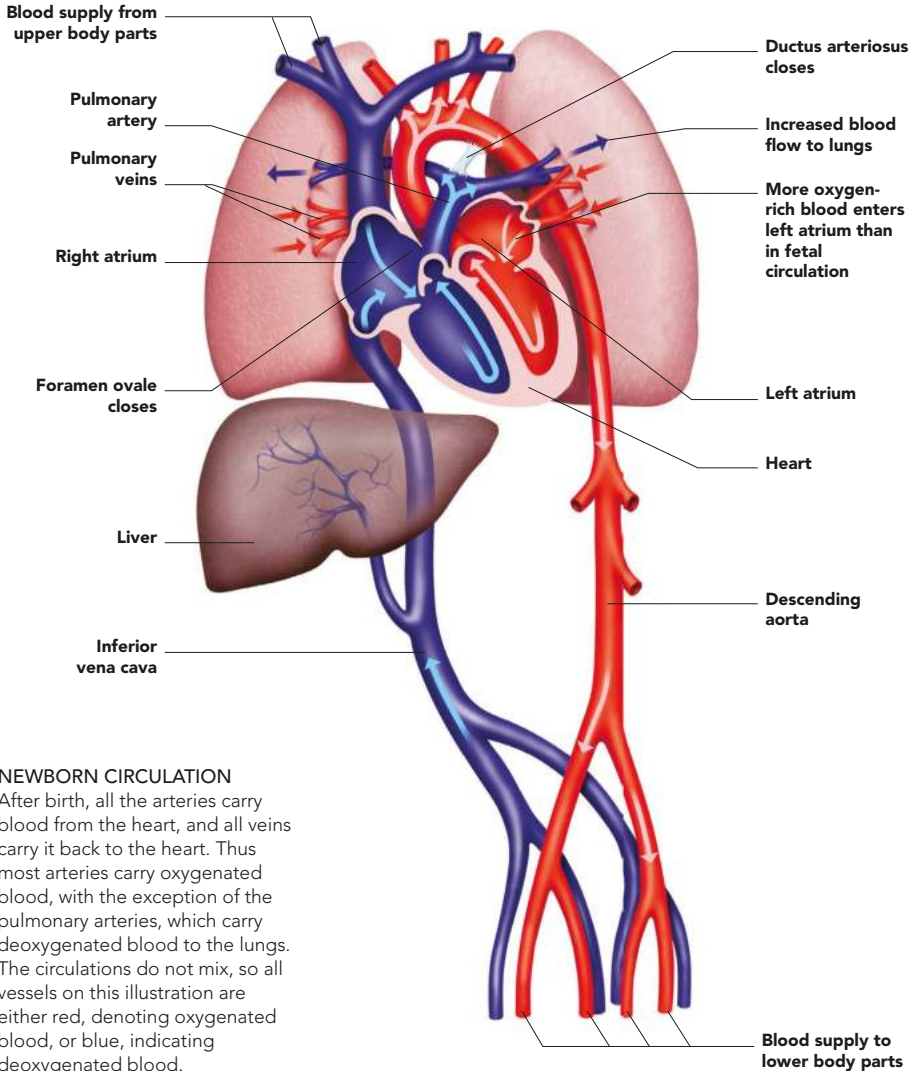
foramen ovale, to the left atrium (mostly bypassing the right ventricle) and onward to the body. Any blood that enters the right ventricle passes into the pulmonary artery but is shunted into the aorta by the ductus arteriosus, thus bypassing the lungs.



## CIRCULATION AT BIRTH

At birth, the baby takes its first breaths and the umbilical cord is clamped. This forces the circulatory system into a monumental response: to convert itself immediately to obtain its oxygen supply via the lungs. Blood is sent to the lungs to retrieve oxygen, and the pressure of this blood

returning from the lungs into the left atrium forces shut the foramen ovale between the two atria, thus establishing normal circulation. The ductus arteriosus, the ductus venosus, and the umbilical vein and arteries close up and become ligaments.



### NEWBORN CIRCULATION

After birth, all the arteries carry blood from the heart, and all veins carry it back to the heart. Thus most arteries carry oxygenated blood, with the exception of the pulmonary arteries, which carry deoxygenated blood to the lungs. The circulations do not mix, so all vessels on this illustration are either red, denoting oxygenated blood, or blue, indicating deoxygenated blood.

# GROWTH AND DEVELOPMENT

YOUNG CHILDREN DEVELOP BASIC PHYSICAL SKILLS AND THEN BECOME MORE AGILE, WITH INCREASED INTELLECTUAL ABILITIES. PHYSICAL GROWTH RATE IS RAPID DURING INFANCY, AND THEN IS FAIRLY STEADY UNTIL IT SPEEDS UP AGAIN AT PUBERTY.

## BONE GROWTH

Body growth depends on the increasing size of the skeleton. The long leg bones provide most of the increase in height. Many long bones develop from cartilage precursors, by a sequence of changes

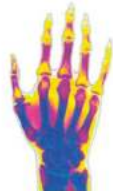(ossification) that starts before birth at primary centres in the bone shafts. After birth, secondary centres develop near the bone ends. Growth ceases once ossification is complete, at 18–20 years of age.



1 YEAR



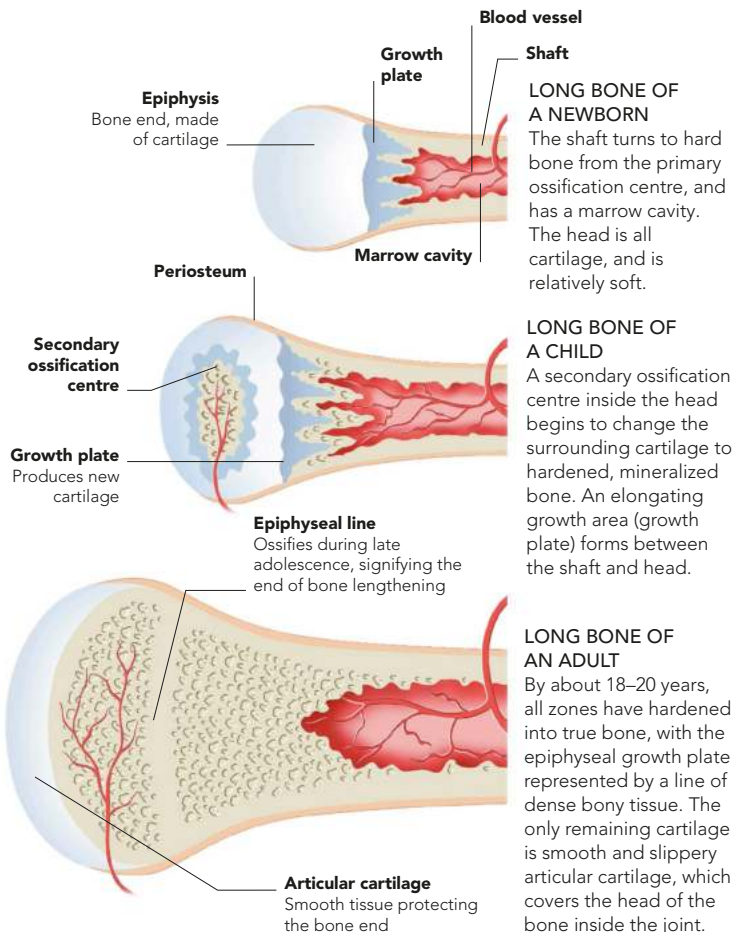
3 YEARS



20 YEARS

### CARTILAGE TO BONE

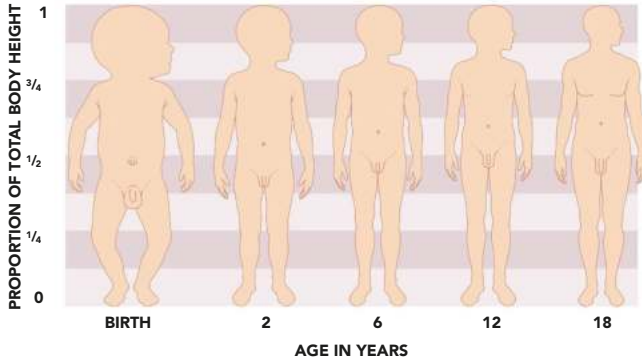
These X-rays of the hand and wrist show bony tissue as darker pink, blue, or purple. At one year, the bones in the wrist and fingers are largely made of cartilage. At three years, ossification of cartilage is well under way, and by 20 years the bones are fully formed.



## CHANGING PROPORTIONS

A newborn's head is relatively large, being wider than the shoulders and representing about a quarter of the baby's total height; the legs are about three-eighths of this height. As the child grows, the arms and

legs "catch up". At two years, the head is about a sixth of the total height. When final adult size is reached during adolescence, the head is only about an eighth of the body length, and the legs one-half.



### HEAD-BODY PROPORTIONS

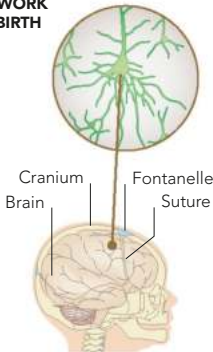
If the body's height at different ages is superimposed onto a grid, the changes in head-body proportions that take place from birth to adulthood are clearly shown. The overall growth trend is for the head to lead, growing first and fastest. Then the other regions of the body catch up: first the torso, followed by the arms, and finally the legs.

## SKULL AND BRAIN

At birth, the brain is a quarter of its adult size. It has almost its full complement of neurons, but they have yet not made many interconnections. Gaps (fontanelles) and

seams (sutures) between the skull bones allow for expansion. By two years, the brain is four-fifths of its adult size, and neurons are forging links into networks.

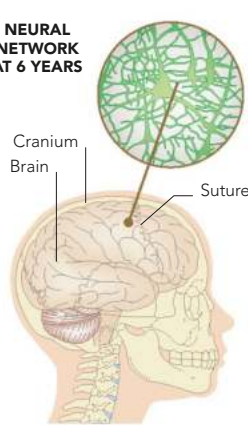
### NEURAL NETWORK AT BIRTH



### BIRTH

The cranium and brain are huge compared to the small facial bones. The neurons make limited links.

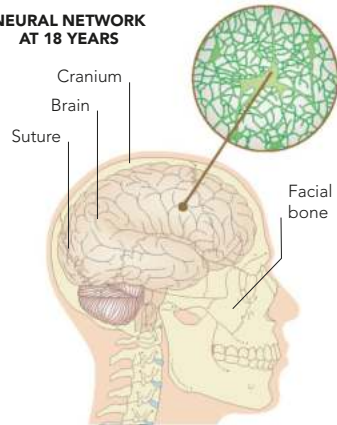
### NEURAL NETWORK AT 6 YEARS



### SIX YEARS

Cranial bones are fusing at the sutures. Neurons rapidly extend their projections and their links.

### NEURAL NETWORK AT 18 YEARS

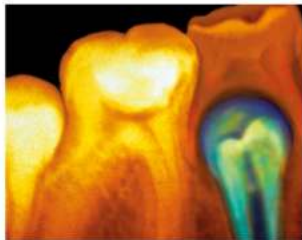


### ADULT

The cranium is solidly fused, the brain is full-sized, and new neural links are made less often.

## DENTAL DEVELOPMENT

The first set of teeth, known as the primary or deciduous dentition, erupts through the gums in a set order, from about six months into the third year. In general, apart from the canines, the teeth appear from the front to the back. However, the exact times and order vary between individuals, and occasionally a baby is born with one or more teeth. Primary teeth loosen and fall out as the adult, or permanent, dentition erupts through the gums. This usually starts at about six years of age. The set of 32 permanent teeth is complete once the third molars (known as wisdom teeth) appear in the late teens or early twenties. In some people, however, the third molars never make an appearance above the gum.

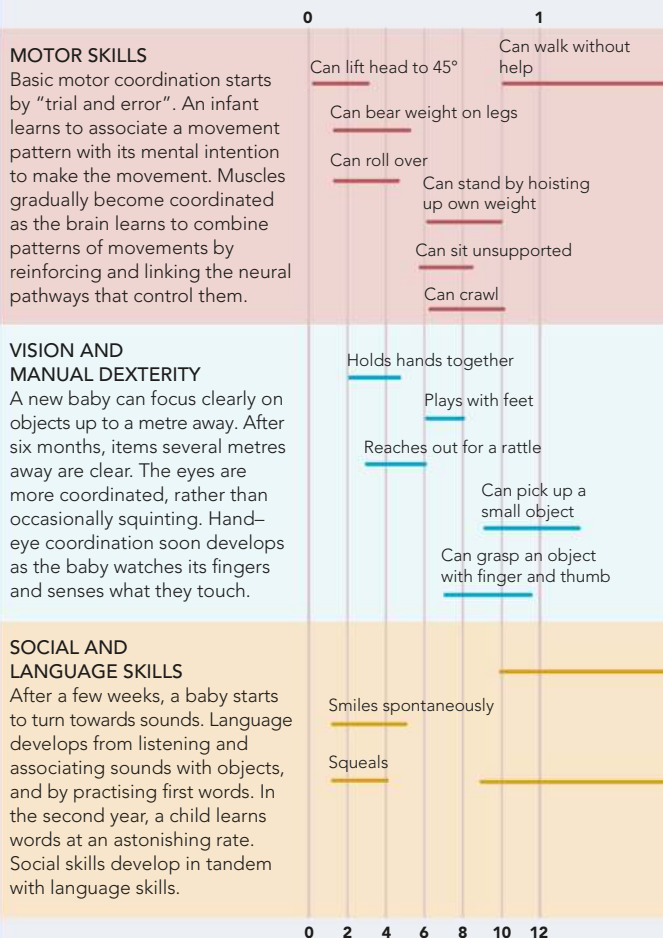


### TOOTH ERUPTION

In this coloured X-ray, a permanent, or adult, tooth (green) is shown erupting under a child's milk, or deciduous, teeth.

## STAGES OF DEVELOPMENT

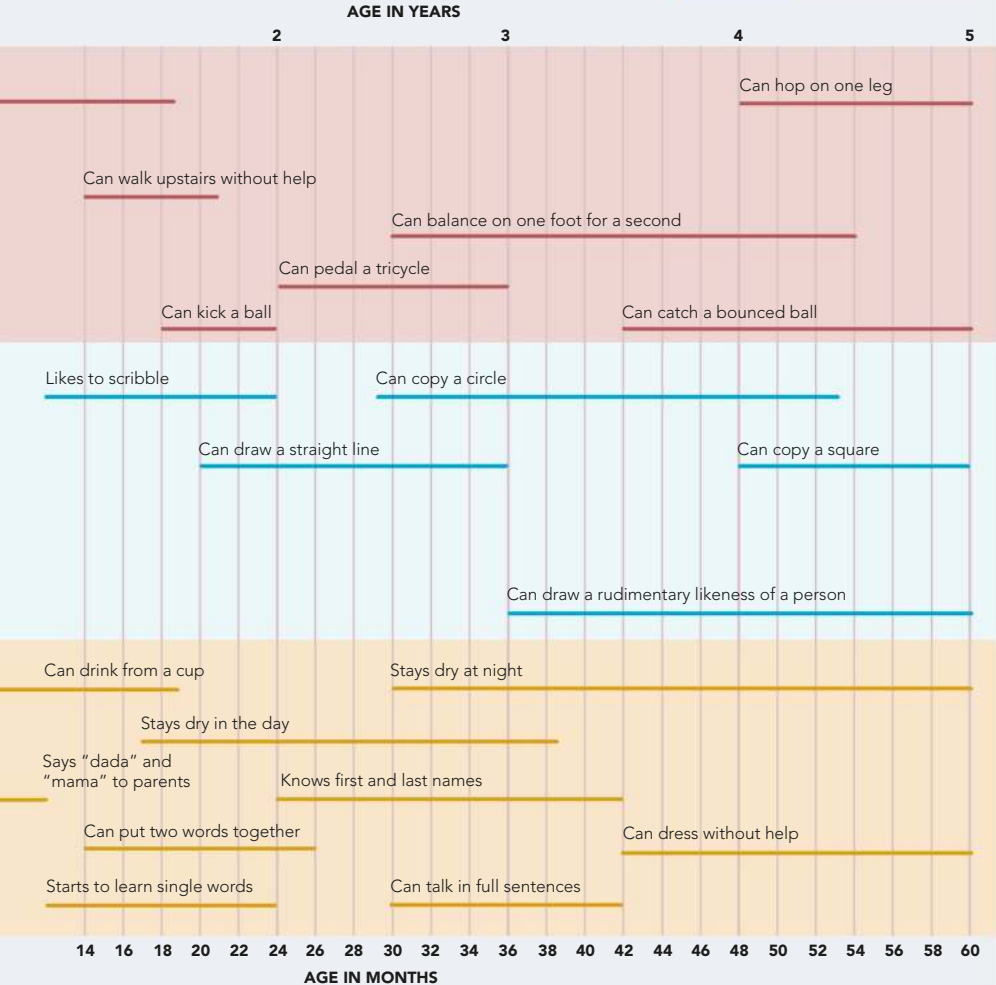
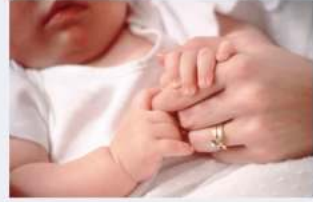Babies are born able to see, hear, and perform reflex actions, such as grasping, urination, and defecation. Gradually, the infant learns to bring these reflexes under conscious control. As the eyes develop the ability to focus clearly, the baby watches his or her hands, and learns how conscious movements formulated in the brain result in actual physical movement. During early childhood, these basic motor skills are refined further. The child also gains a range of social developmental skills, such as smiling, to elicit a response from those nearby. For most children, development takes place in a fairly





predictable sequence: for example, standing must occur before walking. However, there is great variation in the ages at which stages are reached; acquiring a skill early does not always mean the skill will improve later. Some babies and children miss stages and go straight on to the next ones.

**NEONATAL GRASP**  
A newborn's grasp, when its palm is touched, is one of the primitive reflexes, which disappear in a few months.



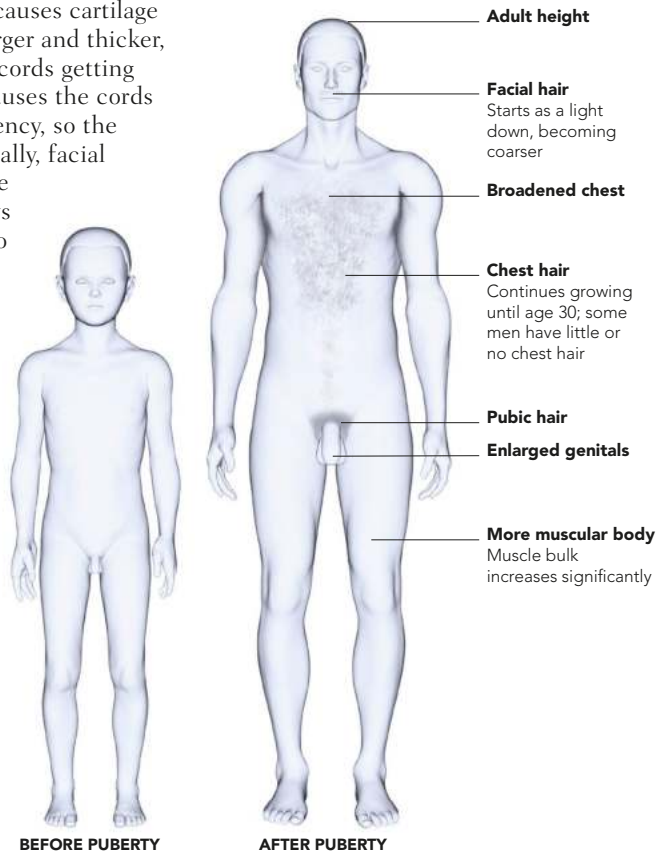
# PUBERTY

AT PUBERTY, A NUMBER OF HORMONAL CHANGES STIMULATE PHYSICAL GROWTH AND THE DEVELOPMENT OF THE SEX ORGANS. IN BOTH SEXES, EMOTIONAL, BEHAVIOURAL, AND PSYCHOLOGICAL CHANGES ALSO OCCUR.

## MALE PUBERTY

In boys, the physical changes of puberty start later than in girls, around age 12 or 13. Most show signs of development by age 14, and complete the changes of puberty by age 17 or 18. The testicles and penis get bigger first, then hair grows in the pubic area and armpits. Muscles increase in bulk, and some breast tissue might also develop. The hormone testosterone causes cartilage in the voice box to grow larger and thicker, which results in the vocal cords getting longer and thicker. This causes the cords to vibrate at a lower frequency, so the voice becomes deeper. Finally, facial hair appears, which may be accompanied by acne. Boys are more likely than girls to experience problems with perspiration and oily skin.

The sign of sexual maturation for boys is ejaculation. Although they are capable of having an erection from birth, boys only produce sperm when testosterone begins circulating in their bodies. It is then that they are able to ejaculate for the first time.



### CHANGES IN THE BODY

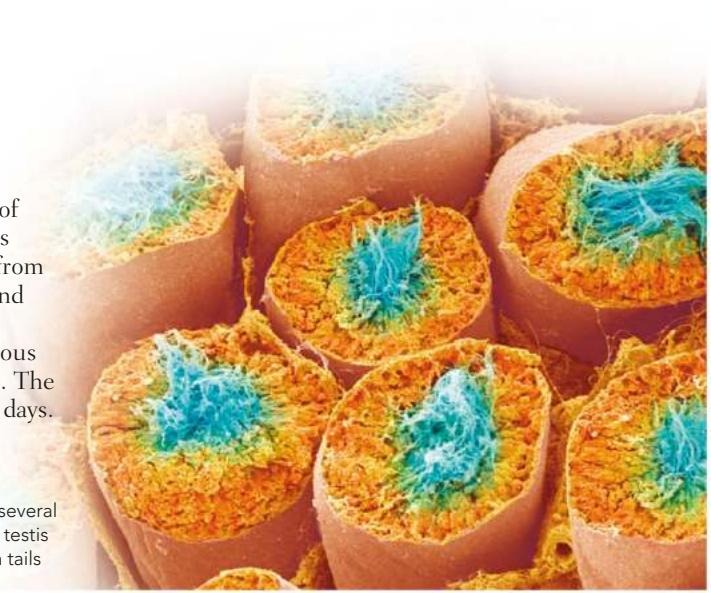
Boys start growing later than girls. Once they begin growing, however, they grow faster and for a longer period, thus attaining a greater adult height. At age 14 or 15, the average boy is taller, heavier, and stronger than an average girl and is still growing.

## SPERM PRODUCTION

Sperm develop in the seminiferous tubules of the testes. Sperm cells gradually move away from the supporting cells and mature as they pass through the seminiferous tubule and epididymis. The process takes about 74 days.

### MATURING SPERM

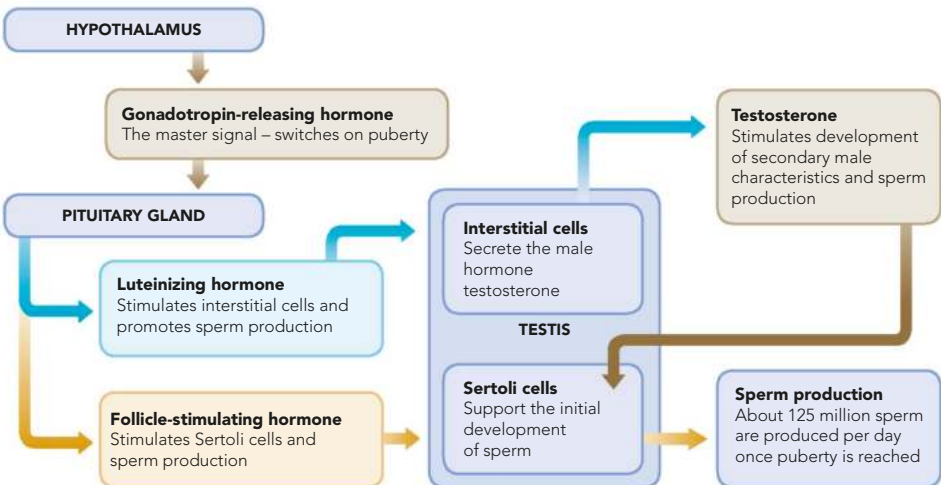
This cross-section through several seminiferous tubules in the testis shows maturing sperm with tails in the centre (blue).



## MALE HORMONE CONTROL

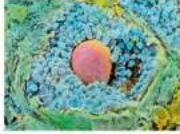Hormone production is often regulated by feedback (see p.139), when the amount of a substance controls how much of it is made. The testes, hypothalamus, and pituitary gland control production of sperm and male hormones in this way. Gonadotropin-

releasing hormone (GnRH) from the hypothalamus stimulates the pituitary to control testis function via follicle-stimulating hormone (FSH) and luteinizing hormone (LH). High levels of testosterone act on the pituitary to slow the release of LH and FSH.



## FEMALE PUBERTY

Changes to the female body are caused by the hormones oestrogen and progesterone. The first sign of puberty is the development of breasts, which starts around 10–11 years. Then hair grows in the armpits and pubic area. Leg hair thickens, and body shape



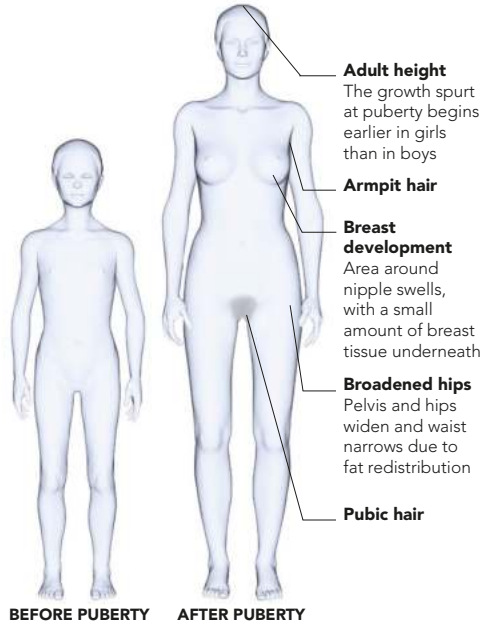
### FOLLICLE IN AN OVARY

At puberty, the ovary starts to form mature follicles each containing a single egg (red).

changes as body fat increases. Hair and skin become oily, which may cause acne. Periods tend to begin at 12 to 13 years. Girls may experience mood swings and irritability.

### CHANGES IN THE BODY

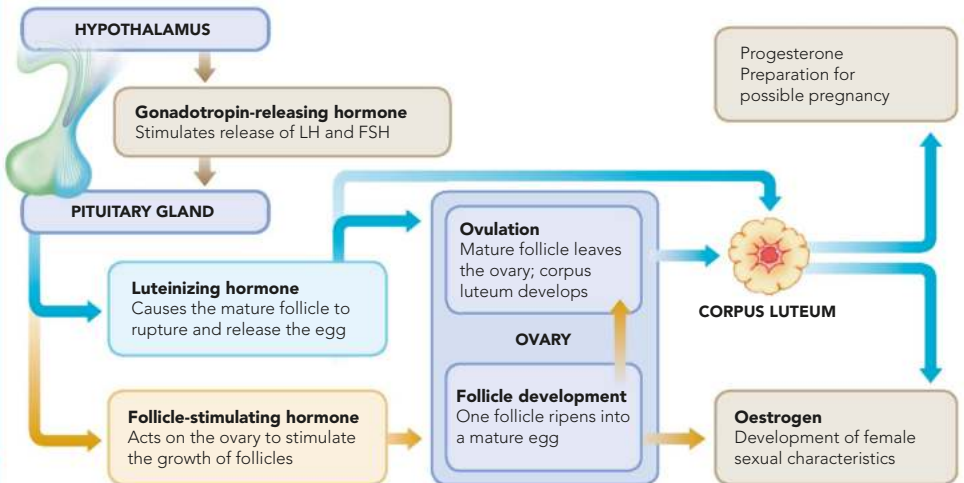
Growth rate peaks at about age 12, when girls grow up to 9cm (3½in) a year. Growth usually stops by the age of 16.



## FEMALE HORMONE CONTROL

In the menstrual cycle, the hypothalamus releases gonadotropin-releasing hormone (GnRH) to trigger the pituitary to secrete luteinizing hormone (LH) and follicle-

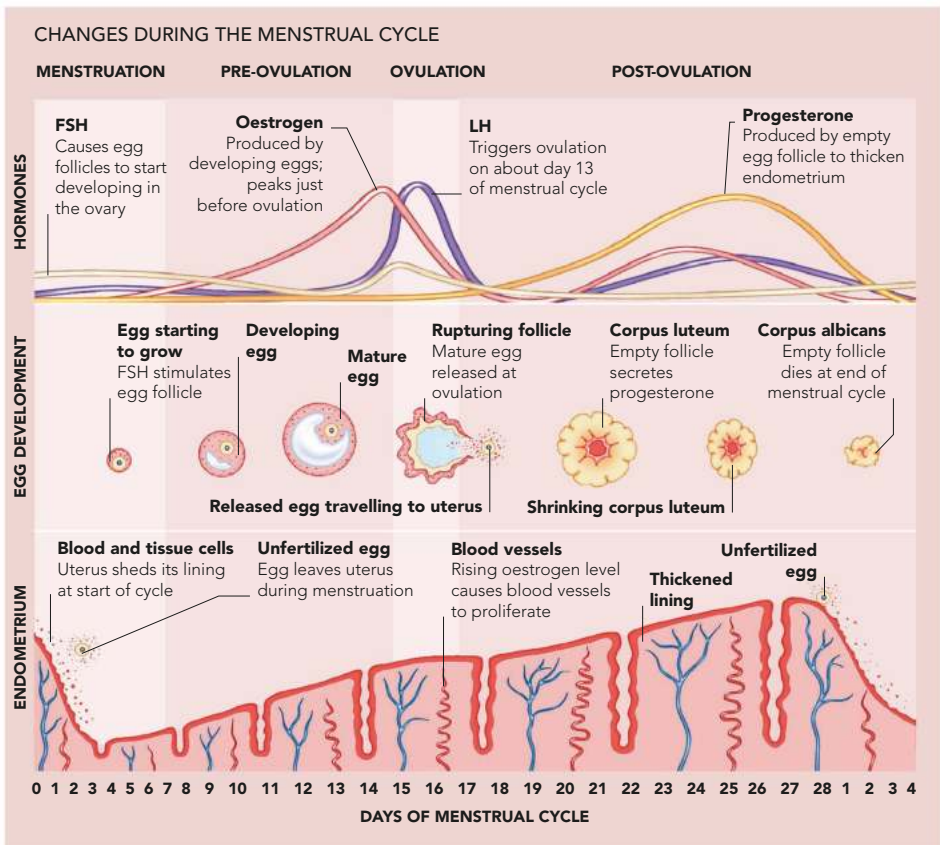
stimulating hormone (FSH). These hormones control the activity of the ovaries and female hormones, and also send feedback (see p.139) to the hypothalamus and the pituitary gland.



## THE MENSTRUAL CYCLE

For a few days each month, the lining of the uterus is shed and blood passes out through the vagina. The lining thickens again to prepare for the implantation of a fertilized egg. This is the menstrual cycle. It starts when the pituitary gland releases FSH (see opposite), which stimulates egg follicles in the ovary. The follicles secrete oestradiol, a form of oestrogen. This triggers the release of LH, which matures the egg and weakens the follicle wall, allowing the release of the mature egg (ovum). Whether the right or left ovary ovulates is entirely

random. If fertilized, the embryo is implanted into the uterine wall, and signals its presence by releasing human chorionic gonadotropin (HCG), the hormone measured in pregnancy tests. This signal maintains the corpus luteum and enables it to continue producing progesterone. In the absence of a pregnancy and without HCG, the corpus luteum dies and progesterone levels fall. Progesterone withdrawal leads to menstrual bleeding and, as FSH levels rise, a new crop of follicles is formed – the cycle begins again.



# AGEING

THE BRAIN, MUSCLES, JOINTS, EYES, AND OTHER ORGANS ALL DECLINE WITH AGE, BUT CHANGES ARE USUALLY SMALL UNTIL AFTER THE AGE OF 60. GENETICS AND LIFESTYLE ARE MAJOR CONTRIBUTORS TO A PERSON'S LIFESPAN.

## CELLULAR DETERIORATION

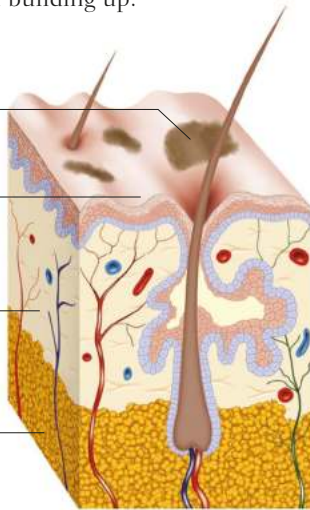
Cells divide a fixed number of times and then stop functioning properly. Connective tissue becomes increasingly stiff, making the organs, blood vessels, and airways more rigid. Changes in cell membranes impede the delivery of oxygen and nutrients and the removal of carbon dioxide and wastes, causing an increase in pigments and fatty substances inside cells. How quickly a person's cells deteriorate, and therefore how long he or she lives, is a balance between how fast things go wrong with cells and how efficiently the body functions to prevent damage from building up.

**Liver spots**  
Pigmentation patches in areas exposed to sun

**Wrinkles**  
Creased, sagging skin that gives a lined appearance

**Dermis**  
Thinner; contains fewer collagen fibres, causing reduced elastic recoil

**Fatty layer**  
Thicker relative to dermis, although may also be thinner with age



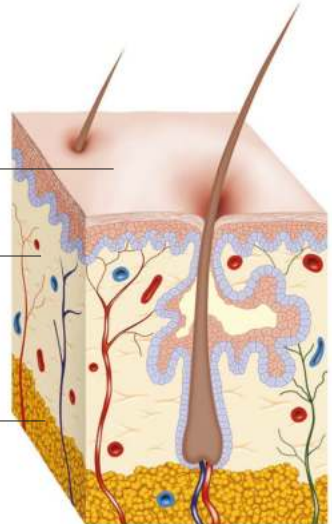
### OLDER SKIN

A thinner outer layer, and fewer elastic fibres and collagen in the deeper layers, result in skin that appears loose, with deeper creases and wrinkles.

**Epidermis**  
Thick layer confers strength

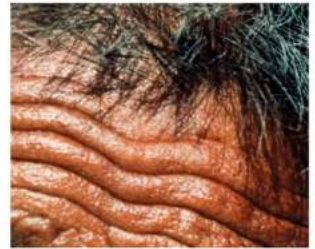**Dermis**  
Well supplied with elastic and collagen fibres

**Fatty layer**  
Gives strong support to upper skin layers



### YOUNG SKIN

A thick top layer, many elastic and collagen fibres in the deeper layers, good layers of supporting fat, and plenty of sebaceous glands producing oil all help to maintain the smoothness and suppleness of young skin.



### AGEING GRACEFULLY

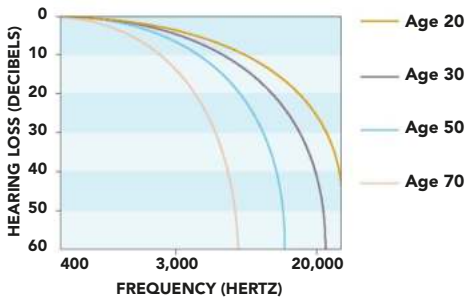
Skin wrinkling is one of the most visible signs of ageing. Creased and sagging skin, seen as wrinkles, can be predetermined by genes.

## NERVOUS SYSTEM

As people age, the brain and nervous system undergo changes, losing nerve cells. Messages are transmitted more slowly, and the senses may be affected.

## HEARING

More than half of people over 60 have hearing difficulties. Problems are caused by changes in the cochlea in the inner ear (see p.117). At birth, there are about 15,000 hair cells in the inner ear, but they gradually reduce with age, and the body is unable to generate new cells.



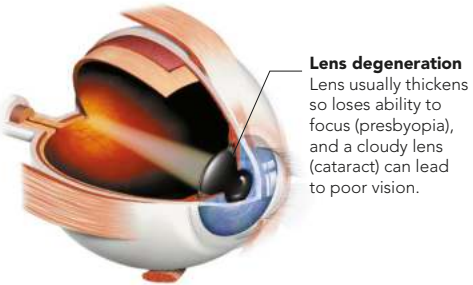
### HIGH-FREQUENCY DROP-OFF

Ageing usually causes a loss of sensitivity to sounds; they may become dull or distorted so that speech is difficult to follow. The first sign is often difficulty hearing high-frequency sounds. Hearing aids may enhance the ability to understand speech.

Reflexes may be lost, leading to problems with movement and safety. Waste products may collect in the brain tissue. Some slowing of memory and thinking occurs.

## VISION

Older people are susceptible to a number of visual disorders (see p.129). In a cataract, for example, the normally transparent lens of the eye becomes cloudy. Meanwhile, macular degeneration can affect the retina, causing detailed vision to deteriorate.

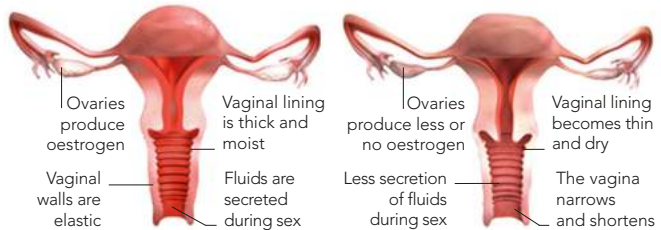


### COMMON EYE PROBLEMS

A range of eye and visual disorders, particularly those involving the ability of the lens to focus, is more likely to occur with increasing age. Presbyopia, in which people lose the ability to adjust their eyes so they can see nearby objects, is almost universal.

## THE MENOPAUSE

The menopause results from decreasing production of sex hormones. Symptoms include hot flushes, insomnia, night sweats, and headaches. Falling oestrogen levels can also cause depression. Menstruation may be irregular for several years up to the menopause, which is complete once a woman has not had a period for one year. The average age for the menopause in developed countries is 51 years.



### PREMENOPAUSAL VAGINA

Before the menopause, the vaginal lining is thick and well lubricated; the walls stretch easily and mucous fluids are secreted.

### POST MENOPAUSAL VAGINA

Declining oestrogen levels cause a reduction in vaginal mucus production; the vagina walls lose some elasticity and become thinner.

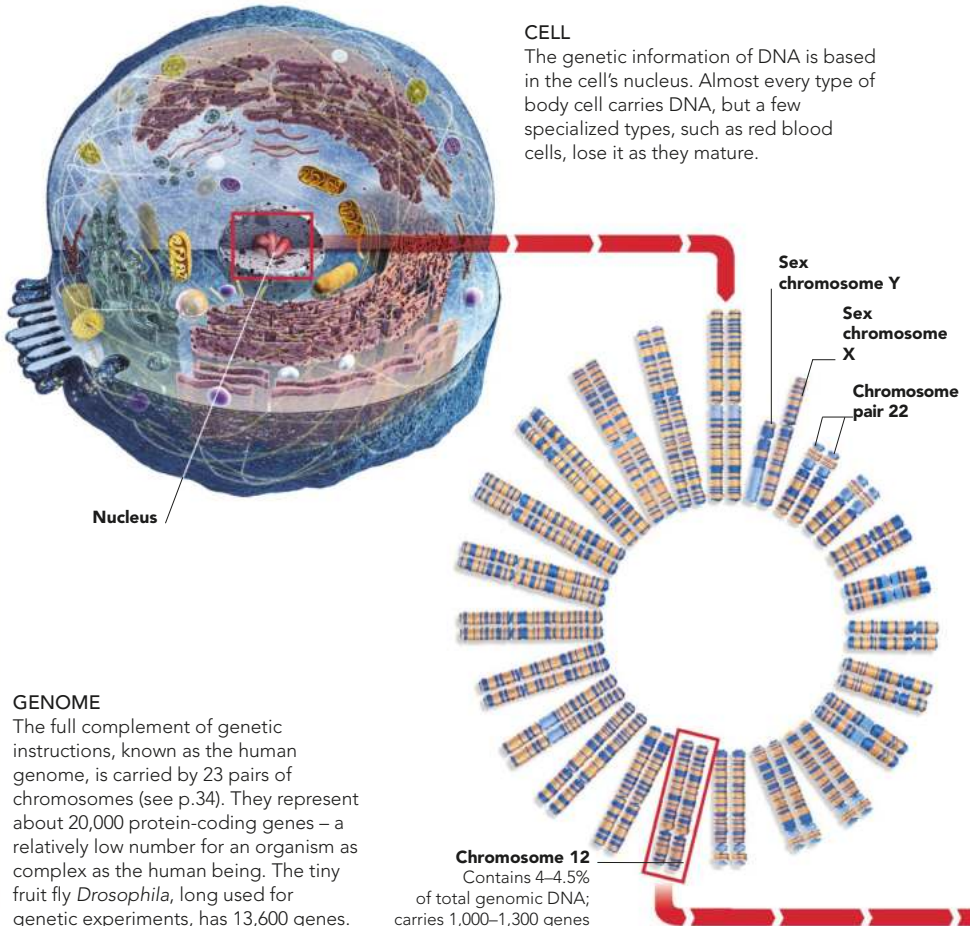
# INHERITANCE

THE PASSING OF GENETIC INFORMATION FROM PARENT TO CHILD IS KNOWN AS INHERITANCE. THE INFORMATION IS CONTAINED IN CHEMICAL CODES CARRIED BY DEOXYRIBONUCLEIC ACID (DNA) IN THE SEX CELLS (EGGS AND SPERM).

## INHERITANCE OF GENES

Everything that specifies a person is found in their genes. Each gene carries a “blueprint” to make a particular product, some of which affect appearance or biology – skin pigment, for instance. Other gene products combine

to produce a complex trait, such as athletic ability. Simple features controlled by single genes are inherited in predictable patterns (see pp.290–93). However, complex traits, such as height, are controlled by many genes.





## SEQUENCING THE GENOME

By 2003 the Human Genome Project identified all 3 billion base pairs in the full set of human DNA. In 2012 it was realized that a large portion of the DNA instructs for building RNA rather than proteins. A major technique used in DNA sequencing is gel electrophoresis. DNA is extracted from cells, purified, and broken into smaller fragments of known length by chemicals known as restriction enzymes. The DNA fragments are separated out and stained with dye, showing up as dark stripes, like bar codes (see right). Computers can read these bar codes and reveal the sequences of base pairs.



### Chromatids

Replicated twins

### CHROMOSOME

Each chromosome is an immensely long, thin molecule of DNA. When ready for cell division, it duplicates itself as a double-chromosome consisting of two identical sister chromatids, in which the DNA is coiled, looped, and folded into one generally cross-shaped structure.

### Centromere

Links chromatids; attaches to spindle during cell division

### Double helix

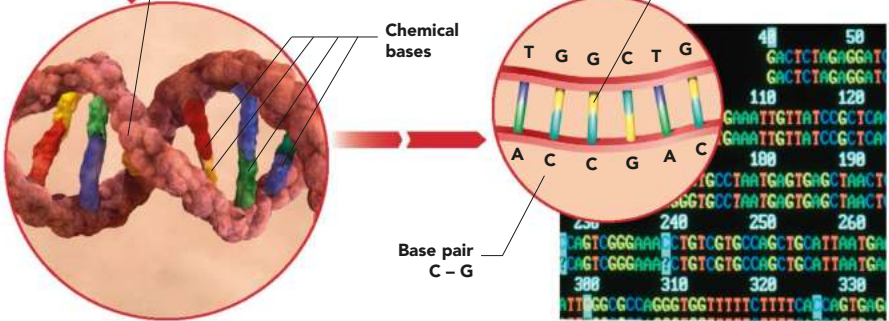
Helical structure; two backbones joined by chemical bases

### Chemical base G

Only pairs off with chemical base C; A pairs only with T

### Chemical bases

### Base pair C - G



### GENETIC CODE

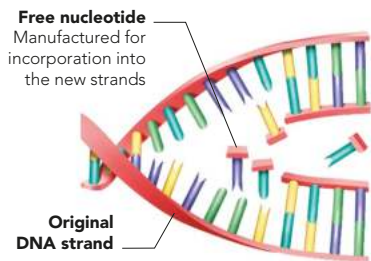
DNA consists of two spiral backbones joined by cross-rungs, which are pairs of chemical bases. The bases are adenine (A), thymine (T), guanine (G), and cytosine (C).

### GENETIC SEQUENCE

The order of base pairs on DNA represents the coded genetic information. Using chemicals to identify the bases, DNA sequencing machines can show the data on screen as lists of letters.

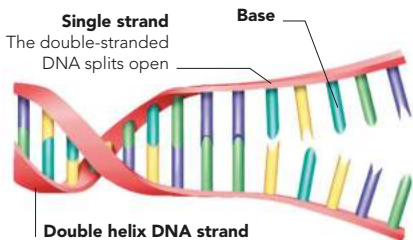
## DNA REPLICATION

Apart from carrying genetic information in chemically coded form, as its sequences of base pairs, DNA has another key feature. It can make exact copies of itself, a process known as replication, by separating the two backbone strands and the bases attached to them, at the bonds between the base pairs. Then each strand acts as a template to build a complementary partner strand. DNA replication takes place before cell division (see right).



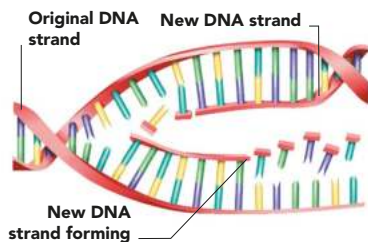
### 2 BASES JOIN

Free nucleotides, each one a base combined with a portion of DNA backbone, join to the two sets of exposed bases. This can only happen in the correct order, since A always pairs with T, and C with G.



### 1 SEPARATION

The two strands of the double helix separate at the base pair links. Each base is exposed, ready to latch onto its partner in the newly constructed strand.

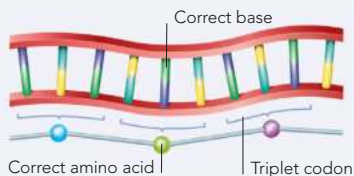


### 3 TWO STRANDS FORM

More nucleotides join, linked by a new backbone. Each strand now has a new "mirror-image" partner, giving two double helices, which are identical to each other and to the original.

## MUTATIONS

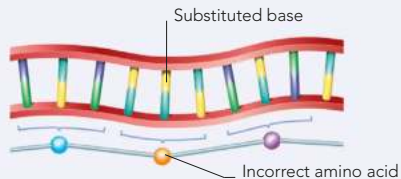
DNA replication usually works well. However, factors such as radiation or certain chemicals may cause a fault, where one or more base pairs do not copy



### NORMAL GENE

Each set of three base pairs (a triplet codon) specifies which amino acid should be added to the series of amino acids that make the normal protein for that gene.

exactly. This change is a mutation. The new base sequence may produce a different protein, which could cause a problem in the body.



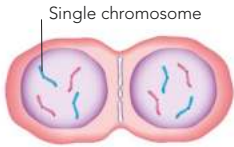
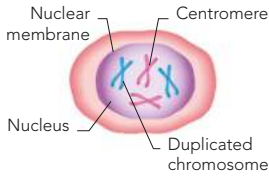
### MUTATED GENE

In a point mutation, one base pair has become altered and substituted. A different amino acid may be specified, which will disrupt the protein's eventual shape and function.

## MAKING NEW BODY CELLS

Cell division (mitosis) produces new cells for growth, maintenance, and repair. First, all the DNA replicates and the chromosomes

**1 PREPARATION**  
DNA replicates and forms double-chromosomes. The nuclear membrane breaks down.

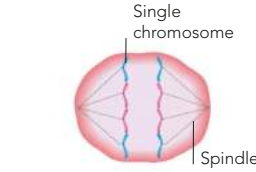
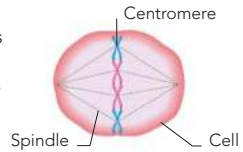


**4 SPLITTING**  
As the spindle disappears, nuclear membranes form around the two groups of chromosomes.

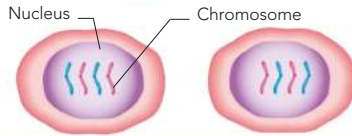
**5 OFFSPRING**  
The cytoplasm divides and the cell splits into two. Both the new cells have 23 pairs of chromosomes. Only two pairs are shown here for clarity.

are duplicated. These double-chromosomes form a line and then migrate away from each other as the cell splits in two.

**2 ALIGNMENT**  
A spindle fibre holds the centromere of each double-chromosome as it lines up in the middle of the cell.



**3 SEPARATION**  
Each centromere splits so that single chromosomes move to each end of the cell.

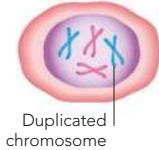


## MAKING SEX CELLS

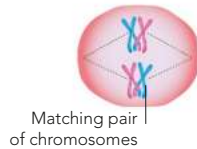
Sperm and egg cells divide by meiosis, into four sex cells (eggs or sperm) that have only one member of a chromosome pair. At

fertilization, when egg and sperm unite, the full set (23 pairs) is restored and all subsequent cell divisions are by mitosis.

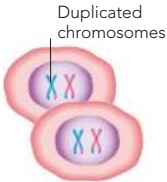
**1 PREPARATION**  
DNA strands replicate and coil up in the nucleus, forming X-shaped double-chromosomes.



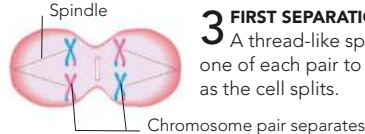
**2 PAIRING**  
The matching (homologous) pairs align, make contact, and exchange genetic material.



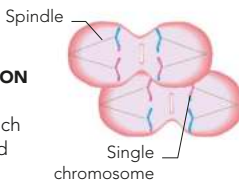
**4 TWO OFFSPRING**  
Each cell has one double-chromosome of each pair, as a random choice during separation.



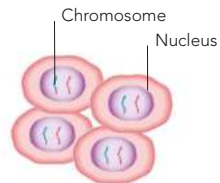
**3 FIRST SEPARATION**  
A thread-like spindle pulls one of each pair to each end as the cell splits.



**5 SECOND SEPARATION**  
The double-chromosome splits, each half moving to one end of the dividing cell.



**6 FOUR OFFSPRING**  
The four sex cells differ from each other and the parent cell in their genetic composition.



# PATTERNS OF INHERITANCE

GENES ARE PASSED FROM ONE GENERATION TO THE NEXT, IN A VAST SEQUENCE OF INHERITANCE. THEY ARE RESHUFFLED AT EACH STAGE SO THAT OFFSPRING ARE UNIQUE, BUT THERE ARE PATTERNS IN THE MODE OF INHERITANCE.

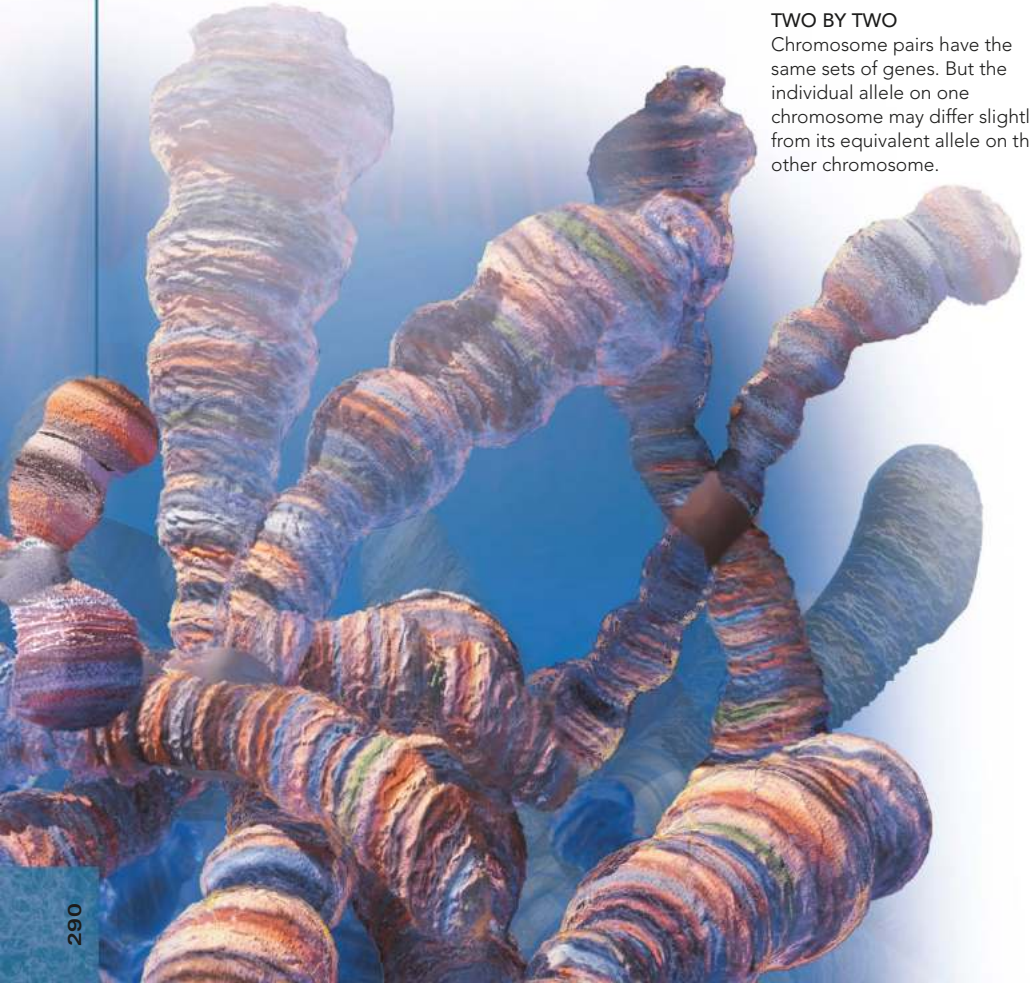
## VERSIONS OF GENES

Each cell in a body contains a double-set of genetic material, in the form of 23 pairs of chromosomes. One chromosome of each pair, and the genes on it, come from the mother. The other chromosome is from the father. So there are, in effect, two

versions of every gene in the set – one maternal and one paternal. These versions of genes are called alleles. Inheritance patterns vary depending on how these two versions interact, because they may be identical or slightly different.

### TWO BY TWO

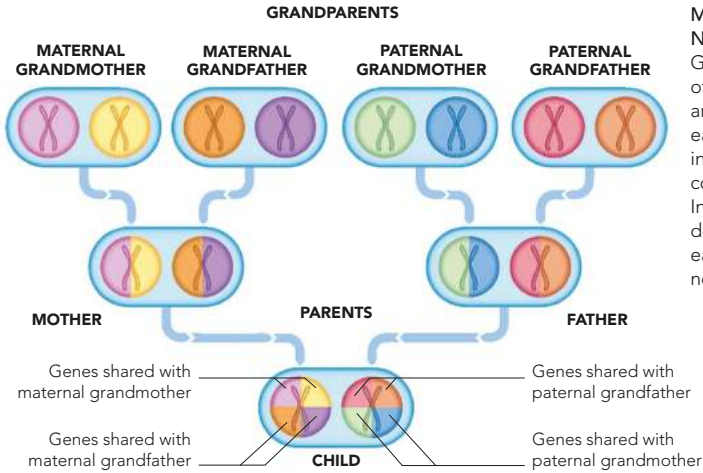
Chromosome pairs have the same sets of genes. But the individual allele on one chromosome may differ slightly from its equivalent allele on the other chromosome.



## GENERATIONAL SEQUENCE

The two versions of the genes (alleles) are mixed, or reshuffled, as they are inherited at each generation. In effect, a child inherits one-quarter of its total genes from each

grandparent. The child's inherited features strongly resemble a mixture of those from his or her parents, but the features from the grandparents appear to be less marked.

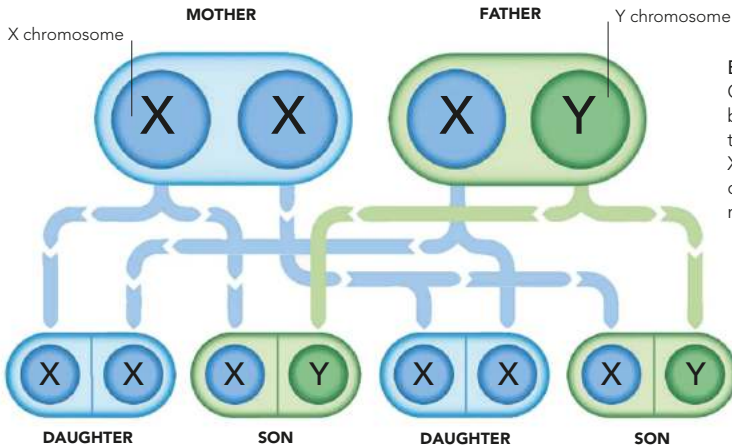


**MIXED, BUT NOT BLENDED**  
 Genes are "units" of inheritance that are shuffled at each generation into different combinations. Individual genes do not blend with each other to create new versions.

## INHERITANCE OF GENDER

Gender depends on which sex chromosome – an X or a Y – is inherited. Females have two identical Xs; males have an X and a smaller Y, with male genes. A woman's

egg cells all contain an X, whereas half a man's sperm cells contain an X and the other half a Y. The gender of offspring is always determined by the father.

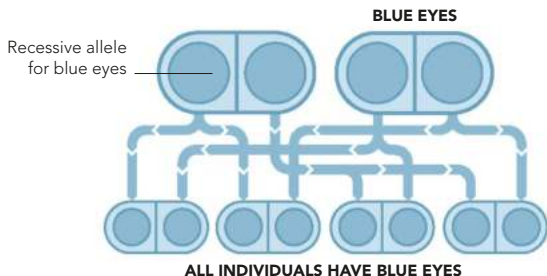


**BOY OR GIRL?**  
 Gender is determined by the inheritance of the sex chromosomes, X and Y (the other 22 chromosome pairs are not shown here).

## RECESSIVE AND DOMINANT GENES

Each gene in a cell exists in two versions, one inherited from each parent. In some cases these gene versions, or alleles, are different, and produce slightly different

results. One allele may be dominant and “overpower” the other, which is recessive. An example is eye colour, although this is not as simple as depicted below.

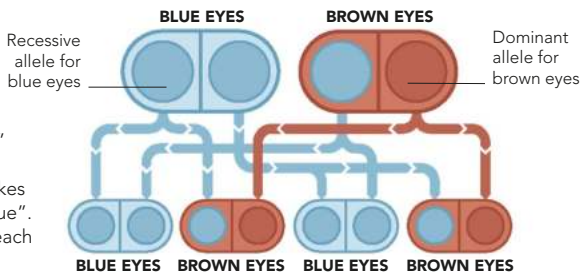


### RECESSIVE AND RECESSIVE

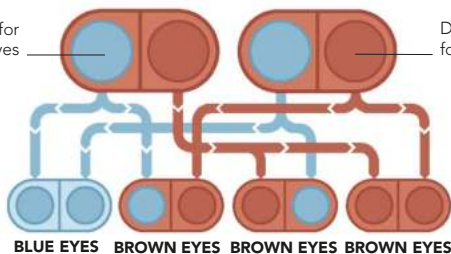
Each parent has two alleles for eye colour. Here, both parents have only “blue” alleles. When both alleles are the same, the individual is said to be “homozygous”. Their children can only inherit “blue” alleles, and so all have blue eyes.

### RECESSIVE AND MIXED

One parent has two “blue” alleles; the other, one “blue” and one “brown” allele. “Brown” is dominant and takes over when it occurs with “blue”. So the chance is 1 in 2 that each offspring has brown eyes.



Recessive allele for blue eyes



Dominant allele for brown eyes

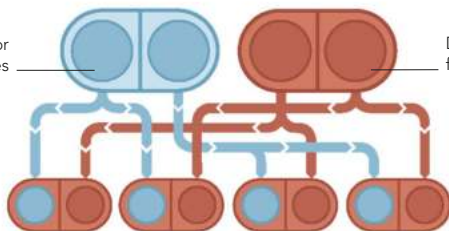
### MIXED AND MIXED

Each parent has a “brown” and a “blue” allele. Individuals who carry two different alleles are “heterozygous”. Only one of the four possible combinations leads to offspring with blue eyes.

### DOMINANT AND RECESSIVE

One parent has two “blue” alleles; the other, two “brown” alleles. The four possible combinations all produce offspring with brown eyes, but all four still carry “blue” alleles.

Recessive allele for blue eyes

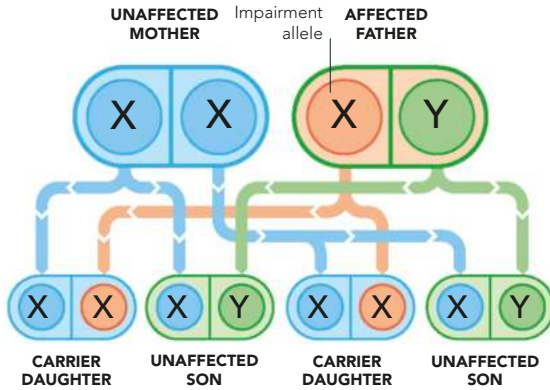


Dominant allele for brown eyes

## SEX-LINKED INHERITANCE

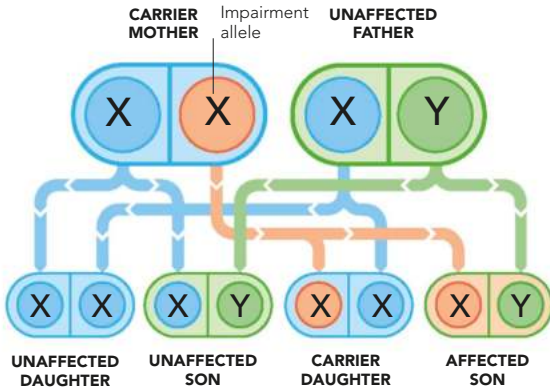
The pattern of inheritance changes when alleles for a body feature are carried on the sex chromosomes. If an allele on a man's X chromosome does not have its equal on

the Y chromosome, or vice versa, only one allele can determine the feature. For example, the problem allele for colour-impaired vision is on the X chromosome.



### COLOUR-BLIND FATHER AND UNAFFECTED MOTHER

Sex chromosomes combine in four possible ways, governed by chance. Here, any daughter will inherit the colour-impaired allele, and will be a carrier, but she also has the normal allele on her other X chromosome, to give normal vision. No sons can be affected, nor can they be carriers.



### CARRIER MOTHER AND UNAFFECTED FATHER

The four possible combinations give a one-in-four-chance each for unaffected sons and daughters. There is also a one-in-four chance a daughter is a carrier, or that a son inherits the colour-impaired allele. He has no second X chromosome and therefore no normal allele, so the result is impaired colour vision.

## MULTIPLE-GENE INHERITANCE

Some body traits follow clear single-gene inheritance patterns. However, the situation becomes more complex in two ways. First, there may not be only two alleles of a gene with a simple dominant-recessive interaction between them. There may be three alleles or more in existence in the general population, although each person can have only two of them. An example is the blood group system, with alleles for A, B, and O. Second,

a trait may be influenced by more than one gene. These two situations mean that a trait can be governed by multiple genes, and for each of these genes, by multiple alleles of the gene – added to which, the genes may interact in different ways, according to which alleles are present in each of them. In such cases, the numbers of possible combinations multiply, consequently making multi-gene inheritance exceptionally difficult to unravel.

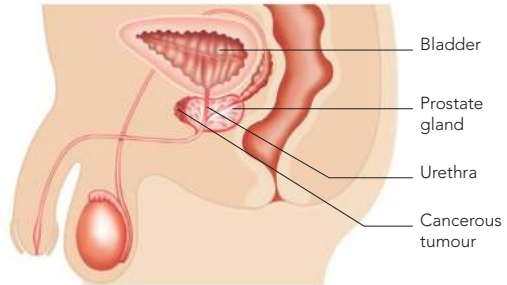
# MALE REPRODUCTIVE DISORDERS

DISORDERS AFFECTING THE EXTERNAL PARTS OF THE MALE REPRODUCTIVE TRACT ARE USUALLY APPARENT AT AN EARLY STAGE; THOSE AFFECTING INTERNAL PARTS, SUCH AS THE PROSTATE GLAND, MAY NOT BE NOTICED UNTIL LATER, WHEN SUCCESSFUL TREATMENT MAY BE HARDER TO ACHIEVE.

## PROSTATE DISORDERS

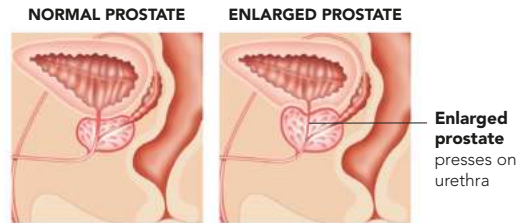
Conditions that affect the prostate gland range from inflammation and benign enlargement to serious disorders such as cancer. Prostate disorders are very common and tend to occur in the middle and later years of a man's life. Prostate cancer, although potentially life-threatening, tends to occur most commonly in elderly men, in whom it often grows slowly and may not cause symptoms. New diagnostic techniques are detecting the condition in much younger men who need treatment.

Enlargement of the prostate is extremely common and is considered part of the ageing process; most men over age 50 have it to some degree. If the enlarged gland constricts the urethra, it can cause distressing urinary symptoms, including frequent urination, delay in starting to urinate, weak flow, dribbling, and a feeling of incomplete bladder emptying. Prostatitis (see below) is a common condition, often caused by infection.



### PROSTATE CANCER

A cancerous tumour of this size on the prostate gland is unlikely to cause immediate problems, but as it grows it may press on the urethra, and may spread to other parts of the body.



### ENLARGED PROSTATE

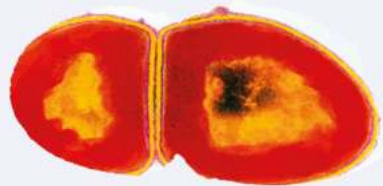
A normal prostate gland fits snugly around the urethra and abuts the bladder; enlargement can squash the urethra.

## PROSTATITIS

Inflammation of the prostate gland, or prostatitis, can be acute or chronic. The acute type is less common; severe symptoms such as fever and pain in the lower back come on suddenly, but usually clear up quickly. Chronic prostatitis features longstanding but often mild symptoms that are difficult to treat, such as groin and penis pain, pain on ejaculation, blood in semen, and painful urination. Possibly caused by a bacterial infection from the urinary tract, both types are most common in men between 30 and 50 years old.

### CAUSATIVE BACTERIUM

This electron micrograph shows the bacterium *Enterococcus faecalis*, implicated in prostatitis. It is a normal, harmless inhabitant of the human gut.





## TESTICULAR CANCER

Cancer of the testis is one of the most commonly occurring cancers in men aged between 20 and 40. Although it is curable if discovered early, the cancer can spread to lymph nodes and to other parts of the body if not treated. Symptoms of testicular cancer include a hard, painless lump in the testis; a change in the size and appearance of the testis; or a dull ache in the scrotum. There are two main types of testicular cancer, seminoma and non-seminoma. They develop from the sperm-producing cells of the testis. As early

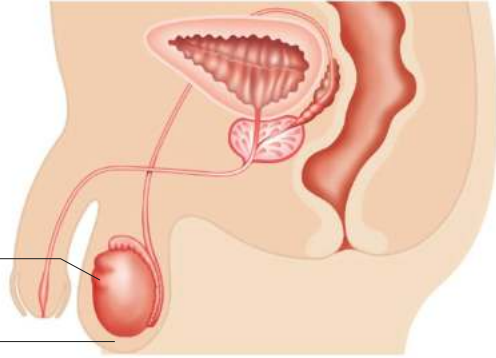
treatment of the cancer is vital and has a very high cure rate, all men should regularly examine their testes; any swellings or changes in the scrotal skin should be reported urgently. Soft lumps or painful swellings are likely to be caused by a cyst or infection, but should still be checked.

### TUMOUR ON TESTIS

A tumour of this size on the outer wall of the testis would be clearly felt through the thin outer skin and layers of the scrotum.

**Tumour**  
Tiny growth  
on the testis

**Scrotum**



## HYDROCELE

Each testis is surrounded by a double-layered membrane, which under normal conditions contains a small amount of fluid. In a hydrocele, an excessive amount of fluid forms, causing the testis to appear swollen. The condition occurs most frequently in infants and elderly people. The cause of hydrocele is not usually known, although infection, inflammation, or injury to the testis are possible triggers. A hydrocele does not usually cause any pain, but may result in a dragging sensation due to the increased size and weight of the scrotum. In younger people with hydrocele,

the condition often gets better without the need for treatment. However, if the condition is causing discomfort, the hydrocele may be surgically removed or, for those who are not fit enough for surgery, the fluid may be drained from the area using a needle and syringe.

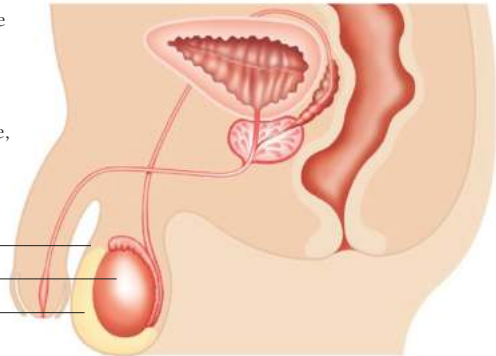
### SWOLLEN TESTIS

A hydrocele is the result of excess fluid filling the double-layered membrane that surrounds the testis; it causes the scrotum to appear swollen.

**Scrotum**

**Testis**

**Fluid**  
Fluid accumulates  
around the testis



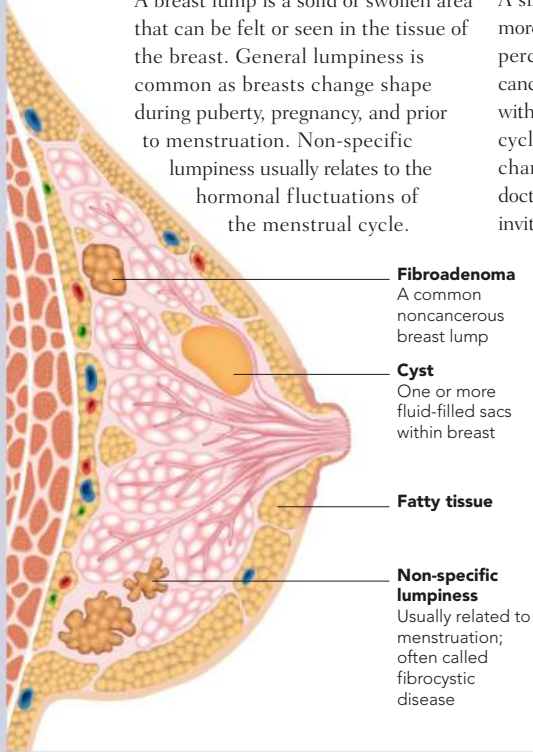
# FEMALE REPRODUCTIVE DISORDERS

MANY FEMALE REPRODUCTIVE DISORDERS ARE HARMLESS, AND SOME ARE EVEN SYMPTOMLESS. HOWEVER, WIDE HORMONAL FLUCTUATIONS AND PHYSIOLOGICAL STRESSES CAN LEAD TO MORE SERIOUS DISORDERS, INCLUDING VARIOUS TYPES OF CANCER.

## BREAST LUMPS

A breast lump is a solid or swollen area that can be felt or seen in the tissue of the breast. General lumpiness is common as breasts change shape during puberty, pregnancy, and prior to menstruation. Non-specific lumpiness usually relates to the hormonal fluctuations of the menstrual cycle.

A single lump may be an overgrown lobule, and a more defined one may be a cyst. Only a small percentage of lumps are a symptom of breast cancer. All women should familiarize themselves with the shape of their breasts during the menstrual cycle, so they can look and feel for abnormal changes, and immediately report them to their doctor. From the age of around 50, women are invited to attend regular screening.



## BREAST CANCER

Cancer of the breast is the most common female cancer. The risk increases with age, doubling every 10 years. The causes are unclear, but risk factors have been identified. Women with higher exposure to oestrogen – for example, through having an early puberty, late menopause, or no children – have a higher risk. Age is significant, with many more cases occurring over the age of 50. Faulty genes are also a known cause. A breast lump, usually painless, is often the first sign of breast cancer.

## ENDOMETRIOSIS

Endometriosis is a common condition, affecting many women of childbearing age. It can cause debilitating pain and very heavy periods; in severe cases, the condition can lead to fertility problems. The endometrium, the lining of the uterus, is shed approximately once every month as part of the menstrual cycle. Endometriosis is when small areas

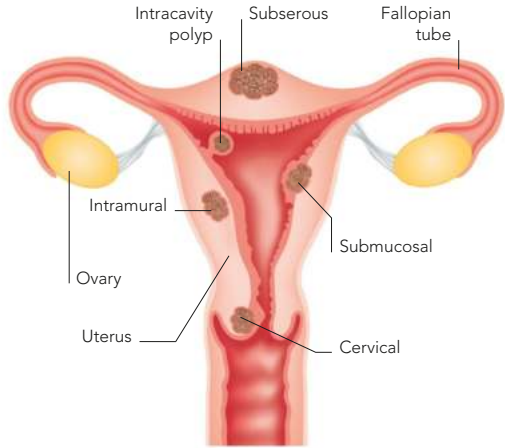
of endometrial tissue grow outside the uterus, most commonly on the ovaries and in the pelvis. These pieces of tissue respond to hormonal changes and bleed during menstruation. Since the blood cannot leave the body through the vagina, its normal exit, it irritates nearby tissues, causing pain and eventually forming scars. The cause of the disorder is unknown.

## FIBROIDS

Fibroids are very common, occurring in about one-third of women of childbearing age. They can occur singly or in groups, and can be the size of a pea or as large as a grapefruit. Small fibroids are unlikely to cause any problems. Larger ones may result in prolonged and heavy menstrual bleeding, and increasingly severe period pain. Large fibroids can distort the uterus, which may cause infertility, or put pressure on other organs, such as the bladder or rectum.

### SITES AND TYPES OF FIBROIDS

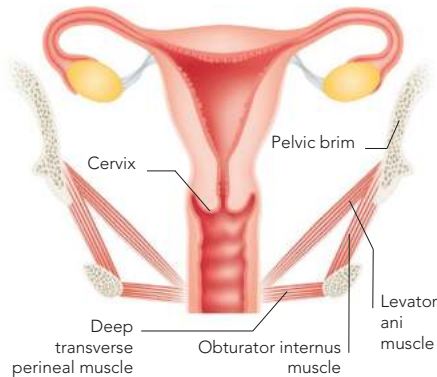
Fibroids can occur in any part of the uterus wall and are named according to their site – for example, in the cervix – or in the tissues they occupy, such as submucosal fibroids.



## PROLAPSED UTERUS

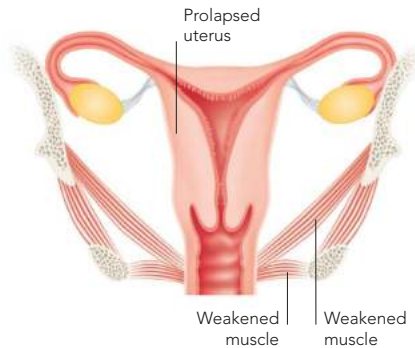
Prolapse of the uterus is more likely to occur after the menopause, when low oestrogen levels affect the ability of the ligaments to retain the uterus. Childbirth, obesity, and straining while coughing or opening the bowels are contributing factors.

The uterus protrudes down into the vagina, and in severe cases may reach as far as the vulva. Symptoms may include a feeling of fullness in the vagina, pain in the lower back, and difficulty passing urine or faeces.



### NORMAL UTERUS

The uterus is kept in place by muscles and ligaments. Regular pelvic floor exercises are important to maintain their strength and avoid prolapse.



### PROLAPSED UTERUS

In this case of uterine prolapse, the uterus has slipped down into the vagina because of weakened muscles. The wall of the vagina may also prolapse.

# SEXUALLY TRANSMITTED INFECTIONS

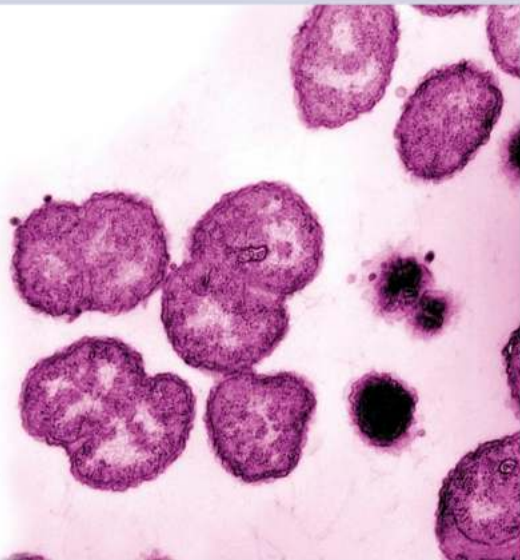
SEXUALLY TRANSMITTED INFECTIONS (STIs), ALSO KNOWN AS SEXUALLY TRANSMITTED DISEASES (STDs), ARE INFECTIONS THAT ARE PASSED FROM PERSON TO PERSON BY SEXUAL ACTIVITY. GENITAL, ANAL, AND ORAL SEX CAN ALL PASS ON AN INFECTION TO ANOTHER PERSON.

## GONORRHOEA

Although gonorrhoea tends to be more prevalent among males, it can also affect women. The main sites of infection are the urethra and, in women, the cervix. The symptoms often do not appear, but if they do they commonly include a discharge of pus from the penis or vagina and pain on urination. Women may also experience lower abdominal pain and irregular vaginal bleeding. Occasionally, the infection spreads to other parts of the body, such as the joints (via the bloodstream). If the disease is left untreated, it can cause infertility in women.

### GONORRHOEA BACTERIA

An electron micrograph of *Neisseria gonorrhoeae*, which is responsible for the STI gonorrhoea.



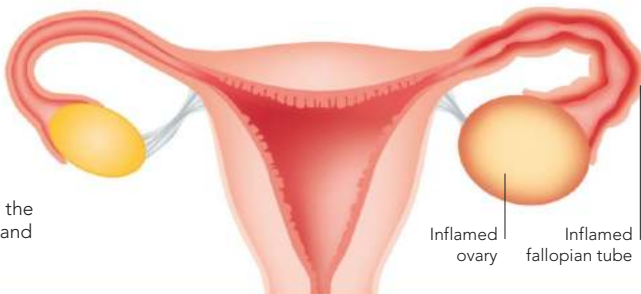## PELVIC INFLAMMATORY DISEASE (PID)

PID is a common cause of pelvic pain in young women; other possible symptoms are fever, heavy or prolonged periods, and pain during sexual intercourse. Sometimes, there are no symptoms. Usually, PID is the result of an STI such as chlamydial infection or gonorrhoea. Infection after childbirth or a pregnancy termination are also possible causes.

The inflammation starts in the vagina and spreads to the uterus and fallopian tubes. In severe cases, the ovaries are also infected. Left untreated, PID can lead to damage in the fallopian tubes, which may cause infertility and an increased risk of ectopic pregnancy (see p.302).

### INFECTED PARTS

The fallopian tube and ovary on the right of the image are inflamed and swollen as a result of PID.



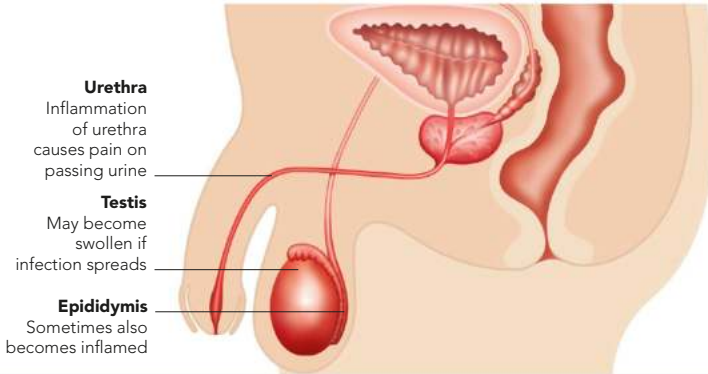
## NON-GONOCOCCAL URETHRITIS

Non-gonococcal urethritis (NGU) is one of the most common STIs affecting men. Typically, it features inflammation of the urethra, with or without a discharge of pus; inflammation and soreness at the end of the penis; and pain on passing urine, particularly when the urine is concentrated first thing in the morning. In about half of all cases, the agent responsible is *Chlamydia trachomatis*, a bacterium that can also infect women, leading

to chlamydial infection. Other possible causes of NGU include the bacterium *Ureaplasma urealyticum*; the protozoan *Trichomonas vaginalis*; the fungus *Candida albicans*; the genital warts virus (human papillomavirus, HPV); and the genital herpes viruses. It is important for both partners to seek treatment to avoid reinfecting each another. To prevent STIs, sexually active people should limit their sexual partners, and use a condom for penetrative sex.

### SYMPTOMS OF NGU

Inflammation of the urethra causes pain and soreness at the external opening on the penis, and painful urination. If the infection spreads, the epididymides and the testes may also become swollen.



## SYPHILIS

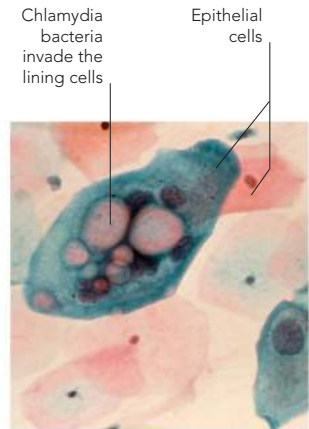
Syphilis can affect both men and women. It is caused by *Treponema pallidum*, a bacterium that enters the body via the genitals. It first affects the organs of reproduction, and spreads to other parts of the body. An infectious sore (chancre) appears on the penis or vagina, lymph nodes swell, and then a rash and wart-like patches develop on the skin. With no treatment, it can proceed to a final, possibly fatal, stage characterized by personality changes, mental illness, and nervous system disorders. Today, the disease rarely progresses to this stage.

## CHLAMYDIAL INFECTION

Chlamydial infection is a very common STI and occurs only in women. It is caused by *Chlamydia trachomatis*, which inflames the reproductive organs, and causes symptoms including vaginal discharge, a frequent urge to urinate, lower abdominal pain, and pain during intercourse. Chlamydial infection can lead to PID (see opposite), if left untreated, and may then cause infertility.

### BACTERIA IN CERVICAL SMEAR

This micrograph (x400) of a cervical smear shows *Chlamydia trachomatis* bacteria (pink cells within large blue cell).

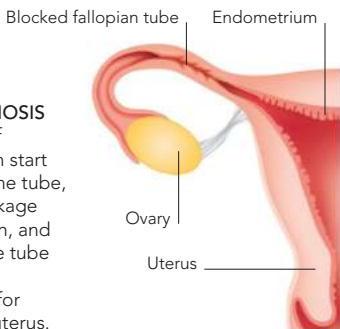


# INFERTILITY DISORDERS

IF A COUPLE IS UNABLE TO CONCEIVE AFTER A YEAR OF HAVING UNPROTECTED SEX, ONE OR BOTH PARTNERS MAY HAVE A FERTILITY PROBLEM. THE LIKELIHOOD OF FERTILITY DISORDERS INCREASES WHEN COUPLES WAIT UNTIL THEY REACH THEIR 30s OR 40s TO START A FAMILY.

## DAMAGED FALLOPIAN TUBE

The fallopian tube may become blocked as a result of endometriosis (see p.296), in which fragments of the uterine lining (endometrium) become embedded in the tube tissue. Pelvic inflammatory disease (see p.298), which is often caused by a sexually transmitted infection such as chlamydia (see p.299), may go unnoticed at the time of infection, but scarring due to the inflammation can cause problems with fertility later. An intrauterine contraceptive device can increase the risk of PID developing. Usually, only one fallopian tube is affected; if so, the woman still has a chance to conceive.



### ENDOMETRIOSIS

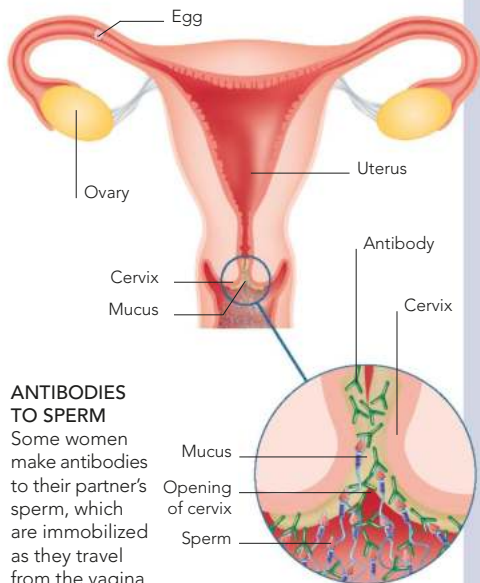
Fragments of endometrium start growing in one tube, causing blockage and distortion, and rendering the tube useless as a passageway for eggs to the uterus.

## OVULATION PROBLEMS

Any deviation from the normal ovulation pattern can cause problems with fertility. The precise problem can range from complete absence of egg release to infrequent release. Factors that can lead to ovulation problems include pituitary and thyroid gland disorders, polycystic ovary syndrome, long-term use of oral contraceptives, being very over- or underweight, stress, excessive exercise, and premature menopause.

## CERVICAL PROBLEMS

The cervix, or neck of the womb, produces mucus that is usually thick; just before ovulation, when the level of oestrogen increases, the mucus turns less viscous to allow sperm to penetrate. If oestrogen levels are low or if there is infection within the reproductive tract, the mucus may remain thick and impregnable to sperm. Another problem that may make the cervix inhospitable is that sometimes a woman's immune system forms antibodies to her partner's sperm, which will then damage or kill the sperm in the cervix. Polyps, fibroids (see p.297), narrowing (stenosis), and distortion are other problems of the cervix that may be related to infertility.




### ANTIBODIES TO SPERM

Some women make antibodies to their partner's sperm, which are immobilized as they travel from the vagina to the cervix.

## PROBLEMS WITH SPERM PRODUCTION

A man may produce sperm in low quantities, or his sperm may be deformed or unable to swim properly. All these problems reduce the likelihood that his sperm can contribute to conception. Huge numbers of sperm must be produced in order for fertilization to occur; men in whom this does not happen have a low sperm count. Microscopic examination can reveal this problem and can also look at the size, shape, and movement (motility) of individual sperm. Problems in any of these areas can cause reduced fertility. If only a small volume of semen is produced per ejaculation, fertility may also be reduced.



**NORMAL SPERM COUNT**

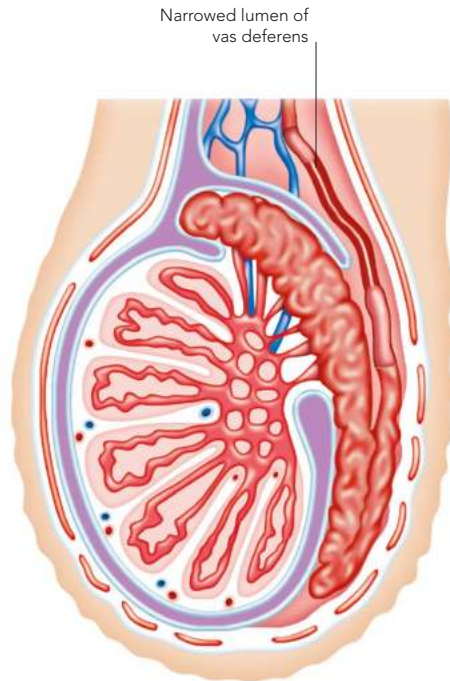
**LOW SPERM COUNT**

## EJACULATION PROBLEMS

A number of ejaculation problems prevent sperm from arriving in the vagina by the normal means, making fertilization impossible. The most common is erectile dysfunction (the difficulty in achieving or maintaining an erection). This condition may be a result of diabetes mellitus (see pp.142–43), a spinal cord disease, impaired blood flow, certain drugs, or psychological problems. Another problem, retrograde ejaculation, causes semen to flow back into the bladder because of faulty valves; this can be a complication of surgery for partial or complete removal of the prostate gland. Various treatments are available that can help to reduce erectile dysfunction, depending on the nature and cause of the problem.

## DIFFICULT PASSAGE OF SPERM

Sperm has a long and tortuous journey from its source in the testis until it is ejaculated. Narrowing, blockage, or other distortion of any of the tubes, including the epididymis and vas deferens, that make up this network can slow or completely block the passage of sperm. Causes of this problem are various, but infection of the male reproductive system is most likely. Some sexually transmitted infections (STIs, see p.298), most notably gonorrhoea, can cause inflammation of the tubes, which leaves scar tissue that can distort their structure and affect their sperm-carrying ability.



### INFLAMED VAS DEFERENS

Damage to the vas deferens, one of the tubes that transports the sperm, can prevent or slow down its passage. Infection, usually by a sexually transmitted organism, can be responsible for such damage.

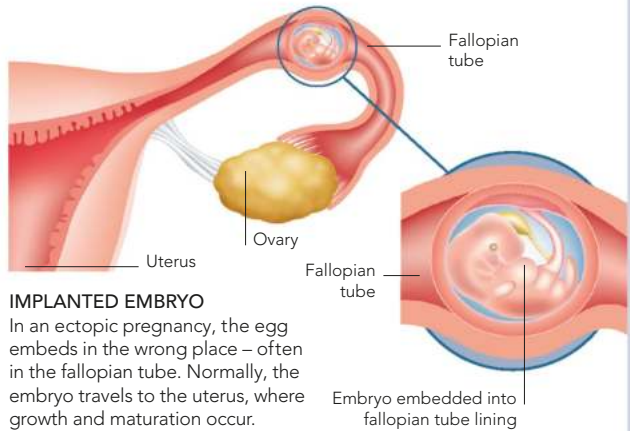
# PREGNANCY AND LABOUR DISORDERS

PROBLEMS CAN ARISE IN NORMALLY HEALTHY WOMEN DURING PREGNANCY AND LABOUR, WHICH MAY ENDANGER BOTH THE MOTHER'S AND THE BABY'S HEALTH. FEW DISORDERS OF PREGNANCY AND LABOUR HAVE ANY PERMANENT PHYSICAL EFFECT ON EITHER MOTHER OR BABY.

## ECTOPIC PREGNANCY

About 1 per cent of pregnancies are ectopic; they are more common in women under the age of 30.

The fertilized egg does not implant in the uterine lining, which is the normal place, but develops in one of the fallopian tubes, or more rarely in another area altogether. The embryo does not develop normally, and so the pregnancy usually fails. The embryo must be surgically removed to avoid rupture of the fallopian tube and to prevent internal bleeding.

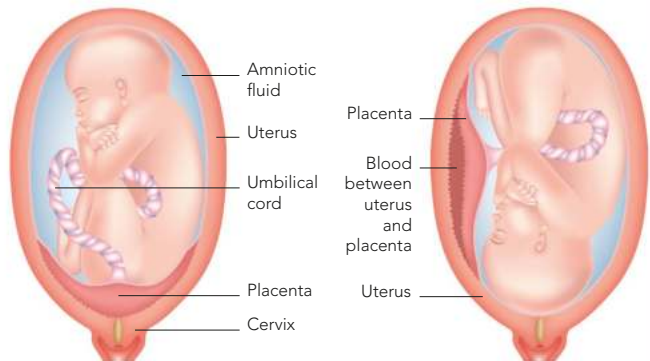


### IMPLANTED EMBRYO

In an ectopic pregnancy, the egg embeds in the wrong place – often in the fallopian tube. Normally, the embryo travels to the uterus, where growth and maturation occur.

## PLACENTAL PROBLEMS

Two main problems can affect the placenta: placenta praevia, in which the placenta covers the opening to the cervix; and placental abruption, in which the placenta separates from the uterine wall. The degree of severity in placenta praevia depends on how much of the cervix is covered. If completely covered, the condition is serious. Placental abruption usually comes on suddenly, and can threaten the fetus as essential blood supplies are compromised. Both conditions can cause vaginal bleeding, but in less severe cases, symptoms may go unnoticed.



### PLACENTA PRAEVIA

In complete placenta praevia, as shown here, the placenta entirely covers the cervix. In a less severe form, the placenta only partially obstructs the exit from the uterus.

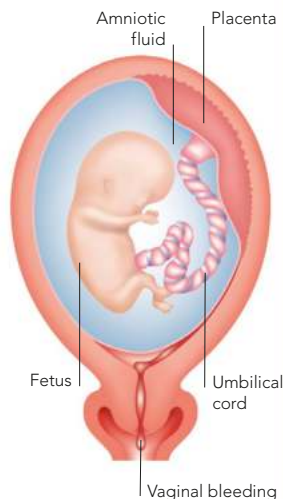
### PLACENTAL ABRUPTION

Premature separation of the placenta from the uterus may be concealed, as shown here, in which case blood collects between the uterus and placenta.



## MISCARRIAGE

Miscarriage, or spontaneous abortion, is the unintended end of a pregnancy before week 24. It is very common, occurring in 25 per cent of all pregnancies. Most miscarriages occur in the first 14 weeks of pregnancy; over half of them are due to a genetic or fetal abnormality. Later miscarriages have various causes, ranging from physical problems with the cervix or uterus to severe infection. Smoking, alcohol, or drug abuse may also be factors. If three or more occur consecutively, it is known as recurrent miscarriage.

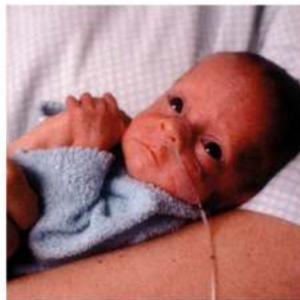

### THREATENED MISCARRIAGE

The fetus remains alive and the cervix is closed, although there is some blood loss. It may proceed to full miscarriage, when the fetus dies, or a successful birth.

## PRETERM LABOUR

Most pregnancies last for about 40 weeks, but delivery during the final three weeks is considered to be full term. Labour that occurs before 37 weeks is known as preterm and results in a premature baby. Premature labour rarely causes maternal problems, but the earlier the birth, the greater the problems encountered by the baby. The cause is not always known, but multiple births, urinary tract infection, and fetal abnormalities are known to be trigger factors. Sometimes, premature labour can be halted or delayed, giving the baby more time in the womb.

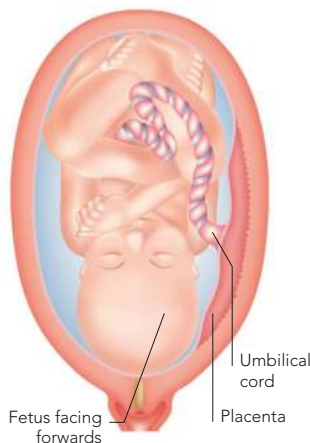


### PREMATURE BABY

This premature baby is being fed through a nasogastric tube because his sucking reflex has yet to develop and his swallowing ability is poor. Other features are his tiny size, wrinkled and yellow skin, and disproportionately large eyes.

## ABNORMAL PRESENTATION

Eighty per cent of babies adopt the normal delivery position for birth, with the head down and facing towards the mother's back. The baby usually achieves this position by about week 36. Other babies are in a position that may cause problems during labour. Breech (see p.266) and occipitoposterior positions (see right) are the most common of these abnormal presentations. In a breech birth, the baby's buttocks present first. Some presentations may allow the umbilical cord to drop through the birth canal and cause fetal distress. The cervix and vagina are more vulnerable to tears if the presentation is abnormal.



### OCCIPITOPOSTERIOR POSITION

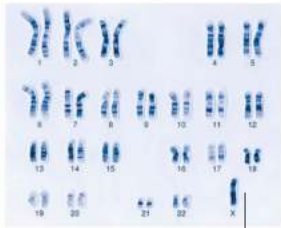
Although the baby's head is facing down, as is normal, the baby is turned 180° towards the front, instead of facing the mother's back.

# INHERITED DISORDERS

INHERITED DISORDERS ARE CAUSED BY DEFECTIVE GENES OR ABNORMAL CHROMOSOMES. IN CHROMOSOME DISORDERS, THERE IS A PROBLEM IN THE NUMBER OR STRUCTURE OF CHROMOSOMES, WHEREAS IN GENE DISORDERS, THERE IS A FAULT IN ONE OR MORE GENES.

## CHROMOSOME DISORDERS

Two-thirds of chromosome disorders are numerical – egg or sperm cells have either too many or too few chromosomes. In many cases, they result in a miscarriage. In a few exceptions, the fetus survives. The most common is Down's syndrome, in which there is an extra chromosome 21. Abnormalities in the sex chromosomes have a less severe effect on the embryo, and there may not be any obvious signs of a problem. A girl with an extra X chromosome or a boy with an extra Y chromosome will probably go unnoticed. However, a boy who is born with an extra X chromosome (XXY) will have Klinefelter's syndrome, which becomes apparent at puberty when secondary sexual characteristics fail to develop. A girl who is born with only one X chromosome will have Turner's syndrome.



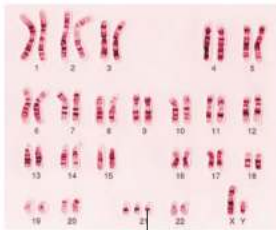Missing X chromosome

### TURNER'S SYNDROME

This chromosome set from a female shows only one X chromosome. She has Turner's syndrome, and will be short in stature and probably infertile.

### DOWN'S SYNDROME

This chromosome set from a male shows an extra chromosome 21. He has Down's syndrome, and will have a distinct physical appearance and learning difficulties.



Extra chromosome 21

## CYSTIC FIBROSIS

Cystic fibrosis is a gene disorder in which mucus glands produce abnormally thick secretions that cause repeated lung infections and problems digesting food. Weight gain is reduced, growth is slow, and life expectancy is shortened. Cystic fibrosis is caused by an abnormal gene that has to be received from each parent.

Prenatal genetic testing and genetic counselling will be offered to parents of one affected child if they want to have more.

**Lungs**  
Lung infections, constant cough, and breathlessness

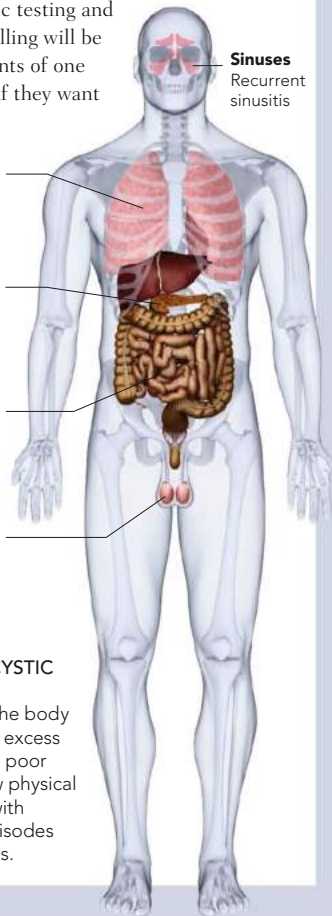
**Pancreas**  
Lack of enzymes means digestion is inefficient

**Intestines**  
Poor absorption of nutrients and intestinal blockage

**Testes**  
Infertility as vas deferens and epididymis fail to develop properly

### EFFECTS OF CYSTIC FIBROSIS

Many parts of the body are affected by excess mucus, causing poor health and slow physical development with intermittent episodes of serious illness.



# CANCER

CANCER IS NOT A SINGLE DISEASE, BUT A LARGE GROUP OF DISORDERS WITH DIFFERENT SYMPTOMS. NEARLY ALL CANCERS HAVE THE SAME BASIC CAUSE: CELLS MULTIPLY UNCONTROLLABLY BECAUSE THE NORMAL REGULATION OF THEIR DIVISION HAS BEEN DAMAGED.

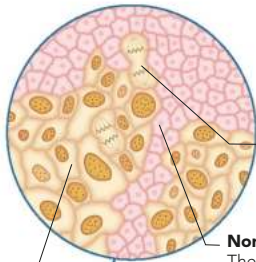
## CANCEROUS (MALIGNANT) TUMOURS

A cancerous (malignant) tumour is a mass of abnormal cells that divide excessively quickly and do not carry out the normal functions of their tissue. These cells are often irregular in size and shape, and bear little resemblance to the normal

cells from which they arose. This irregular appearance is often used to diagnose cancer during microscopic examination of a small sample of tissue taken from a tumour. The tumour gradually enlarges, crowding out normal cells, pressing on nerves, and infiltrating blood and lymph vessels. It is important to distinguish a malignant tumour from a non-malignant one, because cancerous cells can spread to other parts of the body.

### MALIGNANT TUMOUR GROWTH

A cancerous tumour grows and spreads by forcing its way between other cells and infiltrating the tissues, eventually interfering with their function.

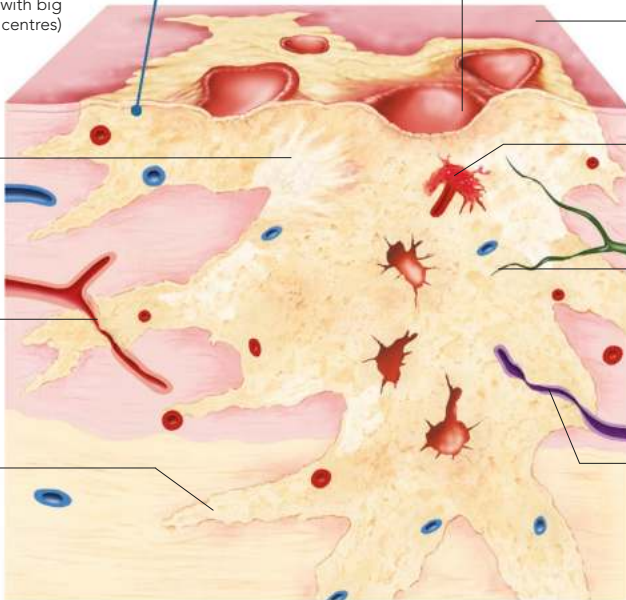


**Dividing cancer cell**  
Rapidly-dividing abnormal cells force their way between normal ones

**Normal cell**  
These remain between the cancerous cells

**Ulcerated area**  
Tumour may erode the epithelial layer to form an ulcer

**Cancerous cell**  
These are often larger than normal cells, with big nuclei (control centres)



**Epithelial layer**  
Covers and lines tissues and organs; tumours often form in this layer

**Bleeding**  
Cancerous cells disrupt and breach tiny blood vessels

**Nerve**  
Pressure on the nerves may cause the tumour to become painful to surrounding tissues

**Lymph vessel**  
Like blood vessels, lymphatic vessels provide a route for cancer cells to spread

**Calcium deposits**  
Hard deposits of calcium minerals may build up in tumours

**Blood vessel**  
Blood circulation is one major route for the spread of cancerous cells

**Tumour outgrowth**  
Cancerous cells form outgrowths that infiltrate surrounding tissues

# GLOSSARY

Terms in **bold italics** refer to other entries that appear in the glossary.

## A

### Accommodation

The process by which the eyes adjust to focus on nearby or distant objects.

### Adenoids

Clusters of lymphoid **tissue** on each side of the back of the upper part of the throat.

### Adipose tissue

**Tissue** made of specialized cells that store fatty (**lipid**) substances for energy, for protective “padding”, and to provide heat insulation.

### Allele

Form or version of a **gene**. For example, the gene for eye colour has blue and brown alleles.

### Alveolus (pl. alveoli)

One of many tiny air sacs at the ends of the airways in the lungs. Gases diffuse in and out of blood through the alveolar walls.

### Amino acid

One of about 20 kinds of building-block subunits of **protein**.

### Antibody

A soluble **protein** that attaches to body invaders, such as **bacteria**, and helps to destroy them.

### Aorta

The central and largest **artery** of the body. It arises from the left **ventricle** of the heart and supplies oxygenated blood to all other arteries except the pulmonary artery.

### Aortic valve

A triple-cusped valve at the origin of the **aorta** that allows blood to leave the left **ventricle** of the heart but prevents backward flow.

### Appendix

The wormlike, dead-ended structure attached to the large intestine. Its function, if it has one, is as yet unknown.

### Aqueous humour

The fluid filling the front chamber of the eye, between the back of the **cornea** and front of the iris and **lens**.

### Arteriole

A small terminal branch of an **artery** leading to even smaller **capillaries**, which link to the **veins**.

### Artery

An elastic, muscular-walled tube that transports blood away from the heart to other body parts.

### Atrium (pl. atria)

One of two thin-walled, upper chambers of the heart.

### Autonomic nervous system (ANS)

The portion of the nervous system controlling unconscious functions such as heartbeat and breathing.

### Axon

The long, fibre-like process of a **nerve** cell that conducts nerve impulses away from the cell body.

## B

### Bacterium (bacteria pl.)

A type of microorganism with one cell. Only a few of the many species of bacteria cause disease.

### Base

In **nucleic acids** (**DNA**, **RNA**), a nitrogen-containing chemical unit or nitrogenous base (adenine, thymine, guanine, cytosine, uracil), the order of which carries genetic information.

### Bile

A greenish-brown fluid secreted by the **liver** that is concentrated and stored in the **gallbladder**; released following food intake to help the digestion of fats.

### Biliary system

The network of **bile** vessels formed by the ducts from the **liver** and the **gallbladder**, and the gallbladder itself.

### Bone marrow

Fatty **tissue** within bone cavities that may be red or yellow. Red bone marrow produces **red blood cells**, **platelets**, and most **white blood cells**.

### Brainstem

The lower part of the brain; houses the centres that control vital functions, such as breathing and the heartbeat.

### Bronchus (pl. bronchi)

One of the larger air tubes in the lungs. Each lung has a main bronchus that branches into smaller and smaller airways.

## C

### Capillary

One of the numerous tiny blood vessels that link the smallest **arteries** and smallest **veins**.

### Cardiac

Relating to the heart.

### Cartilage

Type of connective **tissue** that is tough and resilient, and often flexible; forms some structural parts, such as the ear and nose, and lines bone ends inside joints.

### Central nervous system (CNS)

The brain and spinal cord; receives and analyses sensory data, and initiates a response.

### Cerebellum

A region of the brain located behind the **brainstem**. It is concerned with balance, posture, and the control of fine movement.

### Cerebrospinal fluid

A watery fluid that bathes the brain and spinal cord.

### Cerebrum

The largest part of the brain; made up of two cerebral hemispheres. It contains the **nerve** centres for thought, personality, the senses, and voluntary movement.

### Chromosome

A threadlike structure, present in all nucleated body cells, that carries the genetic code for the formation of the body. Chromosomes coil into “X” shapes. A normal human body has 23 pairs of chromosomes.

**Cochlea**

The coiled structure in the inner ear that contains the organ of Corti, which converts sound vibrations into **nerve** impulses for transmission to the brain.

**Collagen**

The body's most important structural **protein**, present in bones, **tendons**, **ligaments**, and other connective **tissues**.

**Colon**

The part of the large intestine that extends from the caecum to the rectum. Its main function is to conserve water by absorbing it from the bowel contents.

**Cornea**

The transparent dome at the front of the eyeball that is the eye's main focusing **lens**.

**Coronary**

A term meaning "crown". Refers to the arteries that encircle and supply the heart with blood.

**Corpus callosum**

The wide, fan-shaped band consisting of about 20 million **nerve** fibres that connects the two hemispheres of the **cerebrum**.

**Cortex**

Outer layer in various **organs**, such as the cerebral cortex (brain), **renal** cortex (**kidney**), and adrenal cortex (hormone-producing gland on top of the kidney).

**Cranial nerves**

The 12 pairs of **nerves** emerging from the brain and **brainstem**. They include the nerves for smell, sight, eye movement, facial movement and sensation, hearing, taste, and head movement.

**Cytoplasm**

Watery or jelly-like fluid that fills the bulk of a cell; it contains many **organelles**.

**D****Dermis**

The thick inner layer of skin, made of connective **tissue**; contains structures such as sweat glands.

**Diaphragm**

The dome-shaped muscular sheet that separates the chest from the abdomen. When the muscle contracts, the dome flattens, increasing chest volume and drawing air into the lungs.

**Diastole**

The period in the heartbeat cycle when all four chambers are relaxed and the heart is filling with blood. See **systole**.

**Digestive system**

The mouth, **pharynx**, **oesophagus**, stomach, and intestines. Associated **organs** are the **pancreas**, **liver**, and **gallbladder** and their ducts.

**DNA (Deoxyribonucleic acid)**

A chemical with a double-helix structure that carries genetic information in the form of the order of its paired subunits (**bases**); packaged into **chromosomes**.

**Duodenum**

The C-shaped first part of the small intestine, into which the stomach empties. Ducts from the **gallbladder**, the **liver**, and the **pancreas** all enter the duodenum.

**E****Eardrum**

The membrane separating the outer ear from the **middle ear** that vibrates in response to sound.

**Embryo**

The developing baby from conception until the eighth week of pregnancy.

**Endocrine gland**

A gland that produces **hormones** (chemical messenger substances), which are released directly into the bloodstream rather than along tubes or ducts.

**Endorphin**

A morphine-like substance produced naturally by the body in times of pain and stress, and also activated during exercise.

**Enzyme**

A **protein** that accelerates chemical reactions within cells.

**Epidermis**

The outer layer of the skin; its box-shaped cells become flatter and scaler towards the surface.

**Epiglottis**

A leaflike flap of **cartilage** located at the entrance of the **larynx**, which covers the opening of the airways during swallowing and helps to prevent food or liquid from entering the windpipe (**trachea**).

**Epithelium**

Specialized covering or lining **tissue** that forms sheets and layers around and within many **organs** and other tissues.

**Eustachian tube**

Tube connecting the back of the nose to the **middle ear** cavity; allows air pressure to equalize on either side of the eardrum.

**F****Fallopian tube**

One of the two tubes along which an **ovum** travels to the **uterus**, after release from an **ovary**; its fingerlike projections help to sweep the ovum into the tube.

**Fertilization**

The union of a sperm and an egg, after sexual intercourse or artificial insemination, or in a test tube.

**Fetus**

The developing baby from about the eighth week after **fertilization** until the time of birth. See **embryo**.

**G****Gallbladder**

The fig-shaped bag lying under the **liver**, into which **bile** secreted by the liver passes to be stored.

**Gastric juice**

Liquid produced by the stomach lining that contains hydrochloric acid and digestive **enzymes**.

**Gastrointestinal tract**

The muscular tube that extends from the mouth, through the **pharynx**, **oesophagus**, stomach, and intestines, to the rectum. Also known as the digestive tract.

**Gene**

A distinct section of a **chromosome** that is the basic unit of inheritance. Each gene consists of a segment of deoxyribonucleic acid (**DNA**) containing the code that governs the production of a specific **protein**.

**Genome**

The full set of **genes**, or hereditary information, for a living organism; the human genome consists of 20,000–25,000 genes.

**Grey matter**

The darker-coloured regions of the brain and spinal cord that comprise mainly **neuron** cell bodies as opposed to their projecting fibres, which form **white matter**.

**H****Haemoglobin**

The **protein** in **red blood cells** that combines with oxygen to carry the gas from the lungs and distribute it around the body.

**Hair follicle**

A pit on the surface of the skin from which hair grows.

**Heart valve**

One of four structures in the heart that allow the passage of blood in one direction only.

**Hepatic**

Concerning the **liver**.

**Hepatocyte**

A type of **liver** cell with many functions, including making **bile**.

**Hippocampus**

A structure in the **limbic system** in the brain concerned with learning and long-term memory.

**Hormone**

A chemical released by the **endocrine glands** and some **tissues**. Hormones act on specific receptor sites in other parts of the body.

**Hypothalamus**

A small structure located at the base of the brain, where the nervous and hormonal systems of the body interact. It is linked to the **thalamus** above and the **pituitary gland** below.

**I–K****Ileum**

The final segment of the small intestine, where most absorption of nutrients takes place.

**Kidney**

One of two bean-shaped organs in the back of the abdominal cavity that filter blood and remove wastes, particularly **urea**.

**Killer T-cells**

**White blood cells** that can destroy damaged, infected, or malignant body cells by using proteins called lymphokines.

**L****Larynx**

The structure in the neck at the top of the **trachea**, known as the voice box, that contains the **vocal cords**.

**Lens**

The internal lens of the eye, also called the crystalline lens; it fine-focuses vision by adjusting its curvature. The outer lens is called the **cornea**.

**Ligament**

A band of **tissue** consisting of **collagen** – a tough, fibrous, elastic **protein**. Ligaments support bones, mainly in and around joints.

**Limbic system**

A collection of structures in the brain that plays an important role in the automatic (involuntary) body functions, instinctive behaviour, emotions, and the sense of smell.

**Lipid**

Fatty or oily substance, insoluble in water, with varied roles in the body, including formation of **adipose tissue**, cell membranes (phospholipid), and steroid **hormones**.

**Liver**

The large **organ** in the upper right abdomen that performs vital chemical functions, including processing of nutrients from the intestines; manufacture of sugars, **proteins**, and fats; detoxification of poisons; and conversion of waste products to **urea**.

**Lobe**

A rounded projection or subdivision forming part of a larger structure such as the brain, lung, or **liver**.

**Lymphatic system**

An extensive network of transparent lymph vessels and **lymph nodes**. It returns excess **tissue** fluid to the circulation and combats infections and cancer cells.

**Lymph node**

A small, oval gland packed with **white blood cells** that acts as a barrier to the spread of infection. Nodes occur in series along lymph vessels.

**Lymphocyte**

White blood cell that is part of the immune system; it protects against **virus** infections and cancer.

**M****Medulla**

The inner part of an **organ**, such as the **kidneys** or adrenal glands. Also refers to the part of the **brainstem** lying immediately above the start of the spinal cord, just in front of the **cerebellum**.

**Meninges**

Three membrane layers around the brain and spinal cord: the pia mater on the inside, the arachnoid and the dura mater next to the skull.

**Meniscus**

A crescent-shaped, shock-absorbing pad of **cartilage** found in the knee and some other joints.

**Menopause**

The end of the reproductive period in women, when the **ovaries** have ceased their production of eggs and menstruation has stopped.

**Metabolism**

The sum of all the physical and chemical processes that take place in the body.

**Middle ear**

The air-filled cleft within the temporal bone between the **eardrum** and the outer wall of the inner ear; contains **ossicles**. Also called the tympanic cavity.

**Mitochondrion (pl. mitochondria)**

A cell *organelle* involved in the production of energy for cell functions. It contains genetic material (mitochondrial DNA) derived solely from the mother.

**Mitral valve**

The valve that lies between the left *atrium* and left *ventricle* of the heart.

**Motor neuron**

A *nerve* cell that carries the impulses to muscles that cause movement.

**Mucous membrane**

The soft, mucus-secreting epithelial layer lining the tubes and cavities of the body.

**Myocardium**

The special muscle of the heart. The fibres form a network that can contract spontaneously.

**Myofibril**

Cylindrical element within muscle cells (fibres) consisting of thinner filaments that move to produce muscle contraction.

**N****Nephron**

The *kidney's* filtering unit, consisting of a filtration capsule (glomerulus) and a series of tubules, that reabsorbs or excretes water and wastes to control fluid balance.

**Nerve**

Bundle of thread-like projections from individual *neurons* (nerve cells), held together by a fibrous sheath. Nerves carry electrical impulses to and from the brain and spinal cord and other body parts.

**Neuron**

A single *nerve* cell with long projections, the function of which is to transmit electrical impulses.

**Nociceptor**

A *nerve* ending responding to painful stimuli.

**Nucleic acid**

Deoxyribonucleic acid (*DNA*) or ribonucleic acid (*RNA*): chains of *nucleotides*, with genetic

information in the order of the bases of the *nucleotides*.

**Nucleotide**

Building-block subunit of a *nucleic acid* (*DNA*, *RNA*), consisting of a sugar, phosphate, and a nitrogen-containing *base*.

**Nucleus (pl. nuclei)**

Control centre of a cell, containing the genetic material *DNA*.

**O****Oesophagus**

The muscular tube, also known as the gullet, that connects the *pharynx* with the stomach.

**Oestrogen**

A *sex hormone* that prepares the uterine lining for an implanted, fertilized egg and stimulates the development of a female's secondary sexual characteristics.

**Olfactory nerve**

One of two *nerves* of smell that run from the olfactory bulb in the roof of the nose directly into the underside of the brain.

**Optic nerve**

One of the two *nerves* of vision. Each one has about one million nerve fibres running from the *retina* to the brain, carrying visual stimuli.

**Organ**

Discrete body part or structure with a vital function: for example, the heart, *liver*, brain, or *spleen*.

**Organelle**

A tiny structure inside a cell that has a specific role. The *nucleus*, *mitochondrion*, and ribosomes are examples.

**Ossicle**

One of three tiny bones (the incus, malleus, and stapes) of the *middle ear* that convey vibrations from the *eardrum* to the inner ear.

**Ossification**

The process of formation, renewal, and repair of bone. Most bones in the body develop from *cartilage*.

**Osteon**

The rod-shaped unit, also called a Haversian system, that is the building block of cortical bone.

**Ovary**

One of two structures lying at the end of the *fallopian tubes* on each side of the *uterus*. They store ovarian follicles, release the mature *ova*, and produce the female *sex hormones* (*oestrogen* and *progesterone*).

**Ovulation**

The release of an *ovum* from a mature follicle in the *ovary* about midway through the menstrual cycle; if not fertilized, the egg is shed during menstruation.

**Ovum (pl. ova)**

The egg cell; if *fertilization* occurs, the ovum may implant in the *uterus* and develop into an *embryo*.

**P****Pancreas**

A gland behind the stomach that secretes digestive *enzymes* and also *hormones* that regulate blood glucose levels.

**Parasympathetic nervous system**

One of the two divisions of the *autonomic nervous system*. It maintains and restores energy – for example, by slowing the rate and strength of the heartbeat or causing the liver to store glucose.

**Parathyroid glands**

Two pairs of yellowish *endocrine glands*, located behind the thyroid gland, that help to control the level of calcium in the blood.

**Parotid glands**

The large pair of salivary glands situated, one on each side, above the angles of the jaw just below and in front of the ears.

**Pelvis**

The basin-like ring of bones to which the lower end of the *spine* is attached and with which the thigh bones articulate. The term also refers to the general lower abdominal area.

**Pericardium**

The layers of membrane surrounding the heart. The outer fibrous sac encloses the

heart and the roots of the major blood vessels emerging from it. The inner layer attaches to the heart wall.

### Periosteum

The tough **tissue** that coats all bone surfaces except joints and from which new bone can be formed; contains blood and lymphatic vessels and **nerves**.

### Peripheral nervous system

All the **nerves** that fan out from the brain and spinal cord, linking these parts with the rest of the body. The system consists of **cranial nerves** and **spinal nerves**.

### Peristalsis

A coordinated succession of contractions and relaxations of the muscular wall of a tubular structure, such as the intestines, that moves the contents along.

### Peritoneum

The double-layered membrane that lines the inner wall of the abdomen. The peritoneum covers and partly supports the abdominal **organs**. It also secretes a fluid that lubricates the movement of the intestines.

### Phagocyte

A **white blood cell** or similar cell that surrounds and engulfs unwanted matter, such as invading microbes and cellular debris.

### Pharynx

The passage leading down from the back of the nose and the mouth to the **oesophagus**; it consists of the nasopharynx, the oropharynx, and the laryngopharynx.

### Pituitary gland

A pea-sized gland hanging from the underside of the brain. The pituitary secretes **hormones** that control many other glands in the body, and is regulated by the **hypothalamus**.

### Placenta

The disc-shaped **organ** that forms in the **uterus** during pregnancy. It links the blood supplies of the mother and baby via the **umbilical cord** and nourishes the growing baby.

### Plasma

The fluid part of the blood from which all cells have been removed; it

mostly water, but contains some **proteins**, salts, and various nutrients, including glucose.

### Platelet

Tiny fragment of a type of large cell manufactured in bone marrow and known as a megakaryocyte. Platelets are present in large numbers in the blood and are vital for blood clotting.

### Pleura

A double-layered membrane, the inner layer of which covers the lung while the outer layer lines the chest cavity. A layer of fluid lubricates and enables movement between the two.

### Progesterone

A female **sex hormone** secreted by the **ovaries** and **placenta** that allows the **uterus** to receive and retain a fertilized egg.

### Prostaglandins

A group of fatty acids, made in the body, that have various functions and influence some hormones.

### Prostate gland

A male accessory sex gland situated at the base of the bladder and opening into the **urethra**. It secretes some of the fluid in semen.

### Protein

Huge molecule composed of chains of **amino acids**; the basis of many structural materials (keratin, **collagen**), **enzymes**, and **antibodies**.

### Pulmonary artery

The large **artery** that conveys deoxygenated blood from the right **ventricle** of the heart to the lungs to be reoxygenated.

## R

### Red blood cells

Biconcave, disc-shaped cells, without **nuclei**, that contain **haemoglobin**. There are 4–5 million red cells in 1 millilitre ( $\frac{1}{500}$  pints) of blood.

### Renal

Relating to the **kidneys**.

### Respiration

1. Bodily movements of breathing.  
2. Gas exchange of oxygen for carbon dioxide in the lungs. 3. Similar

gas exchange in the **tissues** (cellular respiration). 4. Breakdown of molecules such as glucose to release their energy for cellular functions.

### Retina

A light-sensitive layer lining the inside of the back of the eye; it converts optical images to **nerve** impulses, which travel to the brain via the **optic nerve**.

### RNA

Ribonucleic acid, a substance present in cells; different forms carry out various functions, including the transfer of genetic information and manufacture of **proteins**.

## S

### Saliva

A watery fluid secreted into the mouth by the salivary glands to aid chewing, tasting, and digestion.

### Sex hormones

Steroid substances, including **testosterone** in males and **oestrogen** and **progesterone** in females, that bring about the development of bodily sexual characteristics. Sex hormones also regulate sperm and egg cell production and the menstrual cycle.

### Sphincter

A muscle ring, or local thickening of the muscle coat, surrounding an opening in the body, such as the anus or the **urethra**.

### Spinal nerves

The 31 pairs of combined motor and sensory **nerves** that emerge from and enter the spinal cord.

### Spine

The column of 33 ring-like bones, called **vertebrae**, that divides into seven cervical vertebrae, 12 thoracic vertebrae, five lumbar vertebrae, and the fused vertebrae of the sacrum and coccyx.

### Spleen

A lymphatic **organ**, situated on the upper left of the abdomen, that destroys worn-out **red blood cells**, filters out impurities from the blood, and helps to fight infection.

### Stem cell

Generalized type of cell, usually fast-dividing, with the potential to



become many different kinds of specialized cells.

### Sympathetic nervous system

One of the two divisions of the **autonomic nervous system**. It prepares the body for action – for example, by constricting blood vessels in the intestines and skin, widening the pupils of the eyes, and increasing the heart rate.

### Synapse

The junction between two **nerve** cells, or between a **nerve** cell and a muscle fibre or a gland. Chemical messengers are passed across a synapse to produce a response in a target cell.

### Synovial fluid

Thin, slippery, lubricating fluid within a joint.

### Synovial joint

A mobile joint with a membrane that produces a lubricating fluid.

### Systole

The period in the heartbeat cycle during which first the **atria** and then the **ventricles** contract to force blood out of the heart. See **diastole**.

## T

### Taste bud

A spherical nest of receptor cells found mainly on the tongue; each bud responds most strongly to a sweet, salty, sour, or bitter flavour.

### Tendon

A strong band of **collagen** fibres that joins muscle to bone and transmits the pull caused by muscle contraction.

### Testis (pl. testes)

One of a pair of the sperm- and **hormone**-producing sex glands in the scrotum.

### Testosterone

The principal male **sex hormone**; produced in the **testis** and in small amounts in the adrenal gland on top of the kidney, and in the **ovary**.

### Thalamus

A mass of **grey matter** found deep in the brain, on top of the **brainstem**. The thalamus receives and processes sensory information.

### Thorax

The part of the trunk between the neck and the abdomen that contains the heart and the lungs.

### Tissue

Body structure made of similar cells that perform one main function; types include muscle and connective tissue.

### Tonsils

Oval masses of lymphoid tissue on the back of the throat. They help to protect against childhood infections as they attack microorganisms that enter through the nose and mouth.

### Trachea

Also known as the windpipe. A muscular tube lined with **mucous membrane** and reinforced by about 20 rings of **cartilage**.

## U

### Umbilical cord

The structure that connects the **placenta** to the **fetus**. It provides the immunological, nutritional, and hormonal link with the mother.

### Urea

A waste product of the breakdown of **proteins**; the nitrogen-containing component of urine.

### Ureter

Tube through which urine passes from each **kidney** to the bladder.

### Urethra

The tube that carries urine from the bladder to the exterior; much longer in the male than in the female.

### Urinary tract

The system that forms and excretes urine; made up of the **kidneys**, **ureters**, bladder, and **urethra**.

### Uterus

A hollow muscular structure in which the **fetus** grows until birth.

## V

### Vagina

The muscular passage from the **uterus** to the outside of the body; it stretches during sexual intercourse and childbirth.

### Vagus nerves

The tenth pair of **cranial nerves**; helps to control automatic functions such as heartbeat and digestion.

### Vas deferens

One of a pair of tubes that lead from the **testes**; each tube carries sperm, which mix with fluid before entering the **urethra**.

### Vein

A thin-walled blood vessel that returns blood at low pressure from body **organs** and **tissues** to the heart.

### Vena cava

One of the two large **veins**, the superior and inferior vena cavae, that empty into the right **atrium** of the heart.

### Ventricle

A chamber or compartment, usually fluid-filled. Examples include two **cardiac** ventricles in the heart and four cerebral ventricles in the brain.

### Vertebra (pl. vertebrae)

One of the 33 bones of the vertebral column (**spine**).

### Virus

The tiniest form of infectious microorganism (germ). It takes over a cell to produce copies of itself.

### Vocal cords

One of two sheets of **mucous membrane** stretched across the inside of the **larynx** that vibrate to produce voice sounds when air passes between them.

## W-Z

### White blood cell

Any of the colourless blood cells that play various roles in the immune system.

### White matter

**Nerve tissue** in the brain and spinal cord formed mainly of the projecting fibres, or **axons**, of **neurons** (nerve cells).

### Zygote

The single cell produced when an **ovum** is fertilized by a sperm; it contains the genetic material (**DNA**) for a new person.

## INDEX

Page numbers in **bold** type indicate main references.

## A

abortion, spontaneous 303  
 abscesses 126, 195  
 Achilles tendon 67, 75  
 acids, digestion 228  
 acne 189, 280  
 acromegaly 140  
 "Adam's apple" 171  
 adenine 30, 31, 287  
 adenoids 192  
 adipose cells 27, 37  
 adrenal glands 133, 134, 136, 138  
 adrenocorticotropic hormone (ACTH) 134, 138  
 afterbirth *see* placenta  
 ageing 128, 129, **284-5**  
**AIDS 209**  
 air, breathing 162, 168-70, 217  
 airway *see* bronchi; trachea  
 alcohol, liver disease 236  
 alleles, genes 290-1, 292-3  
 allergies 173, 188, **208**  
 alveoli 164, 167  
   emphysema 175  
   gas exchange 162, 164, 166  
 Alzheimer's disease 125  
 amine hormones 139  
 amino acids 233  
   digestion 229, 230, 231  
   manufacture of 32  
 amniotic fluid 264  
 ampulla, balance 119, 223, 229, 259  
 amygdala 94, 111  
 amylase 215, 229  
 anabolism 233  
 anatomy 10-11  
   *see also individual organs and systems*  
 androgens 133, 137  
 angina 156  
 angiography 12  
 ankle 44, **55**, 59  
 antibiotics, resistance to 205  
 antibodies 148, 172, 196, 197  
   allergic response 208  
   in colostrum 273  
   fertility problems 300  
   immunization 208  
 antidiuretic hormone (ADH) 135  
 antigens 196, 197, 208  
 anus 212, 213, 227  
 aorta 150, 151, 153  
 appendix 213, 225  
 arachnoid 88, 98, 100  
 areola, nipples 259  
 arms: blood vessels 146  
   bones 40  
   elbow joint 44  
   lymphatic system 192  
   muscles 64, 66  
   nervous system 78  
 arrhythmia, heart 159  
 arteries 146, 149  
   in brain 86

coronary arteries 150, 153  
 coronary heart disease 156  
 imaging 12, 13  
 in newborn baby 275  
 pulmonary artery 151  
 respiratory system 163  
 thrombosis 158  
 arterioles 179  
 arthritis **60-1**  
 articular cartilage 46  
 asthma 173  
 astrocytes 83  
 atherosclerosis 156, 157  
 athlete's foot 207  
 atria, heart 151, 152, 154  
 atrial fibrillation 159  
 atriopeptin 132  
 atrioventricular valves, heart 152  
 autoimmune disorders 61, 141, 142  
 autonomic nervous system (ANS) 78, **106-9**  
 axons, neurons 80, 82, 85

## B

B-lymphocytes 172, 194, 196-7  
 babies: birth **268-71**  
   blood circulation 275  
   gender 291  
   growth and development **276-9**  
   newborn **272, 274-5**  
   premature 303  
 bacilli 204  
 back: muscles 66, 68  
   *see also spine*  
 bacteria **204-5**  
   antibiotics 205  
   digestive disorders 234, 235  
   gut flora 193, 204, 224  
   inflammatory response 198-201  
   prostatitis 294  
   sexually transmitted infections 298-9  
   urinary tract infections 248  
 balance **119**  
 ball-and-socket joints 45  
 basal ganglia 92, 109  
 bases, DNA 30, 32, 287, 288  
 basophils 194  
 bicarbonate, digestive system 232  
 biceps muscles 73  
 bile 213, 219, 220, 223, 229  
 bile duct 220  
 binocular vision 122  
 bipolar neurons 82  
 birth **268-71**  
   disorders **303**  
   preparing for **266-7**  
 bladder: anatomy 242, 243  
   cystitis 248  
   epithelial cells 184  
   incontinence 249  
 blastocyst 260, 261, 263  
 bleeding: in brain 124  
   menstrual cycle 283  
 blood 21, **148**  
   cardiovascular system 146  
   clotting 148  
   heartbeat **154-5**  
   hormones in 20, 132  
   plasma 21  
   respiratory system 163, 167  
   urine production 247  
 blood cells 27, 37  
   liver functions 220  
   production in bone marrow 42  
   *see also red blood cells; white blood cells*  
 blood clots: embolism 124, 158  
   heart attack 156  
   inflammatory response 201  
   skin repair 180  
   thrombosis 124, 158  
 blood groups, genetics 293  
 blood pressure, hypertension 159  
 blood sugar *see* glucose  
 blood vessels **149**  
   ageing 284  
   in brain 86  
   cardiovascular system 146  
   cerebrovascular disorders **124**  
   embolism 158  
   in fetus 265, 274  
   heart 150, 151  
   imaging 12, 13  
   kidneys 244, 246  
   liver 220, 222  
   lungs 153  
   menstrual cycle 283  
   in newborn baby 275  
   in skin 178, 179, 183  
   temperature regulation 181  
   vasodilation 201  
   *see also arteries; capillaries; veins*  
 body fat: cells 27, 35, 37  
   obesity 143  
   subcutaneous fat 179  
 body hair, puberty 280, 282  
 body temperature, regulation 23, 181  
 bone marrow 42, 43  
 bones 19, **38-61**  
   ankle and foot **55**  
   cells 42  
   disorders **56-8**  
   in ear 49, 116, 118  
   fractures 56-7  
   growth 42, 134, 276  
   imaging 12  
   joints **44-7**  
   as levers 72  
   ligaments 55  
   in newborn baby 272  
   osteoporosis 56, 58  
   pelvis **53**  
   repair 57  
   ribcage **52**  
   shapes 41  
   skeleton 14, **40-1**  
   skull **48-9**  
   spine **50-1**  
   structure **42-3**  
   tendons 72  
   tissue 37  
   wrist and hand **54**  
 Bowman's capsule 244, 246, 247  
 boys: gender 291  
   puberty 280-1

- brain 78, **86–97**  
 ageing 285  
 anatomy 86–7  
 autonomic nervous system 108  
 blood supply 86  
 cranial nerves **102–3**  
 disorders **124–6**  
 growth and development 277  
 infections **126**  
 information processing **20**  
 memories, thoughts, and emotions **110–11**  
 nerve damage 83  
 primitive brain **94–5**  
 protection 88  
 scanning 13  
 sense of taste and smell 113  
 sense of touch 115  
 sleep cycles 97, 138  
 stroke 157  
 structures 86–7, **90–1**  
 tissues 36  
 vision 120, 122
- brainstem 87, 90, 93, 96  
 breastbone 40, 52  
 breast-feeding 273  
 breasts 259  
 disorders 296  
 milk production 135  
 in pregnancy 265  
 in puberty 282
- breathing **166–70**, 217, 272  
 see also respiratory system
- bronchi 162–5  
 bronchioles 162–5, 167, 173  
 bronchitis 173, 175
- C**
- caecum 224, 225, 232  
 calcium 42, 58, 137  
 cancer **305**  
 breast 296  
 colorectal 239  
 lung 174  
 prostate 294  
 skin 12, 187  
 testicular 295
- Candida albicans* 207, 209, 299  
 canine teeth 216, 278  
 capillaries 146, 149  
 lymphatic system 192, 193  
 in skin 179  
 vasodilation 201
- carbohydrates 229, 232, 233  
 carbon dioxide: ageing 284  
 in blood 21  
 cardiovascular system 146  
 gas exchange 164, **166–7**
- cardiac muscle 67  
 angina 157  
 heart attack 156  
 heartbeat 155
- cardiac skeleton 150  
 cardiovascular system 15, **144–59**  
 anatomy **146–7**  
 blood and blood vessels **148–9**  
 disorders **156–9**  
 heart **150–1**  
 heartbeat **154–5**  
 homeostasis 23
- in newborn baby 275  
 carpal bones 40, 44, 54  
 carpal tunnel syndrome 75  
 cartilage 43  
 bone development 42, 276  
 cells 36  
 ears 116  
 intervertebral discs 50  
 joints 44, 46, 47  
 larynx 171  
 in newborn baby 272  
 osteoarthritis 60  
 ribcage 52  
 torn cartilage 59
- catabolism 233  
 cataracts, eyes 285  
 cells 10, **24–37**  
 ageing 284  
 anatomy 27  
 blood 148, 194  
 bone 42  
 cancer 305  
 cell membrane 26, 27, 28  
 cellular respiration 166  
 development of embryo 260–3  
 division 289  
 DNA **30–1**, 286  
 egg cells 256  
 epithelial tissues 184  
 genetic control 35  
 growth, renewal, and repair 233  
 inflammatory response 198–201  
 muscle 70  
 neurons 80–1  
 sex cells 289  
 skin renewal 178  
 sperm 252  
 tissues 36–7  
 types **27**
- central nervous system (CNS) 78  
 centriole, cells 26  
 cerebellum 86, 87, 90–1, 109  
 cerebral cortex 90, 92, 109, 113  
 cerebrospinal fluid (CSF) 83  
 brain 88, 89, 91  
 spinal cord 98, 100
- cerebrovascular disorders **124**  
 cerebrum 86, 87, 90–1, 92  
 cervical vertebrae 41, 44, 51  
 cervix 257, 264  
 birth 270  
 fertility problems 300  
 menopause 285  
 placenta praevia 302  
 preparation for birth 267, 268–9
- chemotaxis 201  
 chest: breathing 168–70  
 muscles 64, 66  
 nervous system 78
- children: growth and development **276–9**  
 puberty **280–3**
- chlamydia 298, 299  
 chloride, digestive system 232  
 choking 217  
 cholesterol: atherosclerosis 157  
 in blood 148  
 in colon 232  
 gallstones 238
- chondrocytes 36, 43  
 chromosomes: cell division 289
- disorders **304**  
 DNA 30–1, 33  
 fertilization of egg 289  
 and gender 291  
 genome **34–5**, 286–7  
 patterns of inheritance 290–1  
 sex cells 289
- chronic obstructive pulmonary disease (COPD) 175  
 chyme 219, 224, 228, 229  
 cilia 28, 184, 198, 260  
 circle of Willis 86  
 circulatory system see cardiovascular system
- cirrhosis, liver 236, 237  
 clavicle 40, 45  
 clitoris 257, 258  
 clots see blood clots  
 cocci 204  
 coccyx 41, 50, 51, 53  
 cochlea 116–18, 128, 285  
 cold, common 172  
 cold sores 188  
 collagen 44, 55, 284  
 collarbone 40  
 colon 213, **224–7**, 232, 239  
 clostrum 273  
 colour: colour blindness 293  
 eyes 33, 292  
 skin pigmentation 187
- columnar cells 184  
 communication: facial expressions 68  
 see also speech
- compact bone 42, 43  
 complement system, immune system 196–7  
 computerized tomography (CT) 13  
 conception 260, 289  
 cone cells, retina 120  
 conjunctiva, eye 121  
 connective tissue 36, 37  
 ageing 284  
 cartilage 43  
 joints 46  
 tendons 72
- contractions, labour 267–70  
 cornea 120, 121, 129, 185  
 coronary arteries 150, 153  
 coronary heart disease **156**  
 coronary veins 150  
 corpus callosum 87, 92  
 corpus luteum 258, 283  
 cortex, brain 110, 111  
 coughing 171, 217  
 cranial nerves **102–3**, 113  
 cranium 48, 277  
 cuboidal cells 185  
 cystic fibrosis 304  
 cystitis 248  
 cysts 189, 296  
 cytoplasm 21, 26, 29  
 cytosine 30, 31, 287  
 cytoskeleton, cells 26
- D**
- deafness 128, 285  
 defecation 227  
 defences: immune system **194–209**  
 skin and hair **186–7**  
 delivery, birth **270–1**

dementia 125  
 dendrites 80, 85  
 dentine 216  
 dermatomes 105  
 dermis 36, 37  
   ageing 284  
   skin structure 178, 179  
   touch sensors 182, 183  
 diabetes mellitus 142–3  
 diabetic nephropathy 248  
 diaphragm 163  
   breathing 168–9, 170  
   hiatus hernia 235  
 diet, nutrients **232–3**  
 digestive system 17, 24, **210–39**  
   anatomy **212–13**  
   digestion **228–31**  
   disorders **234–9**  
   homeostasis 23  
   hormones 133  
   immune system 193  
   large intestine **224–7**  
   liver **220–3**  
   mouth and throat **214–17**  
   nutrients and metabolism **232–3**  
   stomach and small intestine **218–19**  
 diphtheria 205  
 disc prolapse 57  
 diseases: bacteria 204–5  
   cancer **305**  
   imaging the body **12–13**  
   immunization 208  
   lymphatic system 192  
   sexually transmitted infections **298–9**  
   see also *individual diseases*  
 diverticular disease 239  
 DMARDs 61  
 DNA **30–5**  
   in bacteria 204  
   genome **34**, 286–7  
   mitochondrial DNA 35  
   mutations 288  
   non-coding and “junk” DNA 34  
   replication 288  
   in viruses 202, 209  
 dominant genes 292–3  
 Down’s syndrome 304  
 dreams 97  
 duodenum 218–9, 223  
   digestion 229  
   functions 219  
   ulcers 234  
 dura mater 88, 98, 100

## E

ear drum 117, 118, 128  
 ears **116–19**  
   ageing 285  
   balance 119  
   bones 49, 116, 118  
   disorders **128**  
 ectopic pregnancy 302  
 eczema 188  
 egg cells (ova) 27, 256  
   ectopic pregnancy 302  
   fertilization 260, 289  
   and inheritance of gender 291  
   meiosis 289  
   ovulation 258, 283, 300

ejaculation 252, 254, 255  
   fertility problems 301  
   puberty 280  
 elastic cartilage 36, 43  
 elbow 44, 73  
 electrical signals: heartbeat 13, 155, 159  
   nerve impulses 20, **84–5**  
 electrocardiography (ECG) 13  
 electron microscopy 12  
 ellipsoidal joints 45  
 embolism 124, 158  
 embryo 256, **260–3**  
   cells 35  
   ectopic pregnancy 302  
   see also fetus  
 embryonic disc 262  
 emotions **110–11**  
 emphysema 175  
 enamel, teeth 216  
 endocrine system 15, **130–43**  
   glands **132–3**  
   hormonal action **138–9**  
   hormonal disorders **140–3**  
 endometrium 256, 261, 265  
 endometriosis 296, 300  
 menstrual cycle 296  
 endoplasmic reticulum, cells 26, 29  
 endoscopy 13  
 energy 233  
 enzymes 32  
   digestive system 23, 24, 193, 213,  
     228–30  
   gut flora 224  
   heart attack 156  
   pancreatic 223  
   in saliva 215  
   in stomach 218  
 eosinophils 194  
 epidermis 183  
   ageing 284  
   defensive function 186–7  
   skin structure 178, 179  
 epididymis 252, 253, 301  
 epiglottis 36, 212, 214  
   in coughing 171  
   in swallowing 162, 217  
 epithelium 27, 35, 36, **184–5**  
   digestion 219, 231  
   inflammatory response 198  
   lining of mouth 214  
 equilibrium **23**  
 erythropoietin 133  
 Eustachian tube 116, 128  
 exhalation, breathing 52, 64, 66,  
   169, 170  
 expressions, facial 68, 102  
 extracellular fluid 21, 200  
 eyebrows 69, 186  
 eyelashes 186  
 eyes **120–3**  
   ageing 285  
   colour 33, 292  
   colour blindness 293  
   development of 278–9  
   disorders **129**  
   epithelium 184–5  
   eyelids 69, 123  
   muscles 121, 123  
   optic nerve 103  
   tears 123, 193

## F

face: bones 48  
   expressions 68, 102  
   hair 280  
   muscles **68–9**  
 facet joints, spine 50  
 faeces 212, 224, 226, 227  
   diverticular disease 239  
   fibre in 233  
   in newborn baby 272  
 fallopian tubes 28, 256  
   conception in 260  
   ectopic pregnancy 302  
   fertility problems 300  
   lining 257  
   pelvic inflammatory disease 298, 300  
 false ribs 52  
 fascicles: muscles 70  
   nerves 82  
 fat see body fat  
 fats, digestion 223, 229, 232, 233  
 fatty acids 233  
 feedback systems: homeostasis 23  
   hormones 138, 139, 281, 282  
 feet: athlete’s foot 207  
   bones 41, **55**  
   muscles 65, 67  
   in newborn baby 272  
   skin 186  
   tendons 72  
   toenails 180, 186  
   walking 55  
   X-rays 12  
 female reproductive system **256–9**  
   disorders **296–7**  
   infertility **300**  
   puberty 282  
 femur 41, 47, 272  
 fertility disorders **300–1**  
 fertilization 260, 289  
 fetus 256  
   blood circulation 274  
   development of **264–5**  
   miscarriage 303  
   multiple pregnancy 266  
   position in uterus 266, 303  
 fibre 232  
 fibrinogen 148  
 fibrocartilage 43  
 fibroids, uterus 297  
 fibula 41  
 fingers 54, 180, 182  
 flatworms 207  
 flu 173  
 fluids **21**  
 flukes 207  
 fluoroscopy 12  
 focusing problems, eyes 129  
 folic acid 127  
 follicle-stimulating hormone (FSH) 134,  
   258, 281, 282–3  
 follicles: hair 178, 179, 181, 182  
   ovaries 258, 282, 283  
 fontanelles, skull 272, 277  
 food: digestive system **210–39**  
   nutrients **232–3**  
 foot see feet  
 fractures 56–7, 58  
 fungi 207

## G

galactose 230  
 gallbladder 213, 221, 223  
 gallstones 238  
 gametes 256  
 gamma rays, scanning the body 13  
 gammaglobulins 196  
 ganglia, nerves 104, 106  
 gas exchange 164, **166–7**  
 gastric juices 193, 218  
 gastric pits, stomach 228  
 gastritis 235  
 gender, inheritance of 291  
 genes **33–5**  
   bacteria 204  
   control of cells 35  
   disorders **304**  
   dominant genes 292–3  
   genome **34–5**  
   inheritance **286–93**  
   mitochondrial genes 35  
   mutations 288  
   patterns of inheritance 290–1  
   recessive genes 292–3  
   sex cells 289  
   viruses 202  
 genitals: female 258  
   male 252–3  
   in newborn baby 272  
   in puberty 280, 282  
   sexually transmitted infections 298–9  
 genome **34–5**, 286–7  
 germs *see* bacteria; microorganisms;  
   viruses  
 girls: gender 291  
   puberty 282–3  
 glands **130–43**  
   hormones **134–7**  
   lymph nodes 192, 194  
   male reproductive system 254  
   *see also individual glands*  
 glandular cells 185  
 glaucoma 129  
 glial cells 36, 80, 83  
 gliding joints 44–5  
 globulins 148  
 glomerulonephritis 248  
 glomerulus, kidneys 244, 246, 247  
 gottis, vocal cords 171  
 glucagon 133, 136, 142  
 glucose: in blood 148  
   cellular respiration 166  
   diabetes mellitus 142–3  
   digestive system 231, 233  
   hormone control 136  
   liver functions 220  
 glue ear 128  
 glycerol 233  
 glycogen 220, 233  
 goblet cells 184, 260  
 goitre 141  
 Golgi complex, cells 26, 29  
 gonorrhoea 298  
 goose pimples 181  
 Graves' disease 141  
 greenstick fracture 56  
 grey matter: brain 36, 92–3  
   spinal cord 98, 99  
 growth, babies **276–9**  
 growth hormone (GH) 20, 134, 140

growth plates, bones 42, 276  
 guanine 30, 31, 287  
 gullet 212  
 gums 216  
 gut flora 193, 204, 224

## H

haemoglobin 148, 167  
 haemorrhage, brain 124  
 hair 16  
   defensive functions 186  
   growth 181  
   in puberty 280, 282  
   temperature regulation 181  
 hair cells, ears 118, 119  
 hair follicles 178, 179, 181, 182, 189  
 hamstring muscles 67, 74  
 hands: bones 41, **54**, 276  
   carpal tunnel syndrome 75  
   dexterity 278  
   fingernails 180  
   joints 44, 45  
   muscles 65  
   rheumatoid arthritis 61  
   tendons 72  
   touch sensors 182  
 head: growth 277  
   hair 186  
   muscles **68–9**  
   nervous system 78  
   skull **48–9**  
 headaches, migraine 125  
 healing, fractures 57  
 health 11  
 hearing **116–18**, 128, 285  
 heart 163  
   anatomy **150–1**  
   cardiovascular system 146  
   disorders **156–9**  
   electrocardiography 13  
   heart attack 156  
   heartbeat **154–5**  
   hormones 132  
   muscle 67, 153  
   in newborn baby 272, 275  
   valves 150–2  
 height, children's growth 277  
*Helicobacter pylori* 234, 235  
 hepatic portal system 220, 222  
 hepatocytes 25, 220  
 hernia, hiatus 235  
*Herpes simplex* 188  
 hiatus hernia 235  
 hinge joints 44–5  
 hippocampus 94, 111  
 hips 40, 45, 53, 60  
 histamine 199, 201, 208  
 histoplasmosis 207  
 HIV **209**  
 homeostasis **23**, 106  
 hookworms 207  
 hormones 132  
   action of **138–9**  
   disorders **140–3**  
   fertility problems 300  
   glands **134–7**  
   homeostasis 23  
   information processing 20  
   menopause 285  
   menstrual cycle 258, 283

and osteoporosis 58  
   in puberty 280–3  
   sex hormones 134, 137, 252, 256  
 Human Genome Project 34, 287  
 humerus 40, 44, 45  
 hyaline cartilage 36, 43, 46  
 hydrocele 295  
 hydrochloric acid 193, 218, 228  
 hyoid bone 48, 50, 171, 214  
 hypertension 159  
 hyperthyroidism 141  
 hypothalamus 86, 87, 95  
   autonomic nervous system 106, 108  
   feedback system 138  
   hormones 132, 134, 135, 138, 139,  
   282  
   in puberty 281  
 hypothyroidism 141

ileum 213, 219  
 ilium (hip bone) 53  
 imaging the body **12–13**  
 immune system 16, **190–209**  
   allergies **208**  
   autoimmune disorders 61, 141, 142  
   auxiliary immune system 193  
   HIV and AIDS **209**  
   hormones 132  
   infections **202–7**  
   inflammatory response 195, **198–201**  
   local infections 195  
   lymphatic system 192–3  
   specific responses 196  
 immunization 208  
 impetigo 188  
 incisors 216  
 incontinence, urinary 249  
 infections **202–7**  
   bacteria 204–5  
   brain **126**  
   local 195  
   sexually transmitted (STIs) **298–9**  
   superbugs 205  
   urinary tract 248  
 infertility **300–1**  
 inflammatory response 195, **198–201**  
 influenza 173, 202  
 information processing **20**  
 inhalation, breathing 168, 170  
 inheritance **286–93**  
 inherited disorders **304**  
 injuries, inflammatory response 198  
 insulin 133, 136, 142–3  
 interstitial fluid 21, 192, 193  
 intervertebral discs 46, 50  
 intestines: digestion 230–1  
   hormones 133  
   immune system 193  
   large intestine 212, 213, **224–7**  
   in newborn baby 272  
   parasitic worms 207  
   small intestine 212, 213, **219**  
   *see also* colon; rectum  
 intracellular fluid 21  
 involuntary muscles 67  
 involuntary responses 108  
 iris, eye 121  
 iron, haemoglobin 148  
 islets of Langerhans 136, 142

## J

- jaw: bones 48
  - fibrocartilage 46
  - in newborn baby 272
  - teeth 216
- jejunum 213, 219
- joints 19, **44–7**
  - arthritis **60–1**
  - cartilage 59
  - disorders **59–61**
- jaws 42
- ligaments 55
- movement 72
- muscles 64, 66
- in newborn baby 272
- pelvis 53
- spine 50
- wrist 54

## K

- Kaposi's sarcoma 209
- karyotypes, chromosomes 34
- keratin: in hair 181
  - in nails 180
  - in skin 178, 186
- keratinocytes 187
- ketones 142
- kidneys 242, **244–7**
  - homeostasis 23
  - hormones 133, 135
  - stones 249
- killer T-cells 196
- kinins 201
- knee: joint 46–7
  - patella 41
  - patellar spinal reflex 105
  - torn cartilage 59
- Kupffer cells 25

## L

- labia 258
- labour 266, **268–9**
  - birth **270–1**
  - disorders **303**
- lacrimal glands 102, 123
- language *see* speech
- large intestine *see* intestines
- laryngopharynx 162
- larynx 162, 171, 217
- legs: blood vessels 147
  - bones 41
  - growth 276
  - joint disorders 59
  - knee joint 46–7
  - lymphatic system 193
  - muscles 65, 67
  - nervous system 79
- lens, eye 120, 121, 285
- leucocytes *see* white blood cells
- levers, body parts as 72
- ligaments 55
  - injuries 59
  - joints 44, 46, 47
  - spine 50
- light: pineal gland and 138
  - vision 120–1
- light microscopy (LM) 12
- limbic system 86, **94–5**, 108

- lipids 229
- lips, muscles 69
- liver 212, 213, **220–3**
  - disorders **236–7**
  - in newborn baby 272
  - nutrient processing 232
  - tissues 24–5
- liver spots, skin 284
- lobes, brain 90
- loop of Henle 244, 246, 247
- lumbar vertebrae 51
- lungs: blood vessels 153
  - breathing **168–70**
  - cancer 174
  - chronic obstructive pulmonary disease 175
  - coughing 171
  - cystic fibrosis 304
  - disorders **173–5**
  - gas exchange 164, **166–7**
  - inflammatory response 198–201
  - in newborn baby 272
  - pulmonary embolism 158
  - respiratory system 162
  - structure **164–5**
- luteinizing hormone (LH) 134, 258, 281, 282–3
- lymphatic system 16
  - anatomy **192–3**
  - lymph fluid 21, 192–3, 194
  - lymph nodes 192–3, 194
  - lymph vessels 194
- lymphocytes 194, 196
- lymphokines 196
- lysosome 26, 200

## M

- macrophages 194, 196–7, 199
- macula, balance 119
- macular degeneration, eyes 285
- magnetic resonance imaging (MRI) 13, 111
- malaria 206
- male reproductive organs **252–3**
  - disorders **294–5**
  - infertility **301**
- malignant tumours 305
- mammary glands 135, 259
  - see also* breasts
- mammogram 12
- manual dexterity, development of 278–9
- marrow, bone, 42, 43
- mast cells 208
- Meissner's corpuscles 115, 182, 183
- melanin: moles 189
  - skin pigmentation 134, 187, 188
- melanocytes 134, 187, 188, 189
- melanoma 12
- melanosomes 187
- melatonin 132, 138
- membranes: cells 26, 27, 28
  - epithelial tissues 184
  - lining of mouth 214
  - peritoneum 213
- memory **110–11**, 125
- memory cells, immune system 196, 197, 208
- meninges 87, 88, 98
- meningitis 126
- meniscus, knee joint 47, 59
- menopause 58, 285, 297
- menstrual cycle 282, 283
  - endometriosis 296
  - ovulation 256, 258
- menstruation 282, 283, 285
- Merkel's discs 115, 183
- metabolism 132, 141, **233**
- metacarpal bones 41, 44, 54
- metatarsal bones 41, 44, 55
- meticillin 205
- microfilaments, cells 26
- microorganisms: immune system 194–5, **202–7**
  - see also* bacteria; viruses
- microreceptors 20
- microscopy 12
- microtubules, cells 26
- microvilli, cells 26, 28
- migraine 125
- milk, breast-feeding 135, 259, 273
- milk teeth 272, 278
- minerals 220, 232
- miscarriage 303, 304
- mitochondria 26, 29, 35
- mitral valve, heart 151, 152
- molars 216, 278
- molecules, crossing cell membrane 29
- moles 189
- monocytes 194, 199
- morula 260
- mosquitoes, malaria 206
- motor nerves 82
  - autonomic nervous system 106
  - positional sense 73
  - spinal reflexes 105
- motor skills 19, 278–9
- mouth **214–17**
  - anatomy 214
  - digestive system 212
  - muscles 69
  - sense of taste 113
  - teeth 216
- movement **19, 70**, 72–3
- mucus, coughing and sneezing 171
- multiple-gene inheritance 293
- multiple pregnancy 266
- multiple sclerosis (MS) 127
- multipolar neurons 82
- muscles 14, 19, **64–74**
  - autonomic nervous system 106, 108–9
  - breathing 168, 170
  - cells 27, 35, 36
  - contraction 70, 71
  - development of 278–9
  - digestive system 212, 226, 227
  - disorders **74**
  - eye 121, 123
  - face, head, and neck **68–9**
  - hands 54
  - heart 150, 153
  - joints 46
  - movement 70, 72–3
  - proprioceptive sense 73, 102
  - puberty 280
  - stomach 218
  - structure 70–1
  - tendons 72
  - tissues 37, 67
  - tongue 214
  - mutations 288

myelin, nerves 81, 85, 127  
myofibres 70–1  
myofilaments 70–1

## N

nails 16, 180, 186  
nasal bones 49  
nasopharynx 162, 171, 214  
neck muscles **68–9**  
nematodes 207  
nephrons, kidneys 244, 246–7  
nerve cells *see* neurons  
nerves **82**  
    carpal tunnel syndrome 75  
    dermatomes 105  
    hormones and 132  
    multiple sclerosis (MS) 127  
    regeneration 83  
    touch sensors 179  
nervous system 15, **76–128**  
    ageing 285  
    autonomic nervous system **106–9**  
    brain **86–97**  
    ears, hearing, and balance **116–19**  
    eyes and vision **120–3**  
    homeostasis 23  
    information processing **20**  
    nerves and neurons **80–1**  
    peripheral nerves **102–5**  
    positional sense 73  
    senses **112–23**  
    sensory feedback 19  
    spinal cord **98–9**  
    tissues 36  
    touch sensors 115, 182–3  
neuromuscular spindles 73  
neurons 27, 35, **80–1**  
    ageing 285  
    brain 92  
    nerve impulses **84–5**  
neurotransmitters 84  
neutrophils 180, 194, 199, 200, 201  
newborn baby **272, 274–5**  
nipples 259  
non-gonococcal urethritis (NGU) 299  
nose: auxiliary immune system 193  
    respiratory system 162  
    sense of smell 112, 113  
    sneezing 171  
nostrils 69, 162  
nuclear medicine imaging 13  
nuclear membrane, cells 26  
nucleolus, cells 26  
nucleoplasm, cells 26  
nucleus 26, 30  
    cell division 289  
    neurons 80  
nutrients **232–3**

## O

oesophagus 212, 213  
hiatus hernia 235  
oesophageal varices 237  
swallowing 217  
oestrogen 133, 137, 256, 258  
    fertility problems 300  
    menopause 285  
    menstrual cycle 282, 283  
    puberty 282

olfactory epithelium 102, 112, 162  
oligodendrocytes 83  
omentum 213  
organelles 26, 27, 28, 29  
organs 24  
    *see also individual organs*  
oropharynx 162, 214  
ossicles, ear 49, 117, 118  
ossification, bones 42, 276  
osteoarthritis 60  
osteoblasts 42, 57  
osteoclasts 42  
osteocytes 42  
osteons 43  
osteoporosis 56, 58  
ova *see* egg cells  
ovaries 256, 257, 258  
    hormones 133, 136, 137  
    menstrual cycle 282, 283  
    pelvic inflammatory disease 298  
    puberty 282  
ovulation 256, 258, 282, 300  
ovum *see* egg cells  
oxygen: and ageing 284  
    in blood 148  
    in brain 86  
    breathing 168, 170  
    cardiovascular system 146  
    cellular respiration 166  
    fetal development 265  
    gas exchange 164, **166–7**  
    newborn baby 275  
    pulmonary circulation 153  
oxytocin 135

## P

pacemaker, heart 155, 159  
Pacinian corpuscles 115, 182, 183  
pain 19  
    inflammatory response 198, 201  
palate 214, 217  
pancreas 133, 212, 213, **223**  
    diabetes mellitus 142–3  
    hormones 136  
    pancreatitis 142, 238  
papillae, tongue 114  
parasites 206, 207  
parasympathetic autonomic nervous system 106, 107  
parathyroid glands 137  
parotid glands 212, 215  
patella 41, 47  
patellar spinal reflex 105  
pelvic inflammatory disease (PID) 298, 300  
pelvis 40, **53**  
    childbirth 268, 271  
    in newborn baby 272  
penis 252, 253  
    erection 255  
    sexual intercourse 260  
    urinary system 243  
pepsin 228, 230  
peptic ulcers 234  
peptidase enzymes 231  
peptides 233  
pericardial cavity 163  
periods 282, 283, 285  
periosteum 42, 276  
peripheral nervous system (PNS) 78,  
    **102–5**  
    peristalsis 212, 218  
    peritoneum 213  
    peroxisome, cells 26  
    Peyer's patches 192, 193  
    phagocytes 172  
    phagocytosis 197, 200  
    phalanges 41, 54, 55  
    pharynx 214  
        anatomy 162  
        coughing 171  
        swallowing food 212, 217  
    phospholipids 28  
    photoreceptor cells 27  
    physiology 11  
    pia mater 88, 98, 100  
    pigmentation: ageing 284  
        hormones and 134  
        melanin 187, 188  
    pineal gland 132, 138  
    pituitary gland 87, 132, 134–5  
        hormones 138, 139  
        menstrual cycle 283  
        puberty 281, 282  
        tumours 140  
    pivot joints 44–5  
    placenta 260  
        delivery 270, 271  
        development of 263  
        functions 265  
        problems 302  
    plasma 21, 148, 197, 201  
    plasmids, bacteria 205  
    platelets 37, 148–9, 180  
    pleural cavity 163  
    pleural membranes 163, 165  
    plexus, spinal nerves 104  
    portal hypertension 237  
    positron emission tomography (PET)  
        scans 13  
    posture 19  
    potassium 232  
    pregnancy: conception to embryo  
        **260–3**  
        delivery **270–1**  
        disorders **302–3**  
        fetal development **264–5**  
        labour **268–9**  
        preparing for birth **266–7**  
        ultrasound scans 13  
    premolars 216  
    preterm labour 303  
    primitive brain **94–5**  
    progesterone 133, 137, 282, 283  
    prolactin 135  
    prolactinomas 140  
    prolapsed uterus 297  
    proprioceptive sense 19, 73, 102  
    prostate gland 243, 253  
        disorders 294  
        semen 254, 255  
    proteins: complement system 196–7  
        digestion 229  
        in food 232  
        protein-based hormones 139  
        synthesis 32, 220, 233  
    protists (protozoa) 206  
    psoriasis 188  
    puberty 256, 258, **280–3**  
    pubic hair 280, 282

public health, immunization 208  
 pulmonary artery 151, 163, 165  
 pulmonary circulation 153  
 pulmonary embolism 158  
 pulmonary valve, heart 151, 152  
 pulmonary vein 151, 153, 163, 165  
 pupil, eye 103, 121, 123  
 pus 195  
 pyelonephritis 248

## R

radius 40, 44, 45  
 rashes 126, 188  
 recessive genes 292–3  
 rectum 213, 226  
   colorectal cancer 239  
   defecation 227  
 red blood cells 27, 37, 148–9  
 reflexes 108  
   ageing 285  
   in babies 278  
   respiratory 171  
   spinal 105  
   swallowing 217  
 reflux, urine 248  
 renal artery 245  
 renal vein 245  
 replication, DNA 288  
 reproductive system 17, **250–75**  
   baby **272–5**  
   conception to embryo **260–3**  
   female **256–9**  
   female disorders **296–7**  
   fetal development **264–5**  
   infertility disorders **300–1**  
   male **252–5**  
   male disorders **294–5**  
   menopause 285  
   pregnancy and labour disorders **302–3**  
   sexually transmitted infections **298–9**  
 respiratory system 16, **160–75**  
   anatomy **162–3**  
   breathing **168–70**  
   disorders **172–5**  
   gas exchange **166–7**  
   homeostasis 23  
   immune system 193  
   inflammatory response 198–201  
   lungs **164–5**  
   pulmonary circulation 153  
   reflexes 171  
   vocalization **170**  
 reticular activating system (RAS) 96  
 reticular formation 96  
 retina: epithelium 185  
   macular degeneration 285  
   optic nerve 103  
   vision 120, 122  
 rheumatoid arthritis 61  
 ribosomes, cells 26, 32  
 ribs 40, **52**  
   breathing 163, 168–70  
 ringworm 207  
 RNA 35, 209  
   viruses 202, 203, 209  
 rod cells, retina 120  
 roundworms 207  
 Ruffini corpuscles 115, 183

## S

sacrum 40, 50, 51, 53  
 saddle joints 45  
 saliva 21, 114  
 salivary glands 193, 212, 214, 215  
 scabs, skin repair 180  
 scalp, hair 186  
 scanning electron microscopy (SEM) 12  
 scans, imaging the body **12–13**  
 scapula 40, 41, 45, 68  
 scars 180  
 Schwann cells 80, 81, 85  
 scrotum 252, 253, 295  
 sebaceous glands 179, 186, 189  
 sebum 179, 186, 189  
 secretory vesicles, cells 26  
 semen (seminal fluid) 255  
 semicircular canals, ear 117, 119  
 semilunar valves, heart 152  
 semimovable joints 44  
 seminal vesicles 253, 254  
 seminiferous tubules 252, 254  
 senses **112–23**  
   hearing **116–18**  
   and memory 110  
   proprioceptive sense 19, 102  
   smell **112–13**  
   taste **113, 114**  
   touch **115, 182–3**  
   vision **120–3**  
 sensors, skin 182–3  
 sensory nerves 82  
   autonomic nervous system 106  
   positional sense 73  
   spinal reflexes 105  
   touch 115  
 sex cells: cell division 289  
   chromosome disorders 304  
   egg 258  
   sperm 252  
 sex chromosomes 291, 293  
 sex glands 137  
 sex hormones 134  
   and osteoporosis 58  
   ovaries 133, 136, 137, 256  
   testes 136, 137, 252  
 sex-linked inheritance 293  
 sexual intercourse 260  
 sexually transmitted infections (STIs) **298–9**  
 shoulder 41, 45  
 sigmoid colon 213, 227, 239  
 sinoatrial node, heart 155  
 sinus tachycardia 159  
 sinuses 48  
 skeletal muscle 37, 67, 70  
 skeleton see bones  
 skin 16, **178–89**  
   ageing 284  
   cancer 12, 187  
   connective tissue 36, 37  
   defensive functions **186–7**  
   dermatomes 105  
   disorders **188–9**  
   immune system 193  
   pigmentation 134, 187, 188, 284  
   puberty 280  
   renewal 178  
   repair 180  
   sweat 22  
   temperature regulation 181  
   touch sensors **182–3**  
   see also rashes  
 skull: bones 40, 41, **48–9**  
   fontanelles 272, 277  
   growth 277  
   joints 44, 48, 277  
   sleep cycles 97, 138  
   “slipped disc” 57  
 small intestine see intestines  
 smell, sense of 102, **112–13**, 162  
 smooth muscle 27, 37, 67  
 sneezing 171, 172  
 social skills, development of 278–9  
 sodium 232  
 sounds: hearing 116, 118, 285  
   vocalization 171  
 speech and language 110  
   development of 278–9  
   vocal cords 162  
   vocalization **171**  
 sperm 252, 254–5  
   cells 27, 35  
   fertility problems 300, 301  
   fertilization of egg 260, 289  
   and inheritance of gender 291  
   meiosis 289  
   movement 28  
   puberty 280, 281  
   sexual intercourse 260  
 sphincters 227, 249  
 spina bifida 127  
 spinal cord 51, 78, **98–9**  
   nerve damage 83  
   spina bifida 127  
   spinal nerves 104  
   spinal reflexes 105  
 spine 18  
   disc prolapse 57  
   intervertebral discs 46, 50  
   spinal canal 100  
   vertebrae **50–1**  
 spirilla 204  
 spleen 192, 193  
 sprains 59  
 squamous cells 185  
 stem cells 27  
 sternum 40, 52, 169, 170  
 steroid hormones 133, 134, 136, 139  
 stomach 213  
   anatomy **218**  
   disorders 234–5  
   hormones 133  
   immune system 193  
 stones 238, 249  
 strain, muscles 74  
 striated muscle 67, 70  
 stroke 124, 157  
 subconscious behaviour 94  
 subcutaneous fat 179  
 superbugs 205  
 suture joints, skull 44, 48, 277  
 swallowing 103, 217  
 sweat 22, 179, 181  
 sweat glands 178, 179  
 sympathetic autonomic nervous system 106  
 synapses 80, 84  
 synovial fluid 44, 46  
 synovial joints 44, 46



synovial membrane 44, 46, 47, 61  
 syphilis 299  
 systems **14–17**, 24–5  
   homeostasis 23  
*see also individual systems*

## T

T-lymphocytes 192, 196  
 tanning, skin pigmentation 187  
 tapeworms 207  
 tarsal bones 41, 44, 55  
 taste 103, **113**, **114**  
 tear glands 193  
 tears 123  
 teeth 212, 216  
   abscesses 195  
   chewing food 214, 216  
   development 278  
   milk teeth 272, 278  
   in newborn baby 272  
 temperature regulation 23, 181  
 tendinitis 74  
 tendons **72**, **74–5**  
 tenosynovitis 74  
 testes (testicles) 133, 252, 253  
   cancer 295  
   hormones 136, 137, 281  
   hydrocele 295  
   puberty 280, 281  
 testosterone 133, 137, 252, 280, 281  
 thalamus 86, 87, 90, 93, 113  
 thermoregulation 23  
 thinking **111**  
 thoracic vertebrae 51  
 thoughts **111**  
 throat 172, 214–15, 217  
 thrombocytes 148  
 thrombosis 124, 156, 158  
 thrush 207, 209  
 thumb 45, 54  
 thymine 30, 31, 287  
 thymus gland 132, 192, 272  
 thyroid cartilage 171  
 thyroid gland 132, 137  
   disorders 141  
   hormones 134, 139  
 thyroid-stimulating hormone (TSH) 134, 135  
 thyrotropin-releasing hormone 134, 139  
 thyroxine 141  
 tibia 41, 47  
 tinea infections 207  
 tissues, types of **36–7**  
 toes 55, 180, 186  
 tongue 214  
   hyoid bone 50  
   sense of taste 114  
   sneezing 171  
 tonsils 192  
 tooth see teeth  
 toothache 195  
 touch, sense of **115**, 179, **182–3**  
 toxins 205, 222  
 trachea 165  
   anatomy 162, 163  
   breathing 164, 169  
   bronchoscopy 13  
   coughing 171, 217  
   epithelial cells 184  
   inflammatory response 198–201

transcellular fluid 21  
 transcription, DNA 32  
 translation, DNA 32  
 tricuspid valve, heart 151, 152  
 triplets 266  
 trypanosomes 206  
 tumours 12, 140, 305  
   *see also cancer*  
 twins 266

## U

ulcers, peptic 234  
 ulna 40, 44  
 ultrasound scans 13  
 ultraviolet (UV) light 187  
 umbilical cord 264, 270, 271, 275  
 unipolar neurons 82  
 upper airway infections 172–3  
 ureter 242, 243, 253  
 urethra 242, 243, 255, 257  
 urethritis, non-gonococcal 299  
 urinary system 17, **240–9**  
   anatomy **242–3**  
   disorders **248–9**  
   epithelium 184  
   homeostasis 23  
   kidneys **244–7**  
   urinary tract infections 248  
 urine 242, 247  
 uterus 256, 257  
   after birth 273  
   birth 270–1  
   blood circulation 274  
   contractions 267–70  
   endometriosis 296, 300  
   fetal development 264–5  
   fetal position 266  
   fibroids 297  
   hormones 135  
   implantation of blastocyst 261  
   menstrual cycle 283  
   pregnancy disorders 302–3  
   problems in labour 303  
   prolapse 297  
 vulva 214

## V

vaccines 208  
 vacuoles, cells 26  
 vagina 257, 264  
   birth 270–1  
   menopause 285  
   prolapsed uterus 297  
   sexual intercourse 260  
   vulva 258  
 valves: heart 150–2, 157  
   veins 149  
 vas deferens 252, 253, 255, 301  
 vasodilation 201  
 vasopressin 135  
 veins 146, 149  
   coronary veins 150  
   in newborn baby 275  
   oesophageal varices 237  
   respiratory system 163  
   thrombosis 158  
 vena cava 151, 153, 221  
 ventricles: brain 89, 91  
   heart 150, 151, 152, 154

ventricular tachycardia 159  
 vertebrae 18, 41, **50–1**  
   disc prolapse 57  
   intervertebral discs 46  
   joints 44  
   spinal cord 99, 100  
 vertebral column 40  
 vibrations, hearing 118  
 villi: chorionic 263, 265  
   digestion 219, 230, 231  
 viruses **202–3**  
   HIV **209**  
   respiratory infections 172–3  
 vision **120–3**  
   ageing 285  
   colour blindness 293  
   development of 278–9  
   disorders **129**  
   optic nerve 103  
 visual cortex 110, 122  
 vitamins: digestive system 232  
   storage in liver 220  
   vitamin B group 224, 232  
   vitamin K 224, 232  
 vitiligo 188  
 vitreous humour, eye 120  
 vocal cords 162, 217  
   puberty 280  
   vocalization **171**  
 voluntary muscles 67  
 voluntary responses 109  
 vulva 258

## W

walking 55  
 waste products 21  
   ageing 284, 285  
   in blood 148  
   digestive system 213  
   urinary system 242, 247  
 water: body fluids 21  
   in colon 232  
   drinking 23  
 wax, in ears 116, 128  
 white blood cells 148–9  
   functions 172, 195  
   inflammatory response **198–201**  
   lymphatic system 192  
   skin repair 180  
   types 194  
 white matter 36, 92–3, 98  
 windpipe *see* trachea  
 wisdom teeth 216, 278  
 womb *see* uterus  
 worms, parasitic 207  
 wounds 83, 180, 198  
 wrinkles, skin 284  
 wrist: bones 40, **54**  
   carpal tunnel syndrome 75  
   fibrocartilage 46  
   joints 44, 45

## XYZ

X-rays 12–13  
 yeasts 207  
 zygote 260

# ACKNOWLEDGMENTS

Dorling Kindersley would like to thank several people for their help in the preparation of this book. Anna Barlow contributed valuable comments on the cardiovascular system. Peter Laws assisted with visualization, and additional design work was done by Mark Lloyd and Louise Waller. Three-dimensional illustrations were created from a model supplied by Zygote Media Group, Inc. Ben Hoare, Peter Frances, and Ed Wilson all provided editorial assistance. Marianne Markham and Andrea Bagg contributed to the initial development work.

## The Concise Human Body Book Picture Credits

The publisher would like to thank the following for their kind permission to reproduce their photographs:

(Key: a-above; b-below/bottom; c-centre; f-far; l-left; r-right; t-top)

**5 Science Photo Library:** Sovereign, ISM. **6 Science Photo Library.** **10-11 Science Photo Library:** Francois Paquet-Durand. **12 Alamy Images:** Dr. P. Marazzi (br). **Science Photo Library:** CNRI (bl). **Wellcome Library, London:** K. Hodivala-Dilke & M. Stone (cra). **13 Alamy Images:** Chad Ehlers (bl). **Getty Images:** Science Faction / L. Steinmark - CMSP (br). **Science Photo Library:** CNRI (bc); Wellcome Dept. of Cognitive Neurology (cr); K H Fung (tr); Alfred Pasiaka (tc). **18 Science Photo Library.** **20 Still Pictures:** PHONE Labat J.M. / F. Rouquette (bl); Volker Steger (tr). **21 Science Photo Library:** CNRI (tl). **22 Science Photo Library:** Richard Wehr / Custom Medical Stock Photo; Adam Hart-Smith (crb). **23 Science Photo Library:** Adam Hart-Davis (cr). **25 Dreamstime.com:** Kateryna Kon (tl). **27 Science Photo Library:** Volker Steger (cla). **28 Alamy Images:** Phototake Inc. (tc). **Science Photo Library:** Jean-Claude Revy, ISM (cb). **29 Science Photo Library:** Professors P. Motta & T. Naguro (tl) (tc) (tr). **30 Science Photo Library:** Lawrence Livermore Laboratory (clb). **33 Alamy Images:** Bjanka Kadic (tr). **34 Science Photo Library:** CNRI (tl). **35 Science Photo Library:** Alain Pol, ISM (tl). **36 Alamy Images:** Phototake Inc. (tr). **Science Photo Library:** Nancy Kedersha / UCLA (tc). **Still Pictures:** Ed Reschke (br). **37 Corbis:** Visuals Unlimited (br). **Science Photo Library:** Innerspace Imaging (tl); Claude Nuridsany & Marie Perennou (bc). **Still Pictures:** Ed Reschke (bl) (tc). **Wellcome Library, London:** David Gregory & Debbie Marshall (tr). **38-61 Wellcome Library, London:** Professor Alan Boyde (sidebars). **43 Science Photo Library:** Biophoto Associates (bl). **Wellcome Library, London:** M.I. Walker (cra). **44 DK Images:** Philip Dowell / Courtesy of The Natural History Museum, London (clb). **Wellcome Library, London:** (bl). **46 Science Photo Library:** G.J.L.P. (bl). **47 Science Photo Library:** Eye of Science (tc). **48 Science Photo Library:** Simon Brown (tl). **50 Science Photo Library:** Anatomical Travelogue (tr). **59 Science Photo Library:** CNRI (cla). **60 Science Photo Library:** Princess Margaret Rose Orthopaedic Hospital (cl). **61 Science**

**Photo Library:** CNRI (cl). **62-75 Science Photo Library:** Eye of Science (sidebars). **67 Science Photo Library:** (crb)/Smooth (br)/Cardiac. **Wellcome Library, London:** M.I. Walker (bc/Striated). **68 Still Pictures:** Ed Reschke (tl). **70 Science Photo Library:** Steve Gschmeissner (cla). **76-129 Science Photo Library:** Nancy Kedersha (sidebars). **80 Wellcome Library, London:** Dr Jonathan Clarke (clb). **81 Science Photo Library:** Steve Gschmeissner (br). **83 Science Photo Library:** Nancy Kedersha (br); Dr. John Zajcek (bc). **86 Alamy Images:** allOver Photography (bl). **Science Photo Library:** Zephyr (br). **Still Pictures:** Alfred Pasiaka (tr). **91 Science Photo Library:** Zephyr (clb). **92 Science Photo Library:** Bo Veisland, MI&I (br). **99 Alamy Images:** Phototake Inc. (t). **104 Science Photo Library:** CNRI (tr). **111 Corbis:** Visuals Unlimited (b). **112 Science Photo Library:** Eye of Science (tr). **113 Science Photo Library:** Pascal Goetgheluck (t). **114 Alamy Images:** Phototake Inc. (br). **118 Science Photo Library:** Susumu Nishinaga (tr). **121 Louise Thomas:** (fcr) (fcr). **123 Wellcome Library, London:** (cla) (cra). **125 Science Photo Library:** Alfred Pasiaka (c). **126 Alamy Images:** Medical-on-Line (br); Phototake Inc. (bc). **128 Science Photo Library:** Bo Veisland (clb). **130-143 Wellcome Library, London:** University of Edinburgh (sidebars). **137 Science Photo Library:** Manfred Kage (bl); **Dreamstime.com:** Steve Gschmeissner (br). **141 Wellcome Library, London:** (br). **144-159 Wellcome Library, London:** EM Unit / Royal Free Med. School (sidebars). **151 Science Photo Library:** Manfred Kage (tr). **152 Science Photo Library:** (cr); Professors P.M. Motta & G. Macchiarelli (bl). **153 Wellcome Library, London:** M.I. Walker (tr). **156 Science Photo Library:** CNRI (crb). **157 Science Photo Library:** BSIP VEM (cra). **160-175 Science Photo Library:** G.J.L.P. (sidebars). **167 Alamy Images:** Phototake Inc. (tc). **169 Science Photo Library:** Zephyr (t). **171 Science Photo Library:** CNRI (cl) (c). **Alamy Stock Photo:** Custom Medical Stock Photo (cr). **172 Science Photo Library:** Dr Gary Settles (cra). **176-189 Science Photo Library:** Steve Gschmeissner (sidebars). **178 Science Photo Library:** Sheila Terry (tl). **182 Alamy Images:** Phototake Inc. (bl). **Science Photo Library:** J.C. Revy (cl). **184 Science Photo Library:** Steve Gschmeissner (bl); Prof. P. Motta / Dept. of Anatomy / University, "La Sapienza", Rome (cr). **185 Science Photo Library:** Prof. P. Motta / Dept. of Anatomy / University "La Sapienza", Rome (tr). **186 DK Images:** Steve Gorton (tr); Jules Selmes and Debi Treloar (cl). **Science Photo Library:** Alfred

Pasiaka (bc). **187 DK Images:** Susanna Price (cr); Jules Selmes and Debi Treloar (cl) (c). **188 Alamy Images:** Medical-on-Line (bl). **Mediscan:** (cl). **Wellcome Library, London:** (cr) (br). **190-209 Science Photo Library:** Francis Leroy, Biocosmos (sidebars). **196 Science Photo Library:** CNRI (bl). **199 Alamy Images:** Phototake Inc. (tr) (tl). **205 Alamy Images:** Scott Camazine (br). **206 Science Photo Library:** Eye of Science (tr). **207 Science Photo Library:** David Scharf (cl) (bl). **210-239 Science Photo Library:** Eye of Science (sidebars). **215 Science Photo Library:** Steve Gschmeissner (crb). **216 Science Photo Library:** Eye of Science (tr). **217 Science Photo Library:** CNRI (tr). **218 Dreamstime.com:** Gunita (c). **221 Science Photo Library:** Prof. P. Motta / Dept. of Anatomy / University "La Sapienza", Rome (bl). **224 Science Photo Library:** Professors P. Motta & F. Carpino / University "La Sapienza", Rome (br). **230 Science Photo Library:** Dr T. Blundell, Dept. of Crystallography, Birkbeck College (b). **232 Corbis:** Frank Lane Picture Agency (tr). **235 Science Photo Library:** P. Hawtin, University of Southampton (tr). **244 Wellcome Library, London:** David Gregory & Debbie Marshall (br). **248 Science Photo Library:** Professor P.M. Motta et Al (br). **249 Science Photo Library:** Steve Gschmeissner (bl). **250-305 Science Photo Library:** Susumu Nishinaga (sidebars). **254 Science Photo Library:** Steve Gschmeissner (clb). **255 Science Photo Library:** Parviz M. Pour (b). **256 Wellcome Library, London:** Yorgos Nikas (bl). **257 Alamy Images:** Phototake Inc. (tl). **258 Science Photo Library:** Professors P.M. Motta & J. Van Blerkom (tr). **270 Science Photo Library:** Keith / Custom Medical Stock Photo (cra). **276 Science Photo Library:** (l). **278 Science Photo Library:** BSIP VEM (bl). **279 Corbis:** Jose Luis Pelaez, Inc. (tr). **281 Science Photo Library:** Susumu Nishinaga (t). **282 Science Photo Library:** Professor P.M. Motta, G. Macchiarelli, S.A, Nottola (cla). **284 Alamy Images:** Chad Ehlers (br). **285 Science Photo Library:** Gunilla Elam (bc) (br). **287 Corbis:** Andrew Brookes (tr). **Science Photo Library:** Philippe Plailly (br). **294 Science Photo Library:** CNRI (br). **298 Mediscan:** CDC (t). **299 Science Photo Library:** (br). **301 Science Photo Library:** James King-Holmes (fc) (cl). **303 Alamy Images:** Janine Wiedel Photolibrary (tr). **304 Wellcome Library, London:** Wessex Reg. Genetics Centre (clb) (bl)

All other images © Dorling Kindersley  
For further information see:  
[www.dkimages.com](http://www.dkimages.com)